Nouveautés en imagerie de la base du crâne

F Dubrulle
NX Bonne – C Vincent

CHU Lille - France

Nouveautés en imagerie de la base du crâne

Apport des logiciels de fusion d'images et de guidage per-opératoire (Brainlab) à la chirurgie de la base du crâne

Imagerie de l'hydrops labyrinthique:
la révolution du FLAIR HR 4h après Gado

Imagerie 3D et Reconstruction 3D
Aide à la planification chirugicale

Pas une nouveauté en base du crâne
Plus de 15 ans

collaboration chirurgiens-radiologues

Planification pré-opératoire

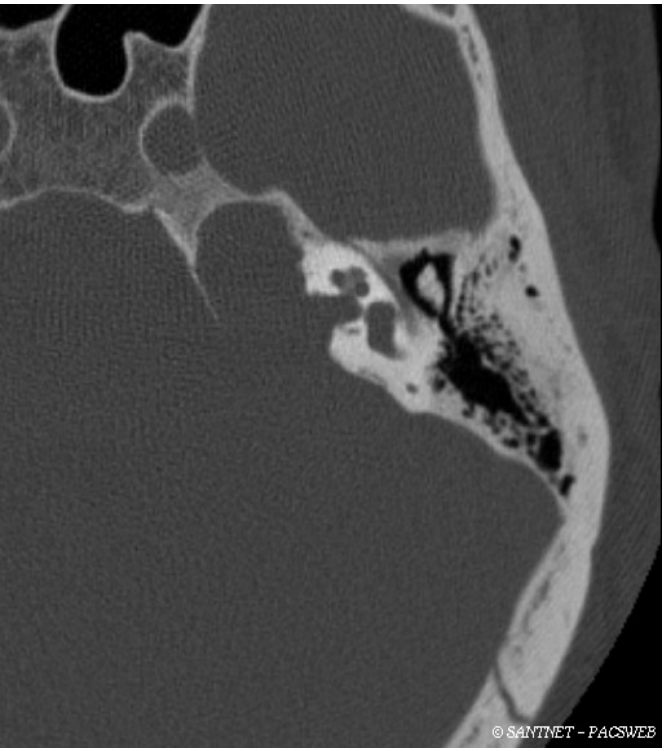
© SANTINET - PACSWEB

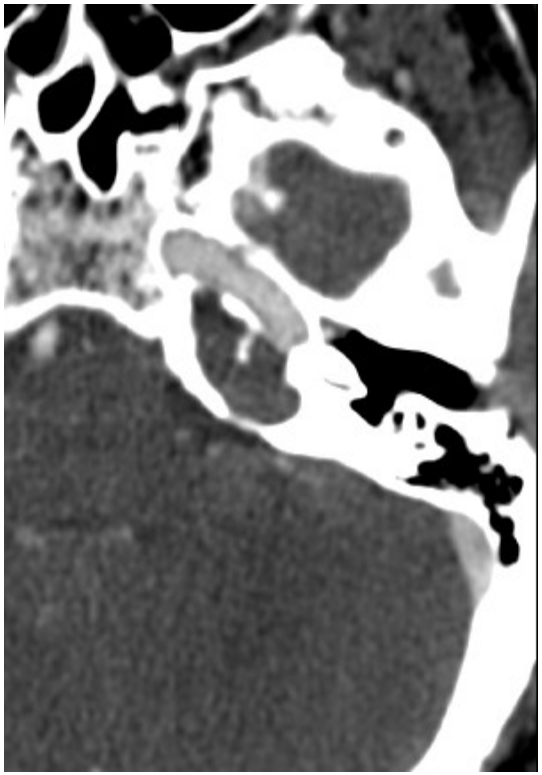

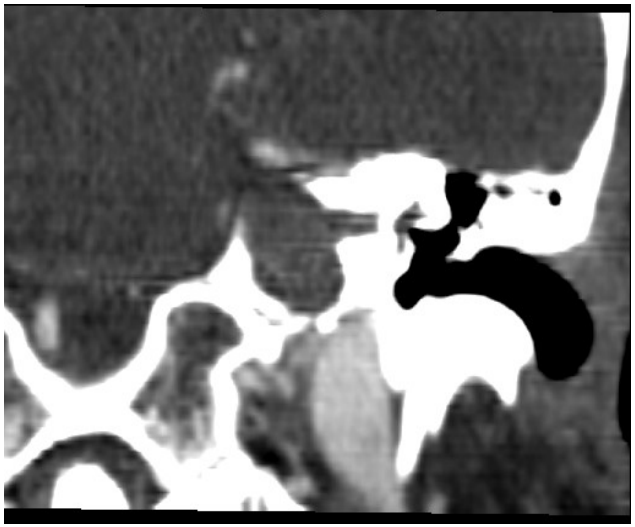

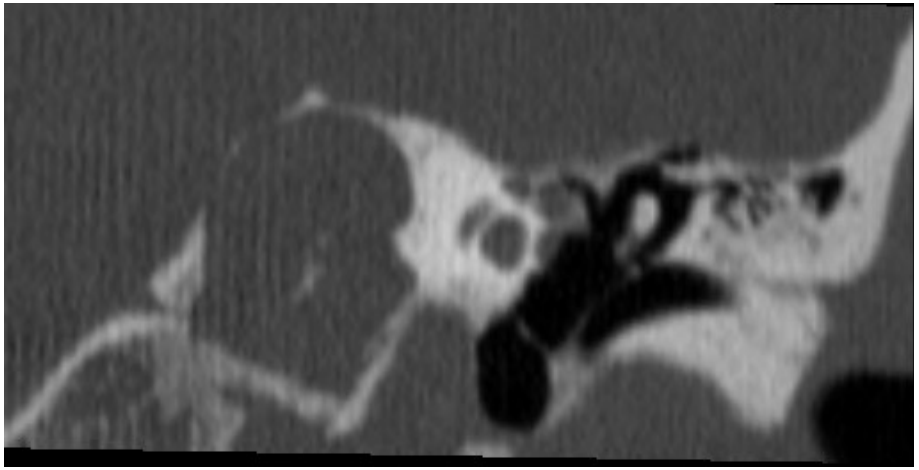

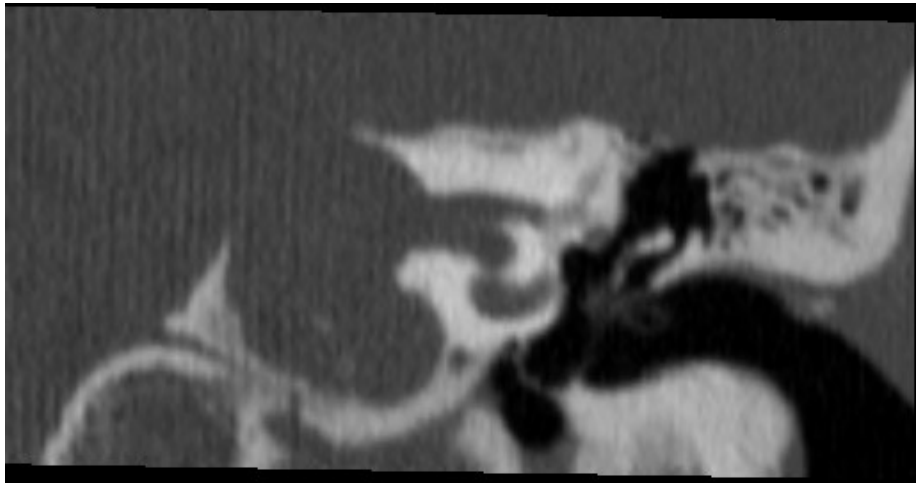

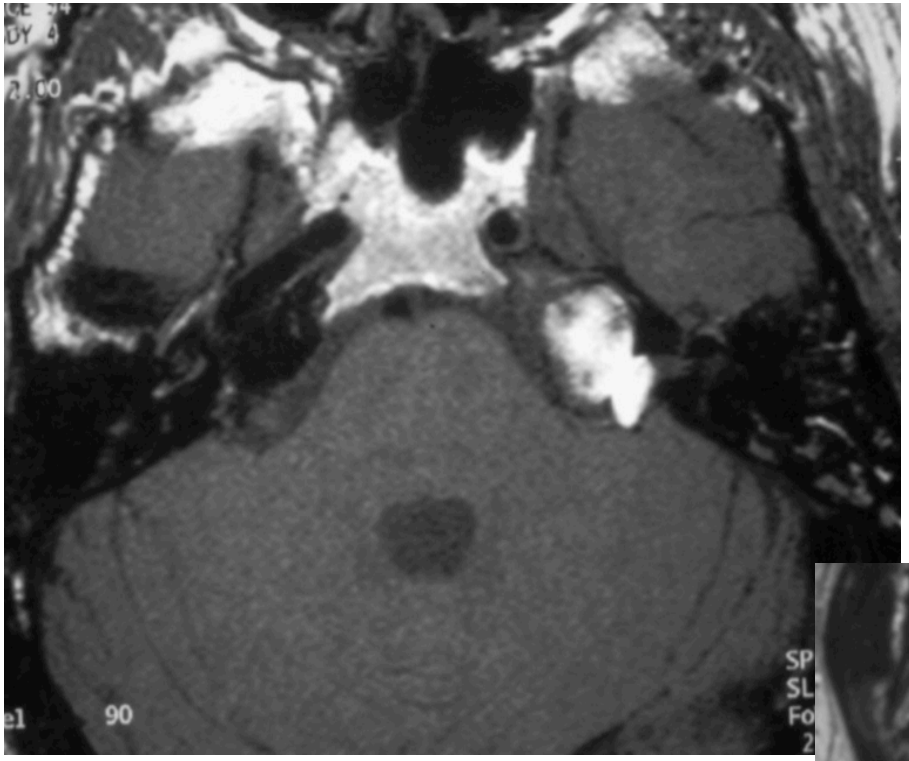
90

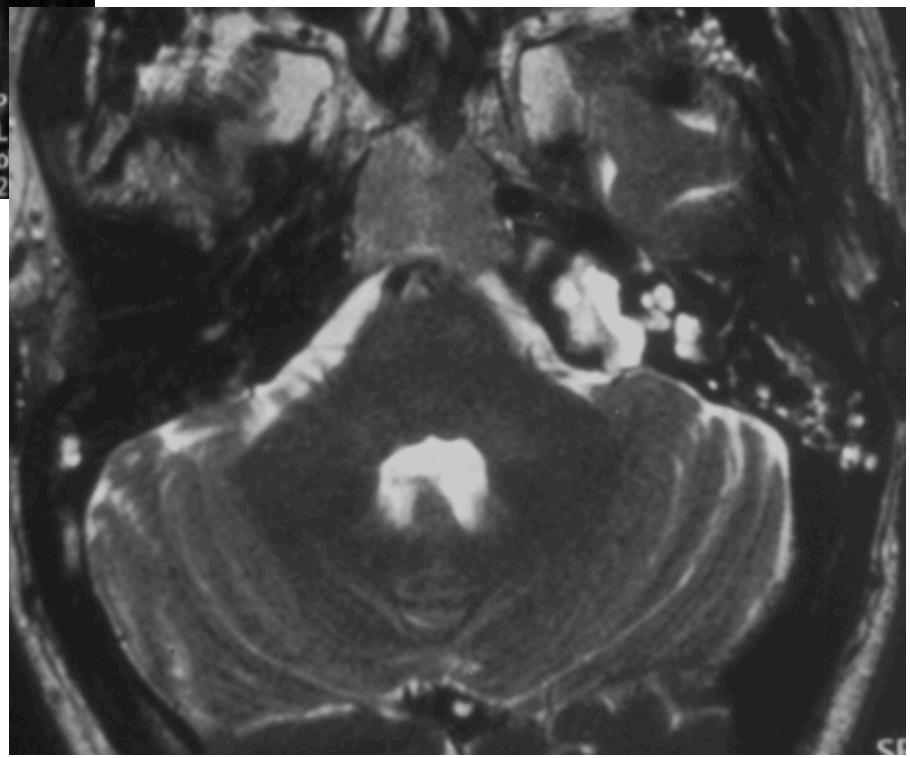

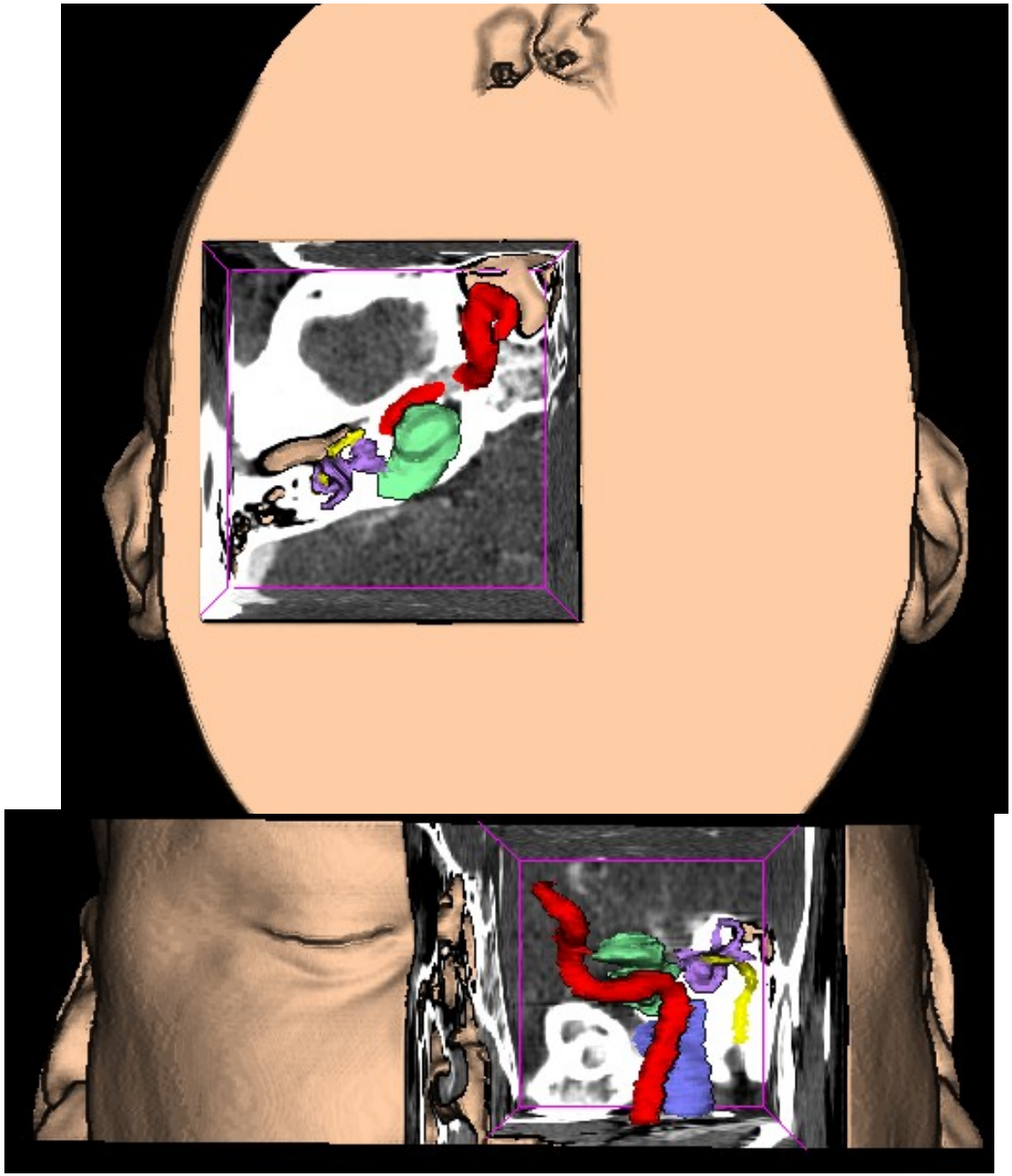

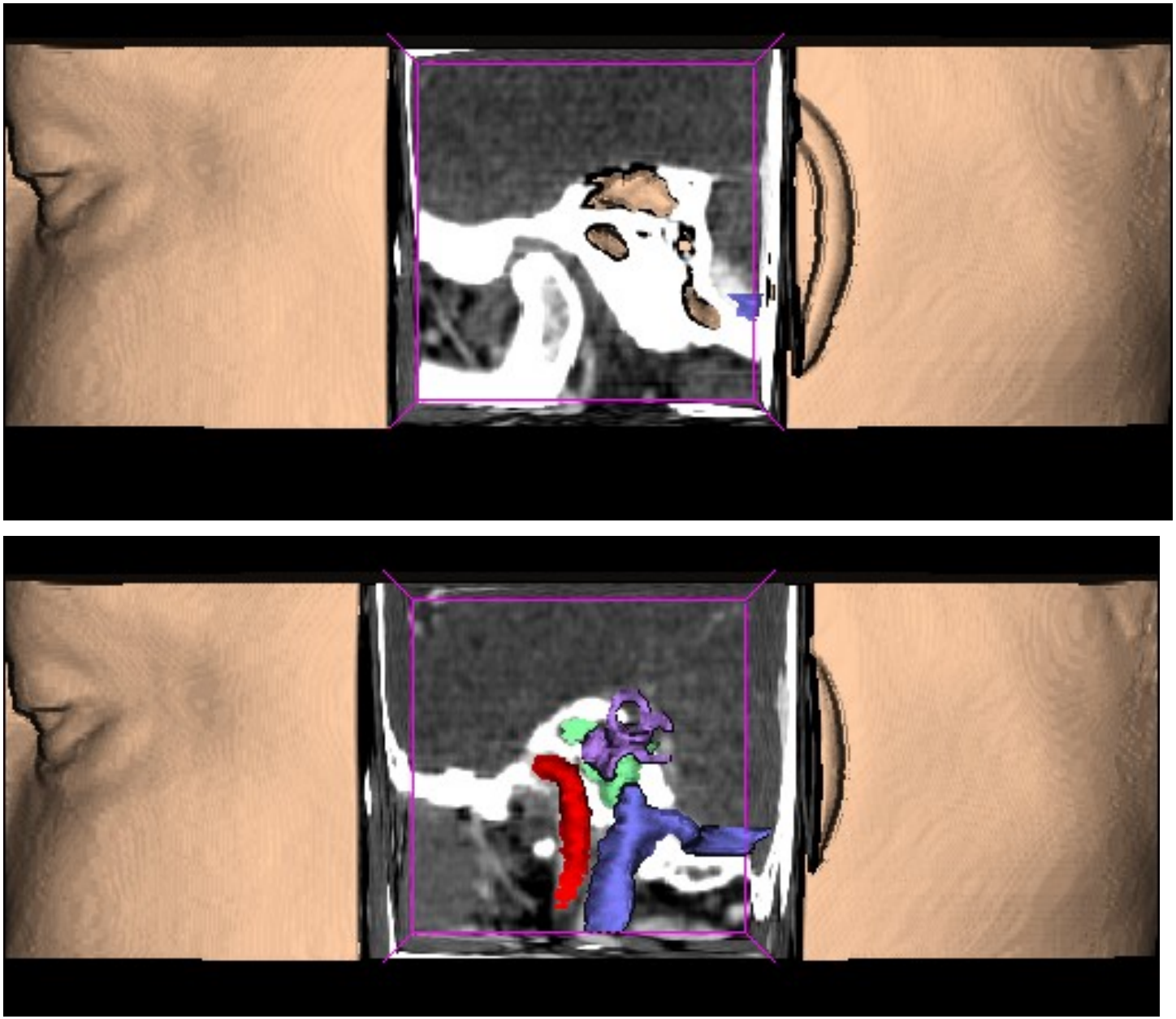

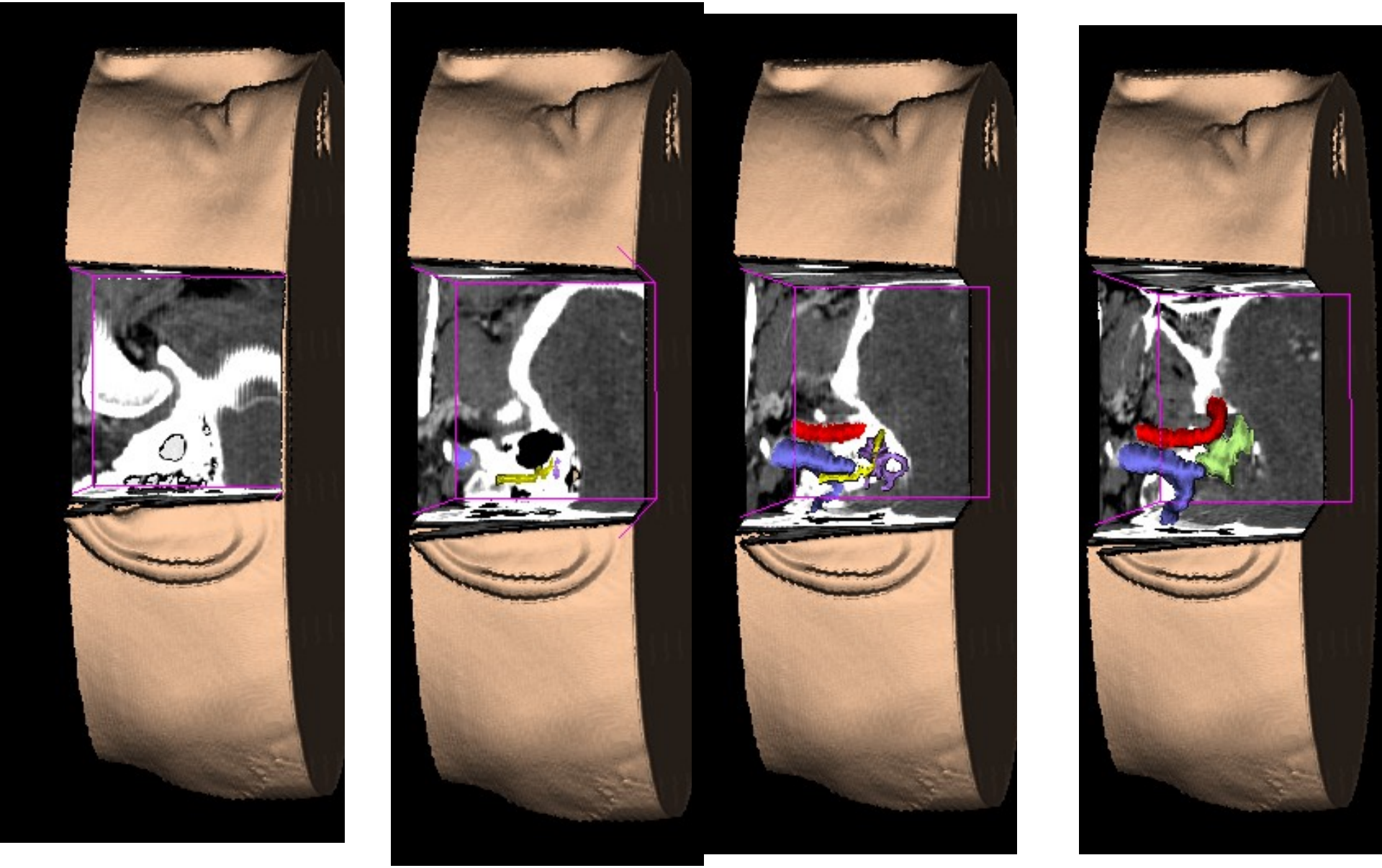

Imagerie 3D et Planification chirurgicale

Reconstructions 3D pas récentes

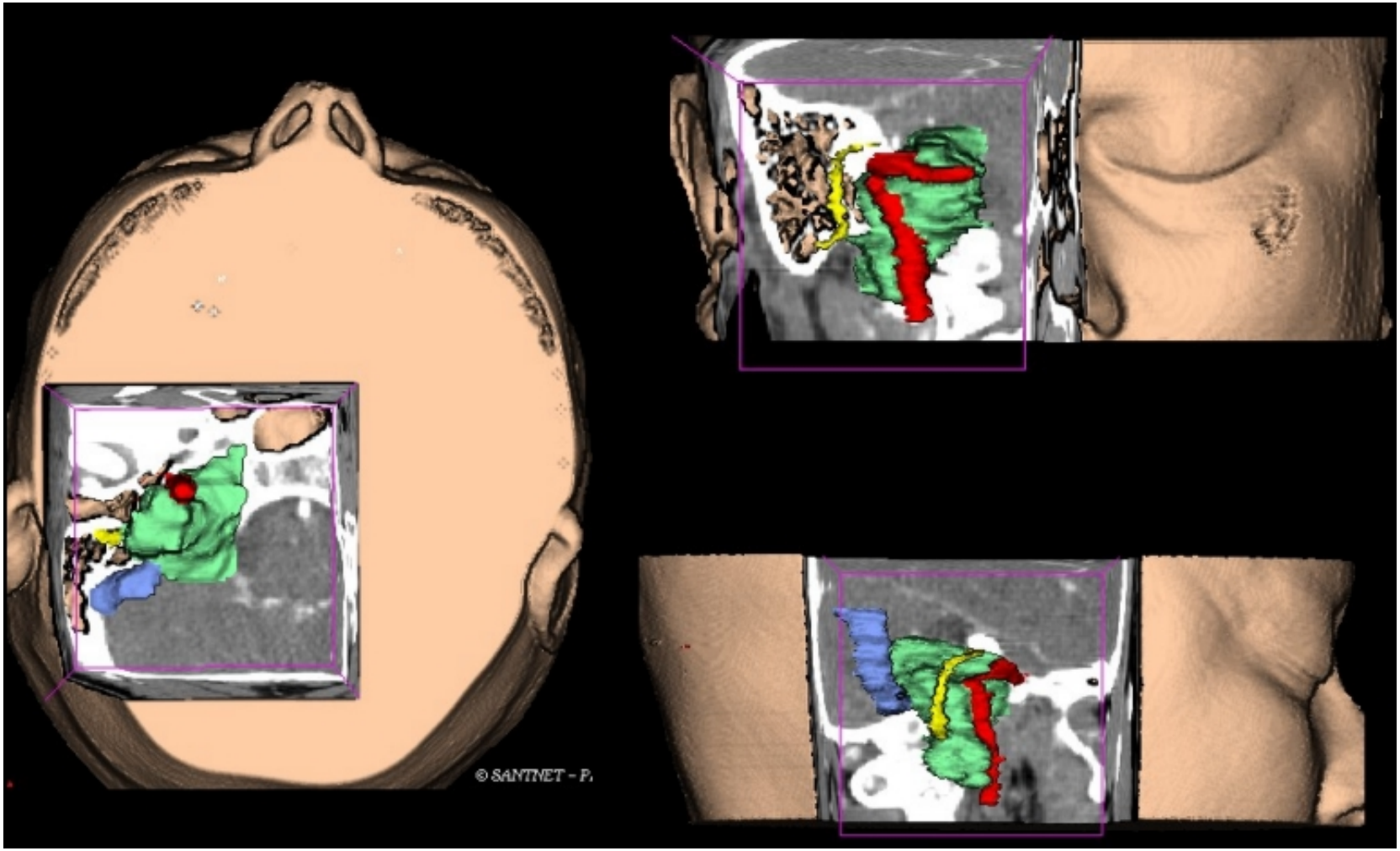

Imagerie 3D et Planification chirurgicale

Reconstructions 3D pas récentes

Imagerie 3D et Planification chirurgicale

Reconstructions 3D pas récentes

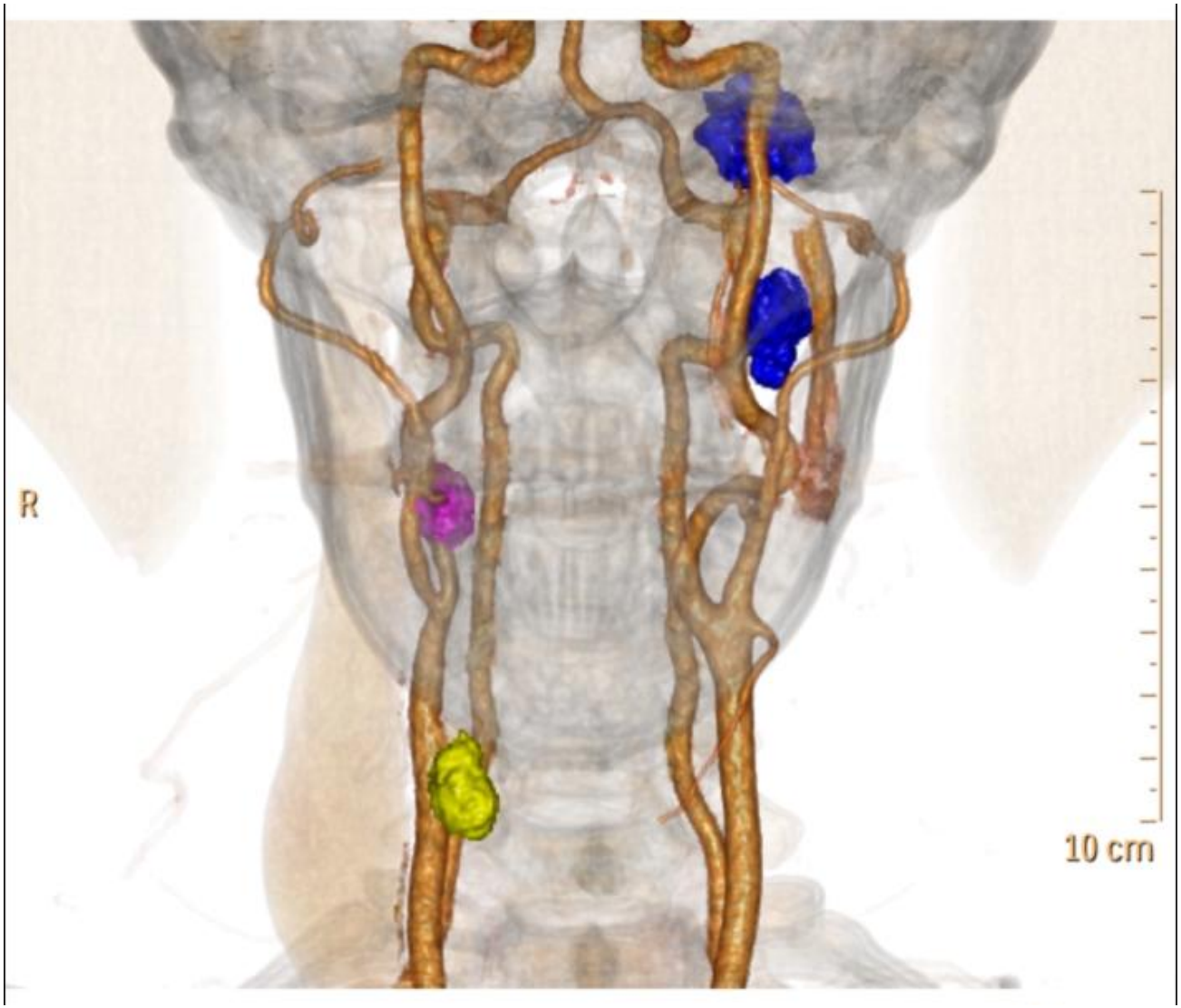

Volumineux paragangliome cervical droit

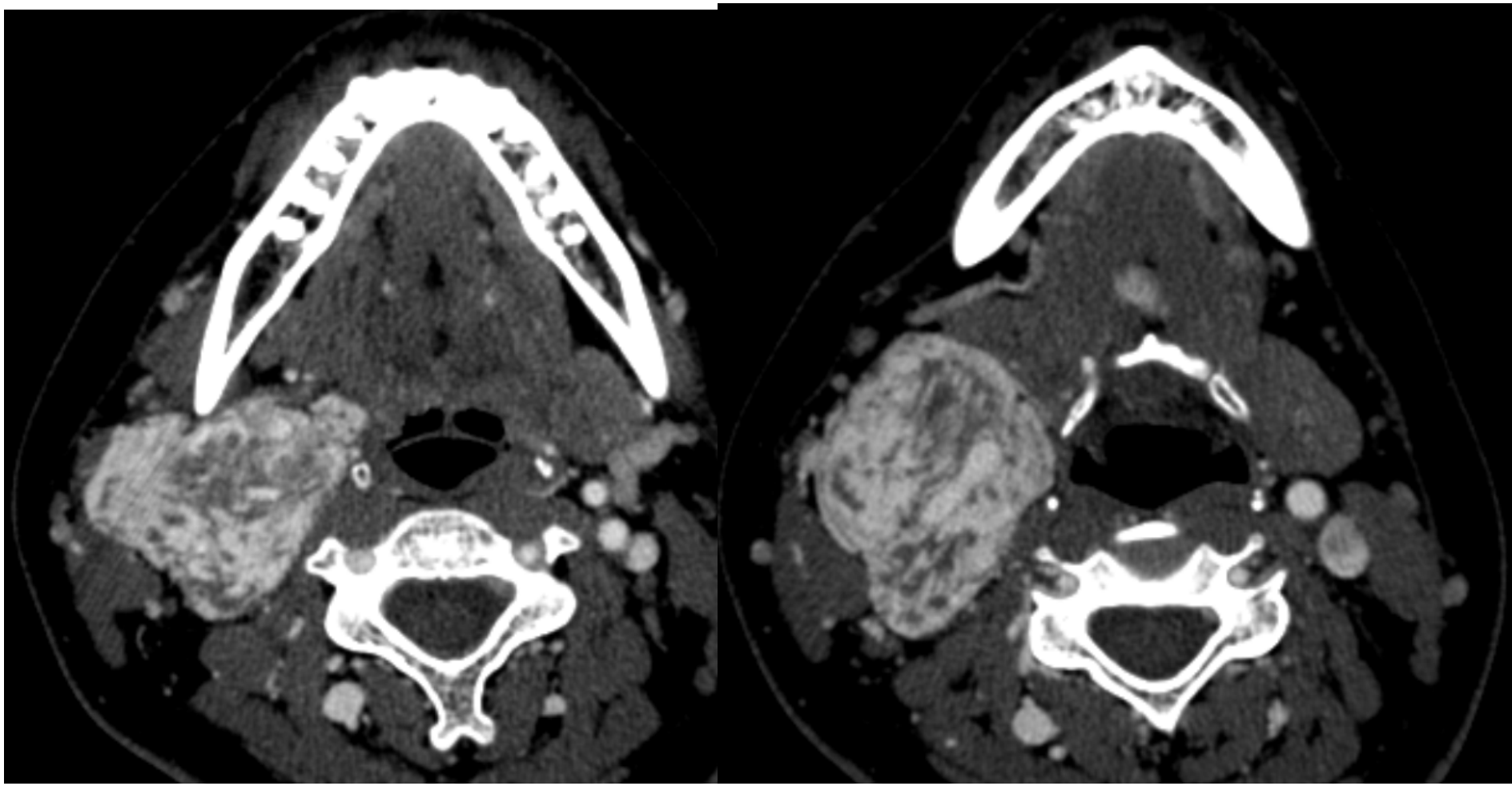

Volumineux paragangliome cervical droit

Volumineux paragangliome cervical droit

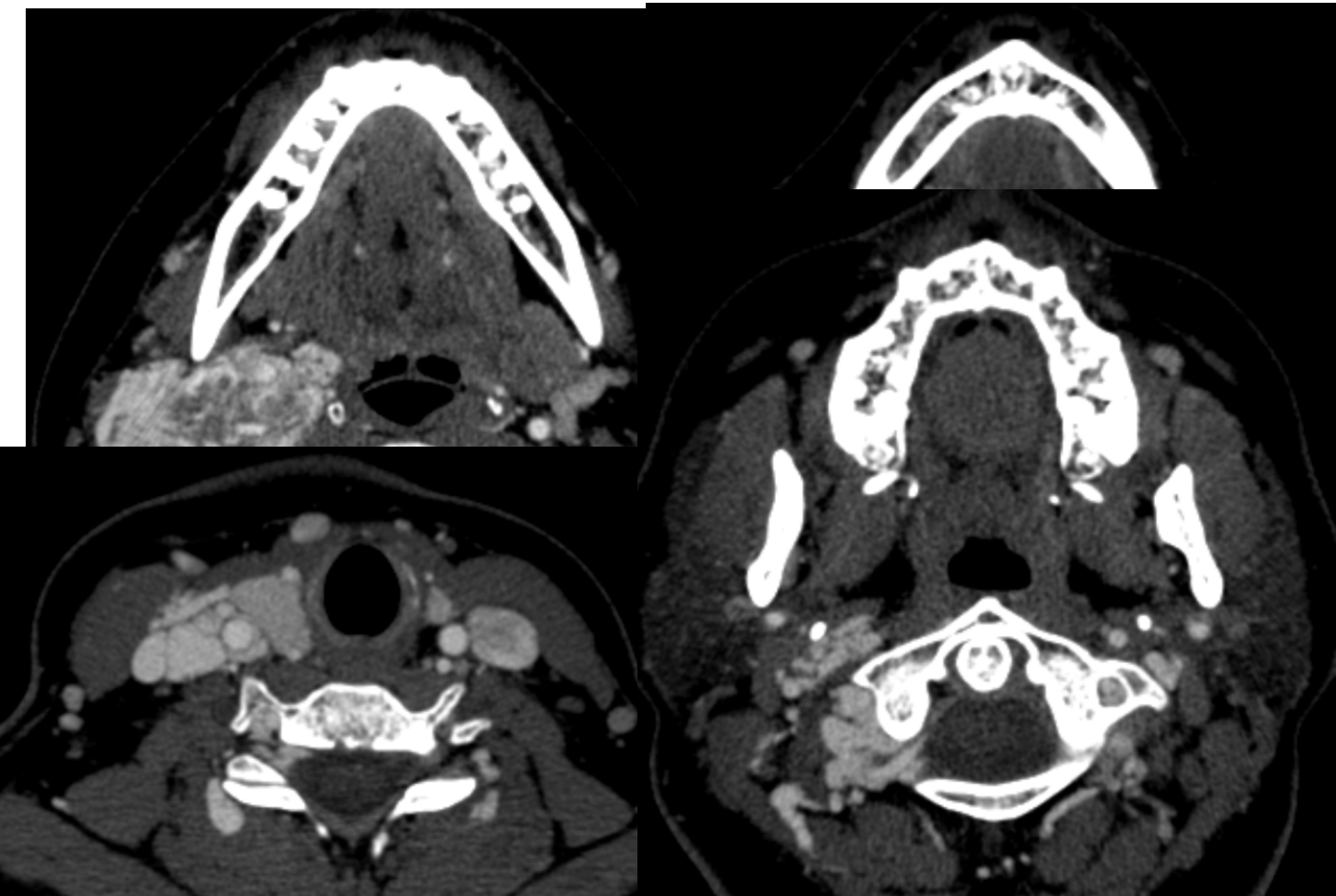

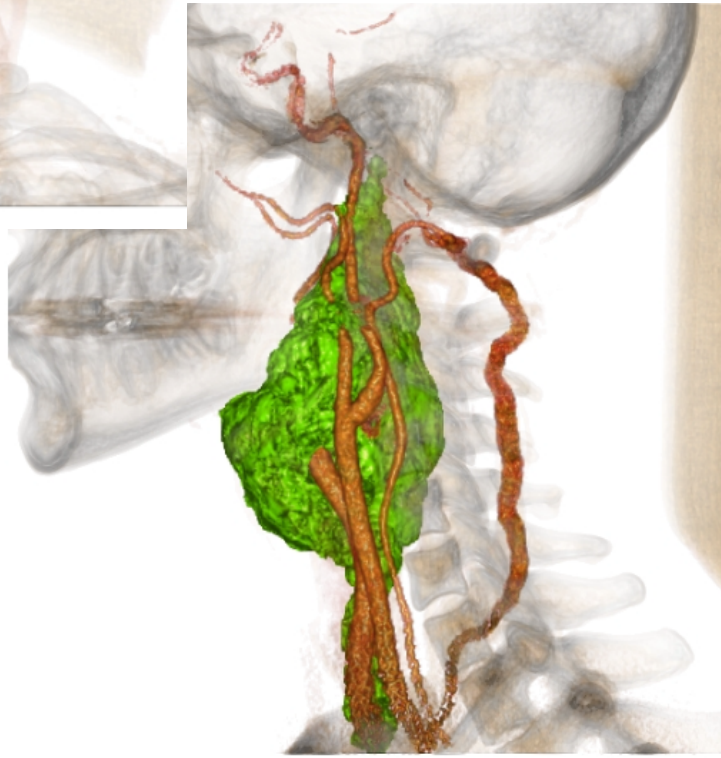

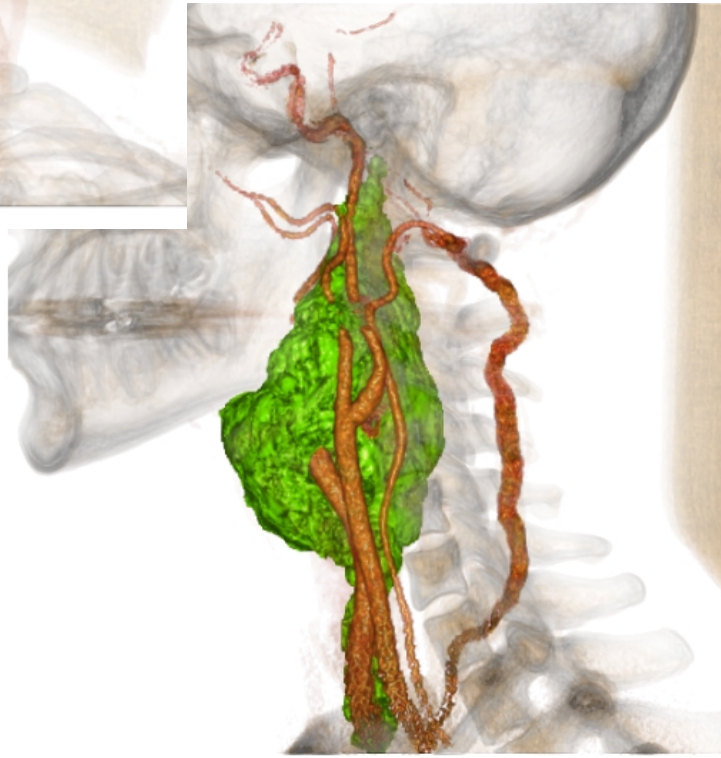

R

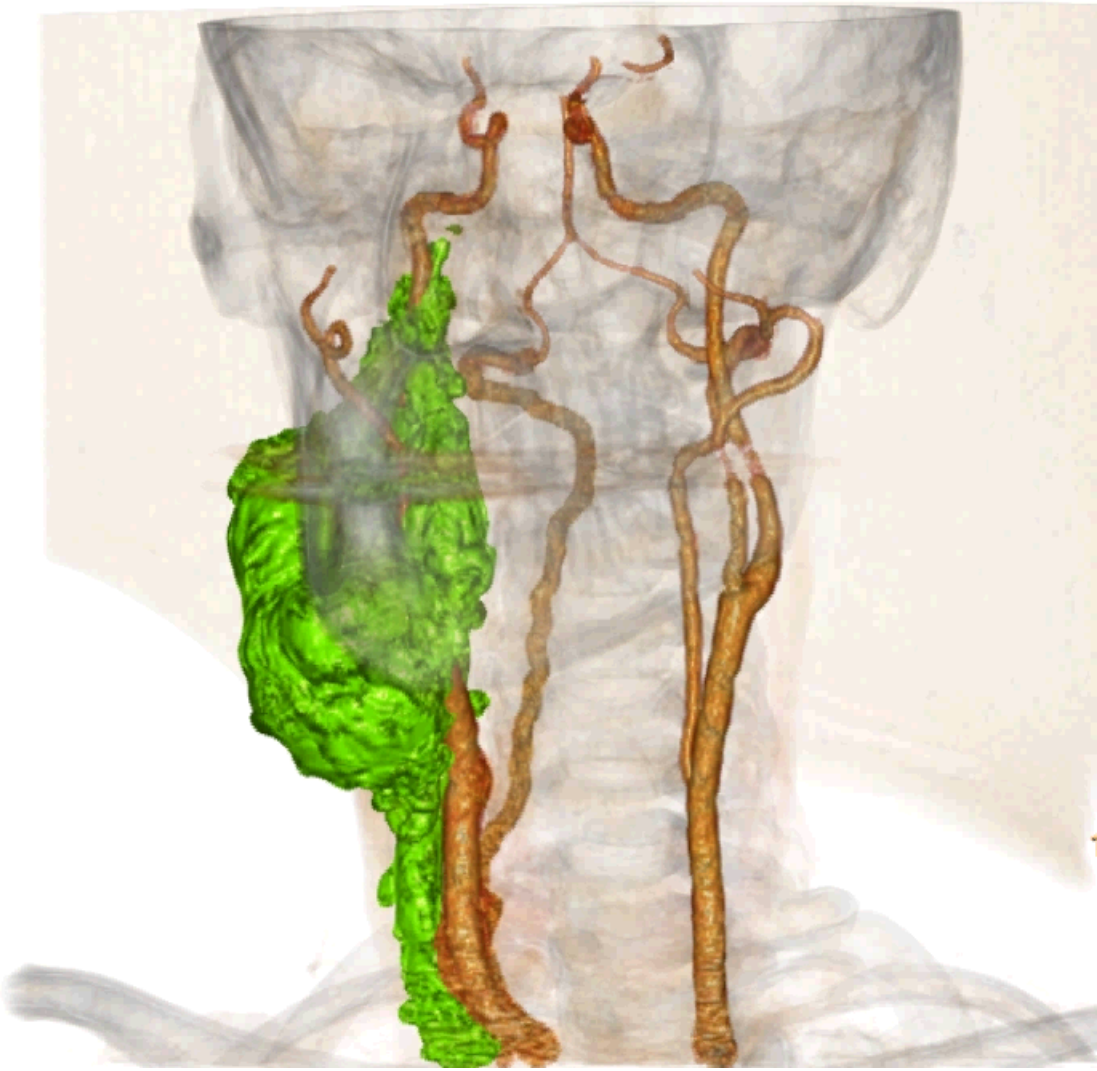

Imagerie 3D et chirurgie assistée par la robotique

Récent

Fusion de plusieurs modalités

pour délimiter au mieux la lésion et l'entourage vasculaire et nerveux
en gardant les repères osseux

Utilisation simultanée de plusieurs techniques

TDM – IRM - (TEP scanner)

Technologie Brainlab

VOIE SUS PETREUSE pour neurectomie vestibulaire

Acquisition de base: spirale TDM incluant l'ensemble du massif facial

Points de repères

VOIE SUS PETREUSE pour neurectomie vestibulaire

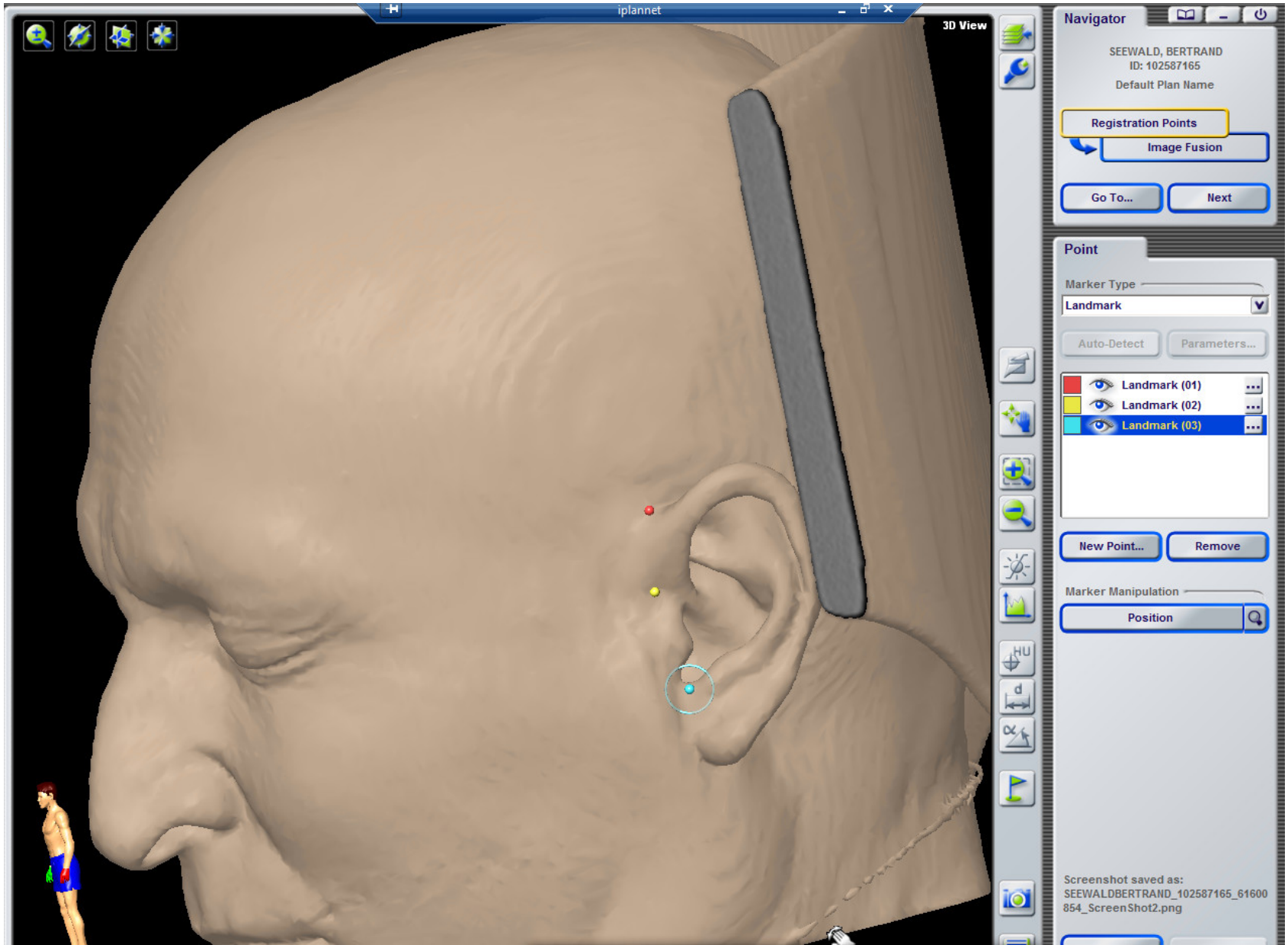

iplannet

#2 (CT; Axial)
[#1 (CT; Axial)]
Axial View

#2 (CT; Axial)
#1 (CT; Axial)
Axial View
Fusion type: Manual

#2 (CT; Axial)
#1 (CT; Axial)
Sagittal View

#2 (CT; Axial)
#1 (CT; Axial)
Coronal View

Fusion type: Manual

Navigator

SEEWALD, BERTRAND
ID: 102587165
Default Plan Name

Image Fusion
Object Creation

Go To... | Next

Fusion

#2 (CT; Axial) -#1 (CT; Axial)

New Pair... | Reset

#2 (CT; Axial) #1 (CT; Axial)

Edges | Edges

Manual Fusion

Coarse | Fine

Automatic Fusion

Auto Fusion | Modify ROI...

Show Fusion ROI

Registration Point Fusion

Fuse Points | Alternatives

Please verify the fusion result before proceeding

Screenshot saved as:
SEEWALDBERTRAND_102587165_61600854_ScreenShot3.png

Fusion manuelle + automatique des séries

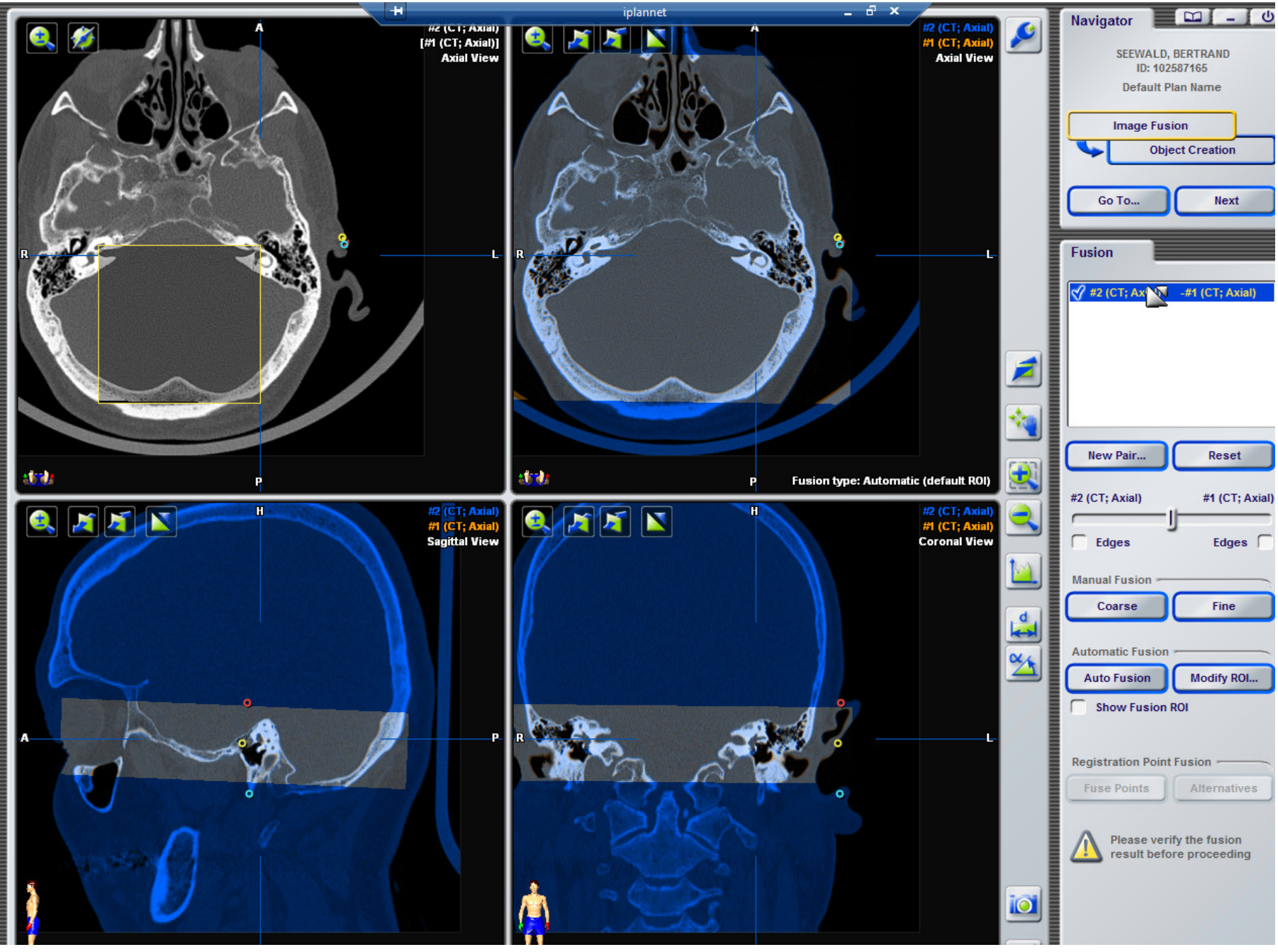

Contourage manuel + automatique CSC supérieur

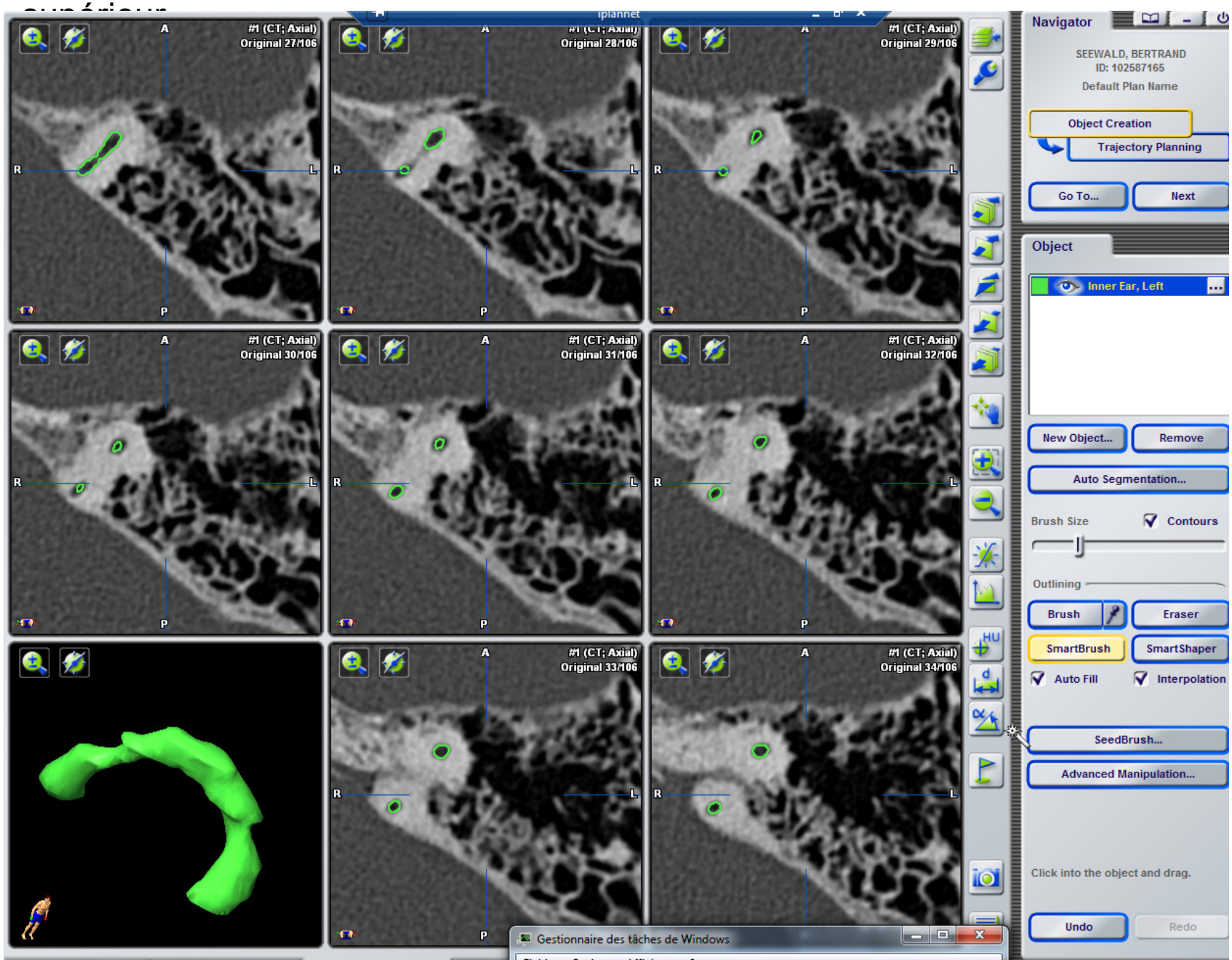

Contourage manuel + automatique CSC supérieur +zone de sécurité

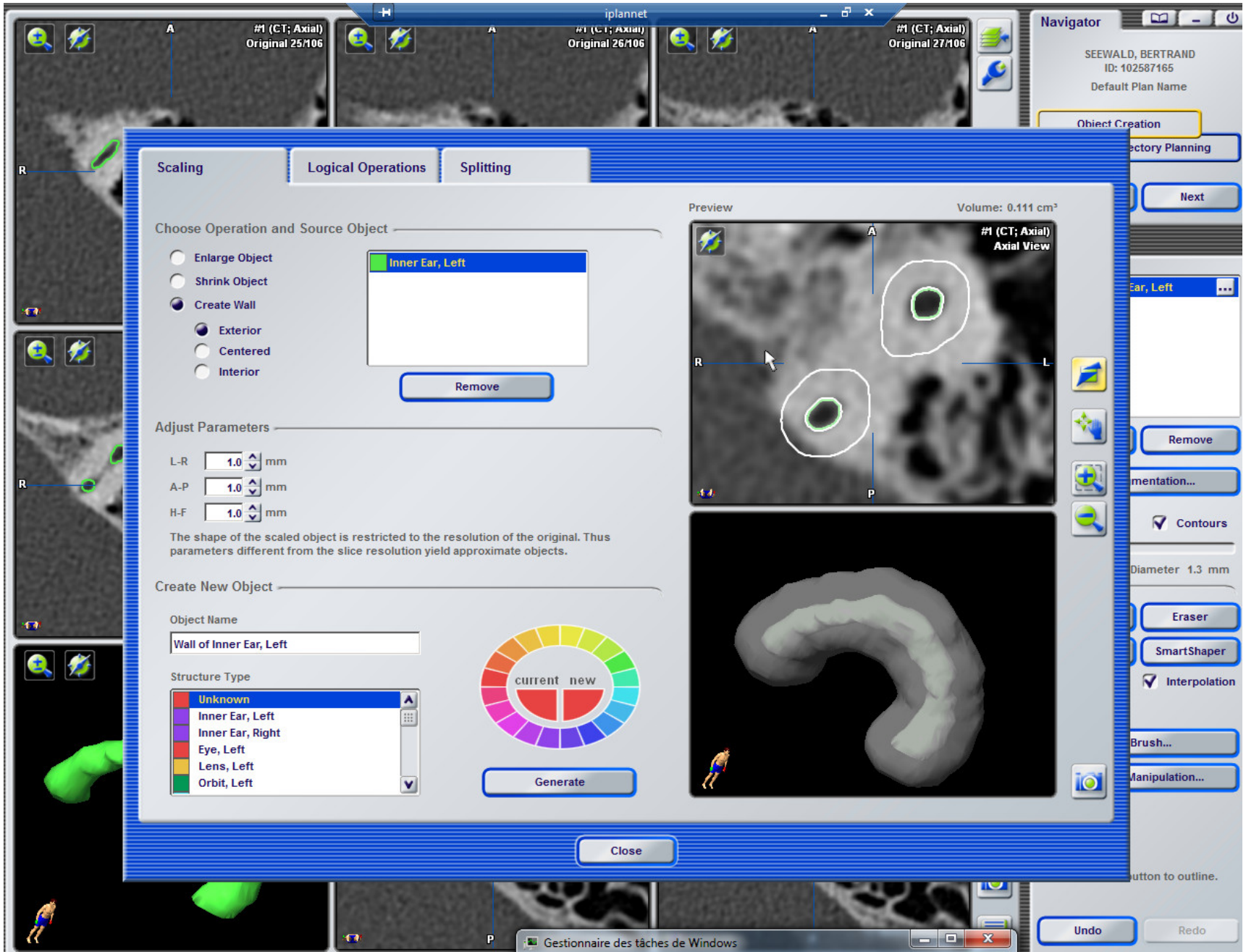

Contourage manuel + automatique CSC supérieur +zone de sécurité

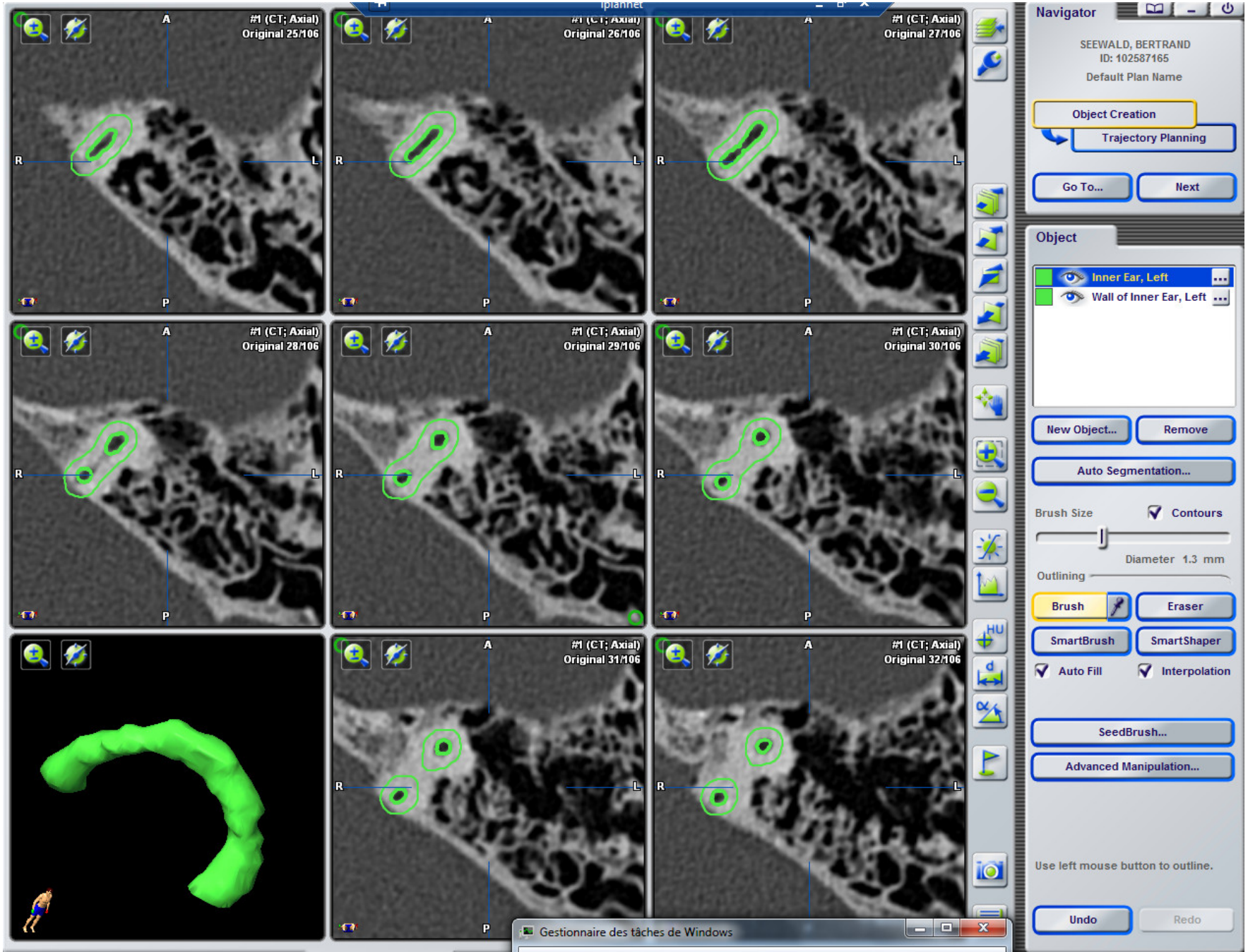

Contourage manuel + automatique nerf facial 1ère portion - début des nerfs pétreux

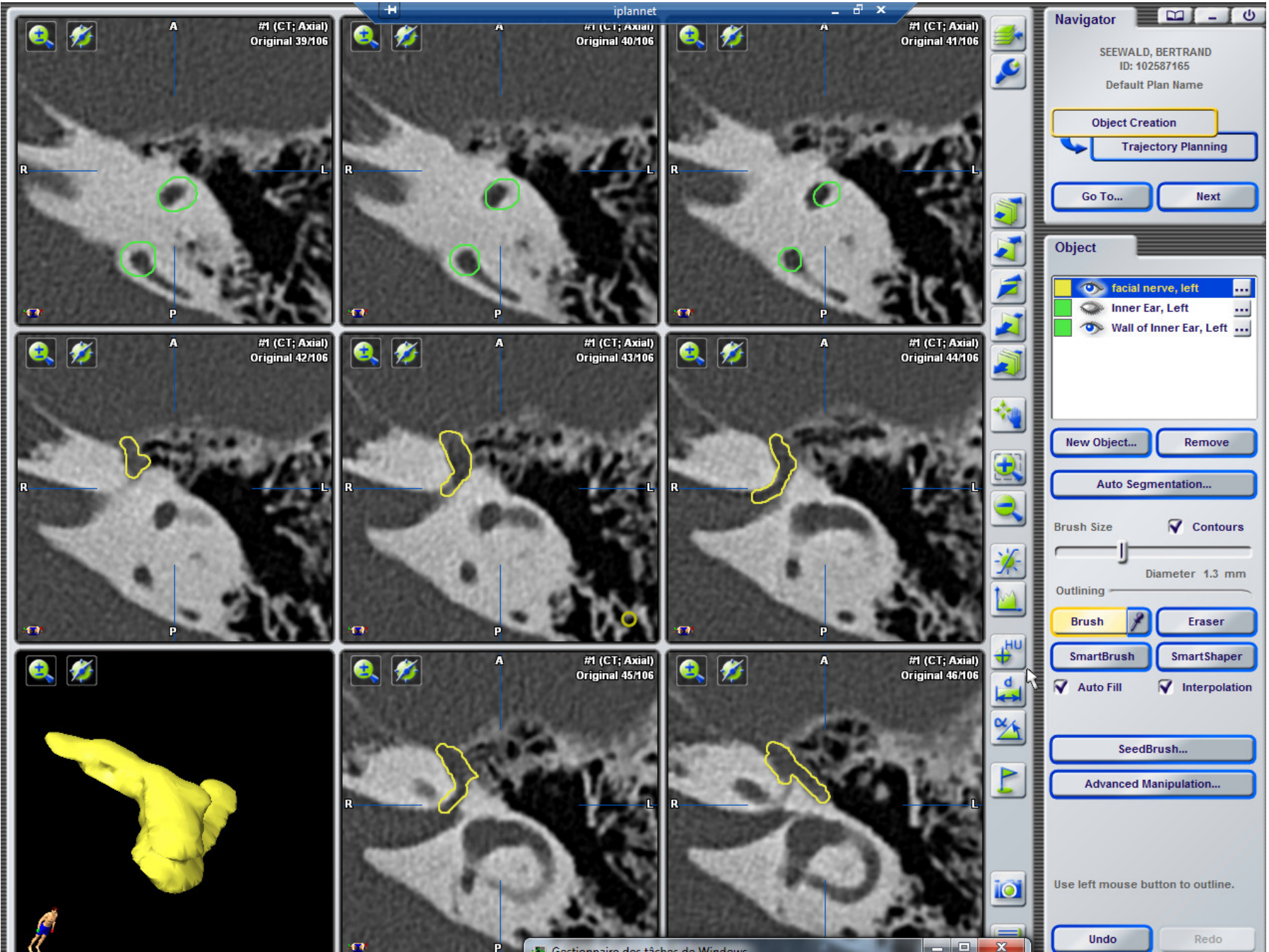

Contourage manuel + automatique nerfs vestibulaires sup et inf

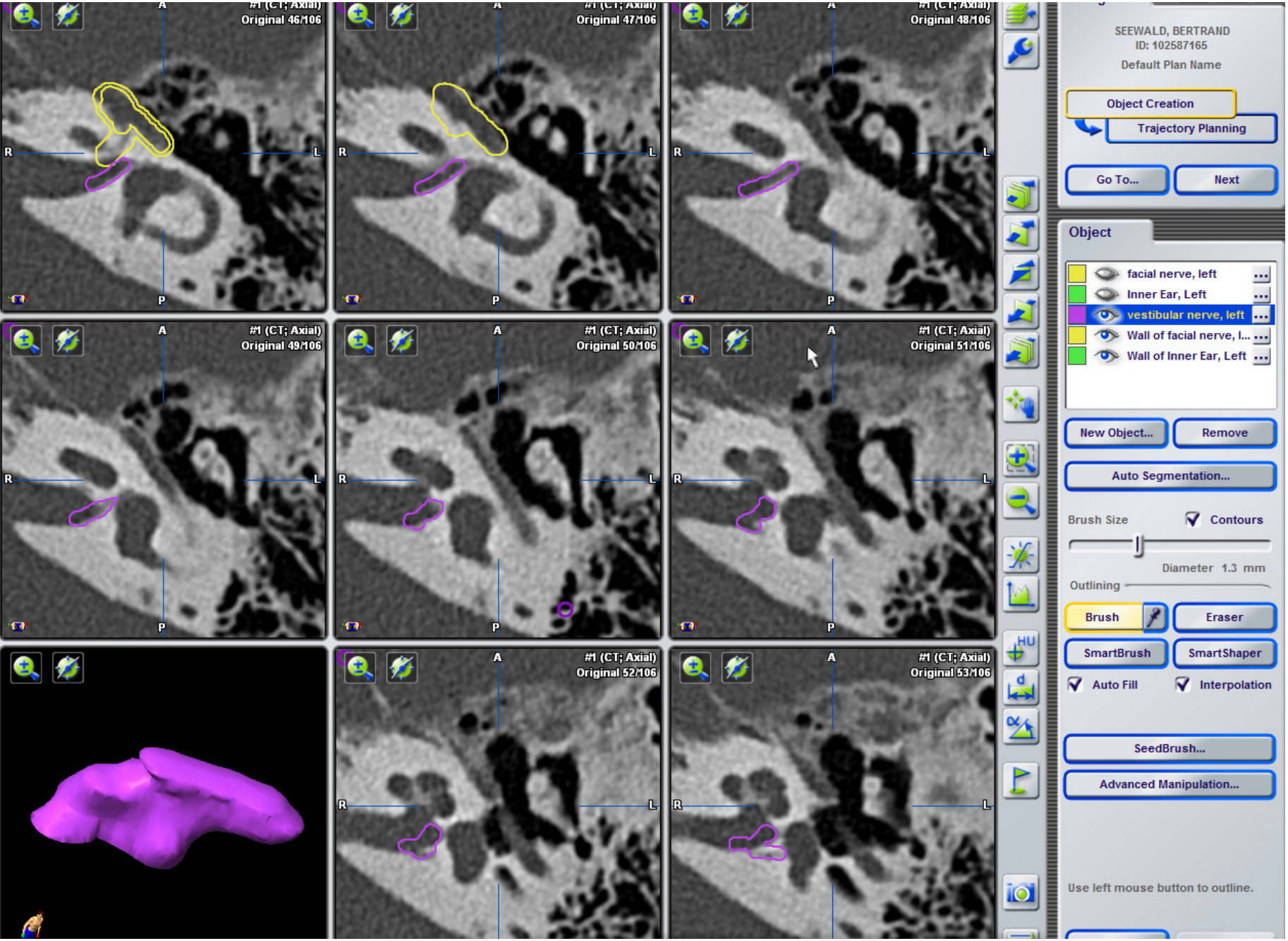

Planification 3D et vue en position opératoire

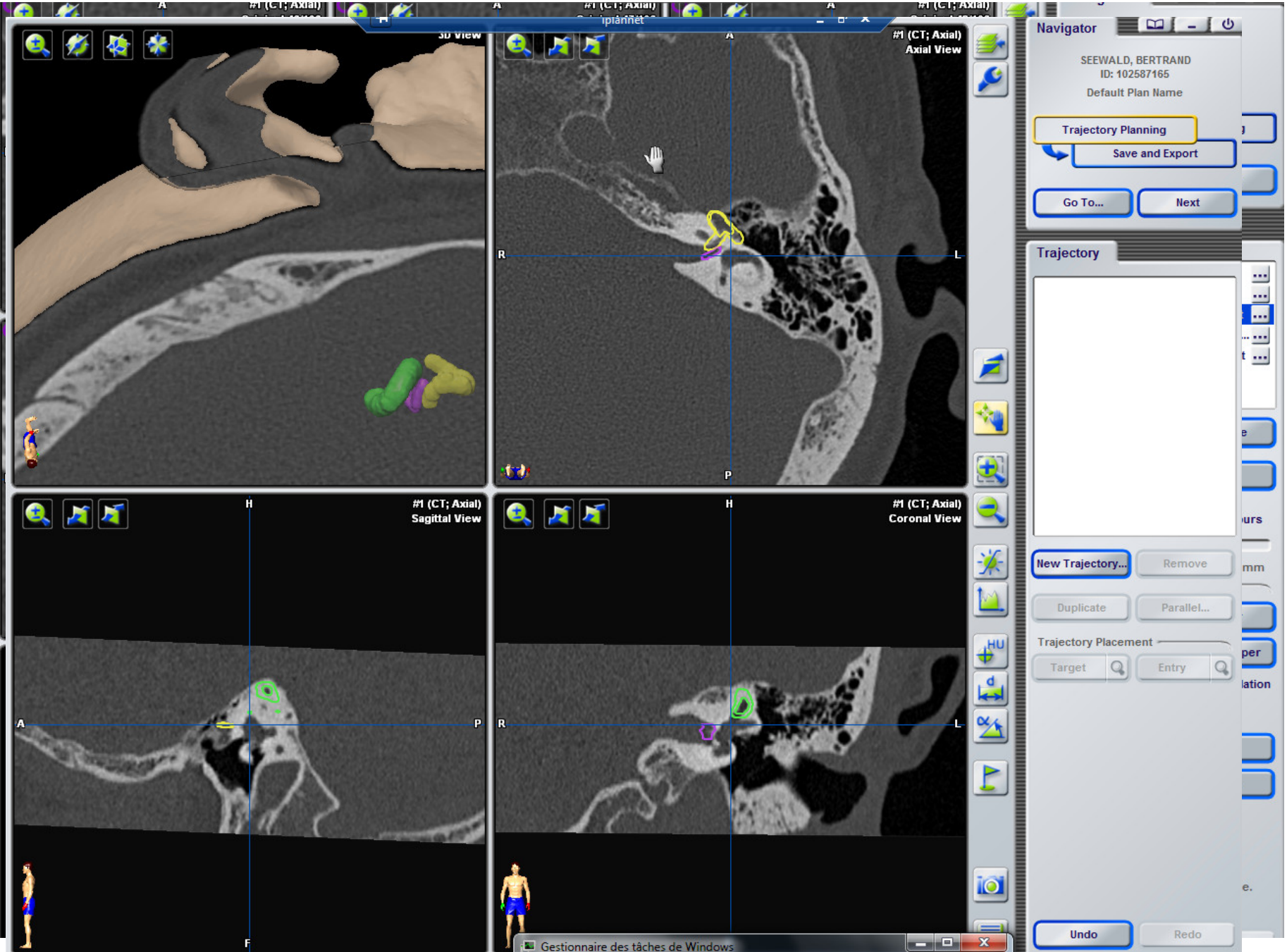

voie sus-pétreuse

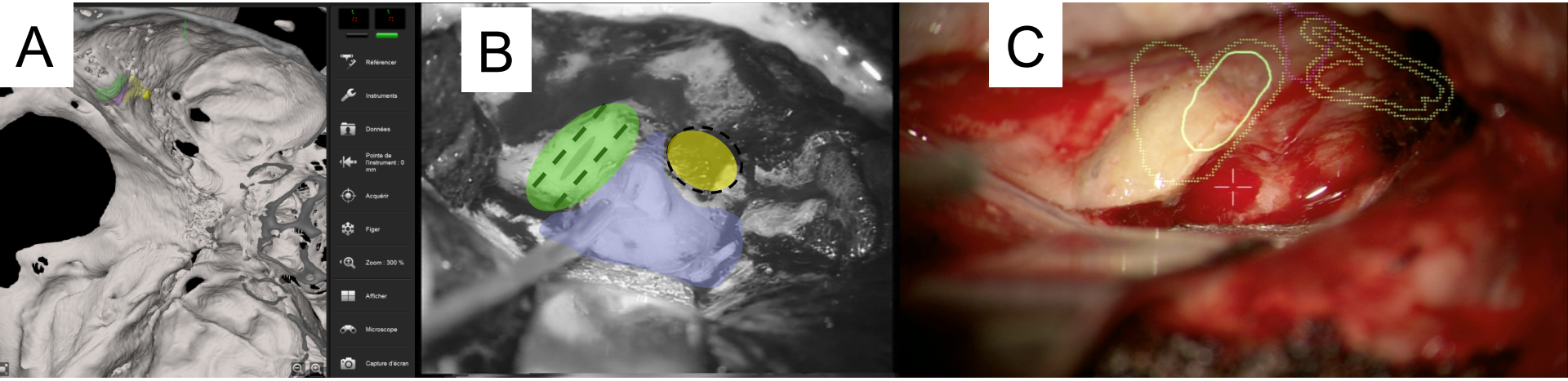

Abord du conduit auditif interne par voie sus-pétreuse:

A.Reconstruction tridimensionnelle de la base du crâne figurant l'oreille interne (vert), le nerf facial (jaune), l'espace de décompression (violet)
B.Vue peropératoire avec représentation schématique des zones projetées en A
C.Vue peropératoire en réalité augmentée

Patiente
Cholesteatome droit multi-opéré
Extension intrapétreuse

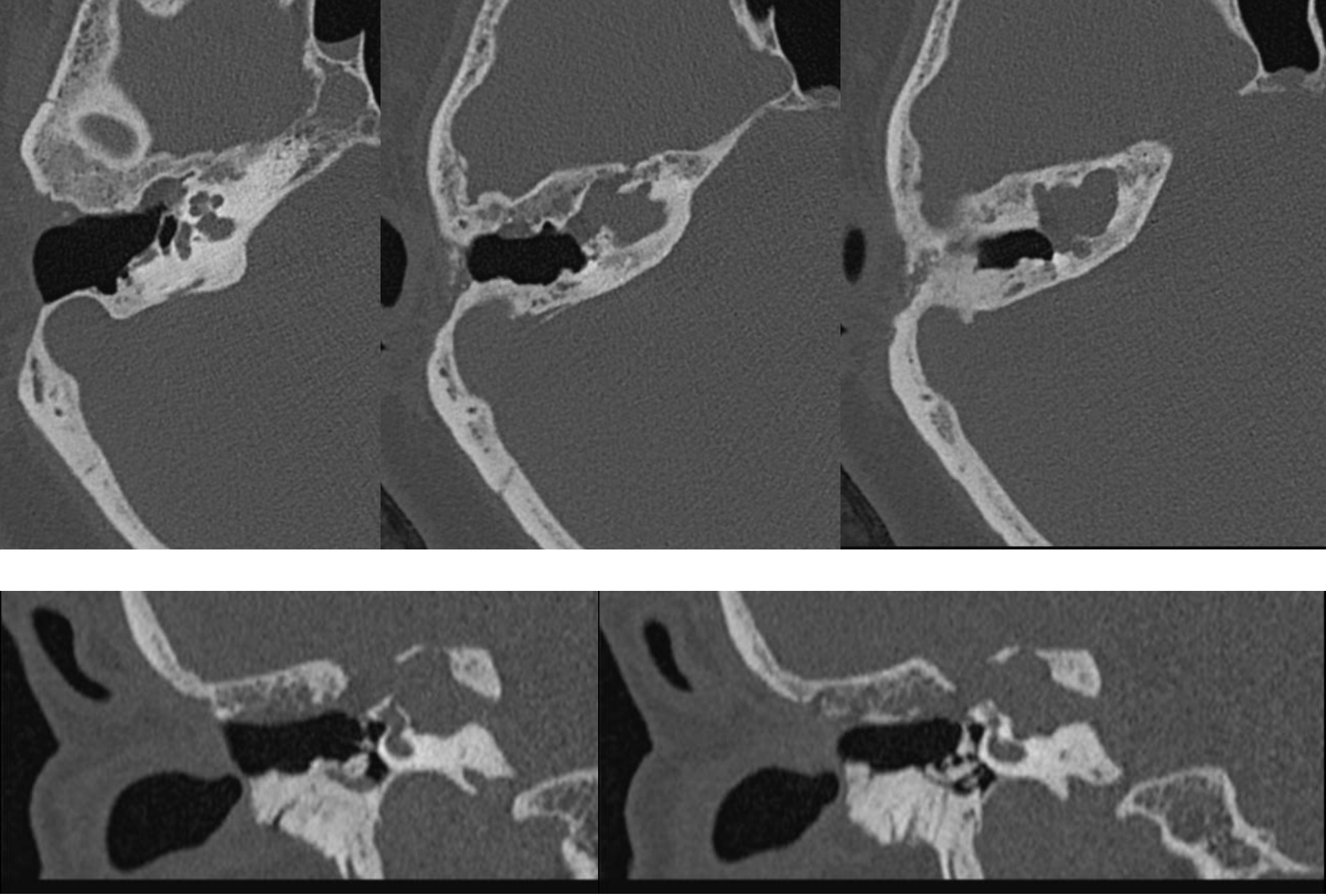

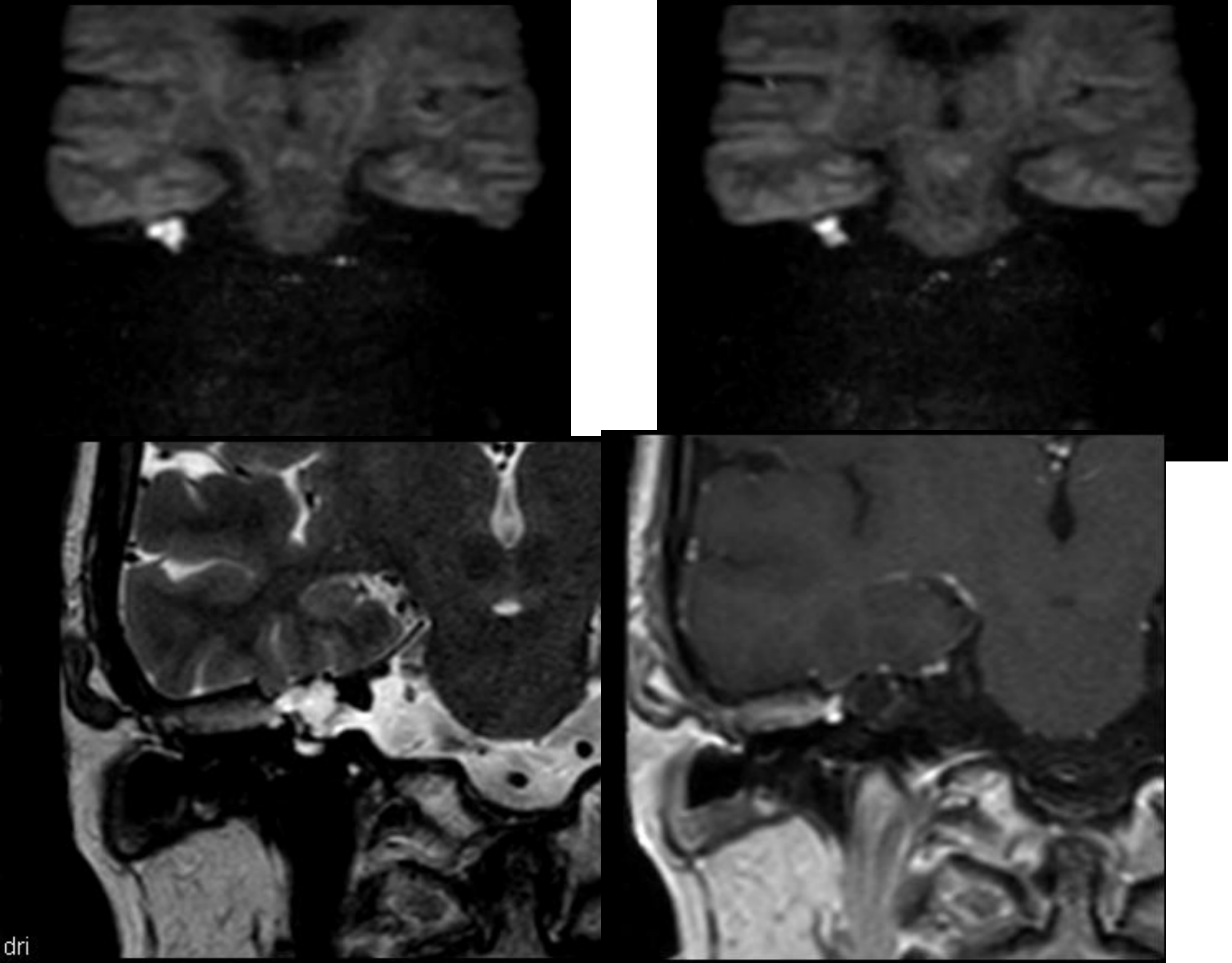
dri

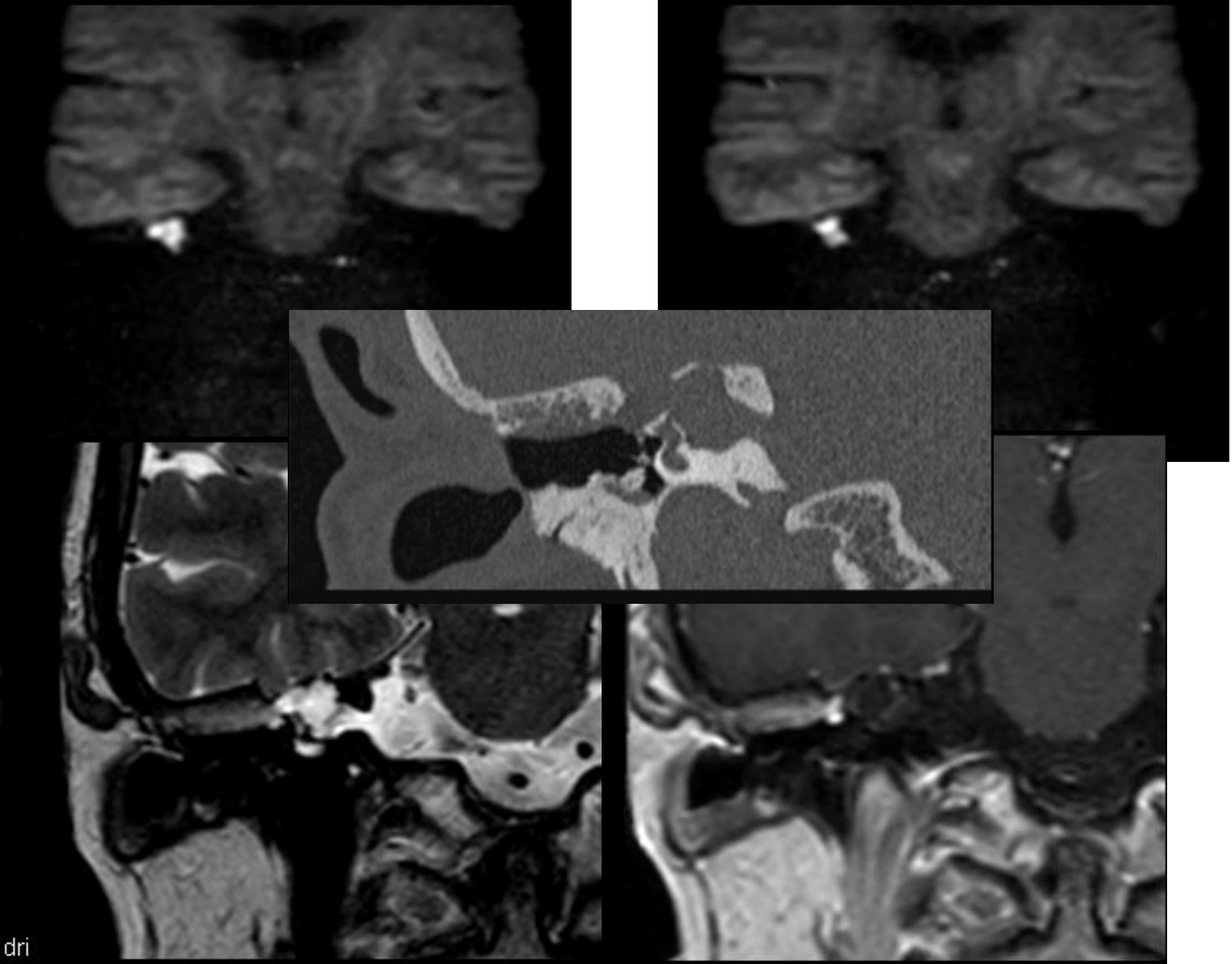
dri

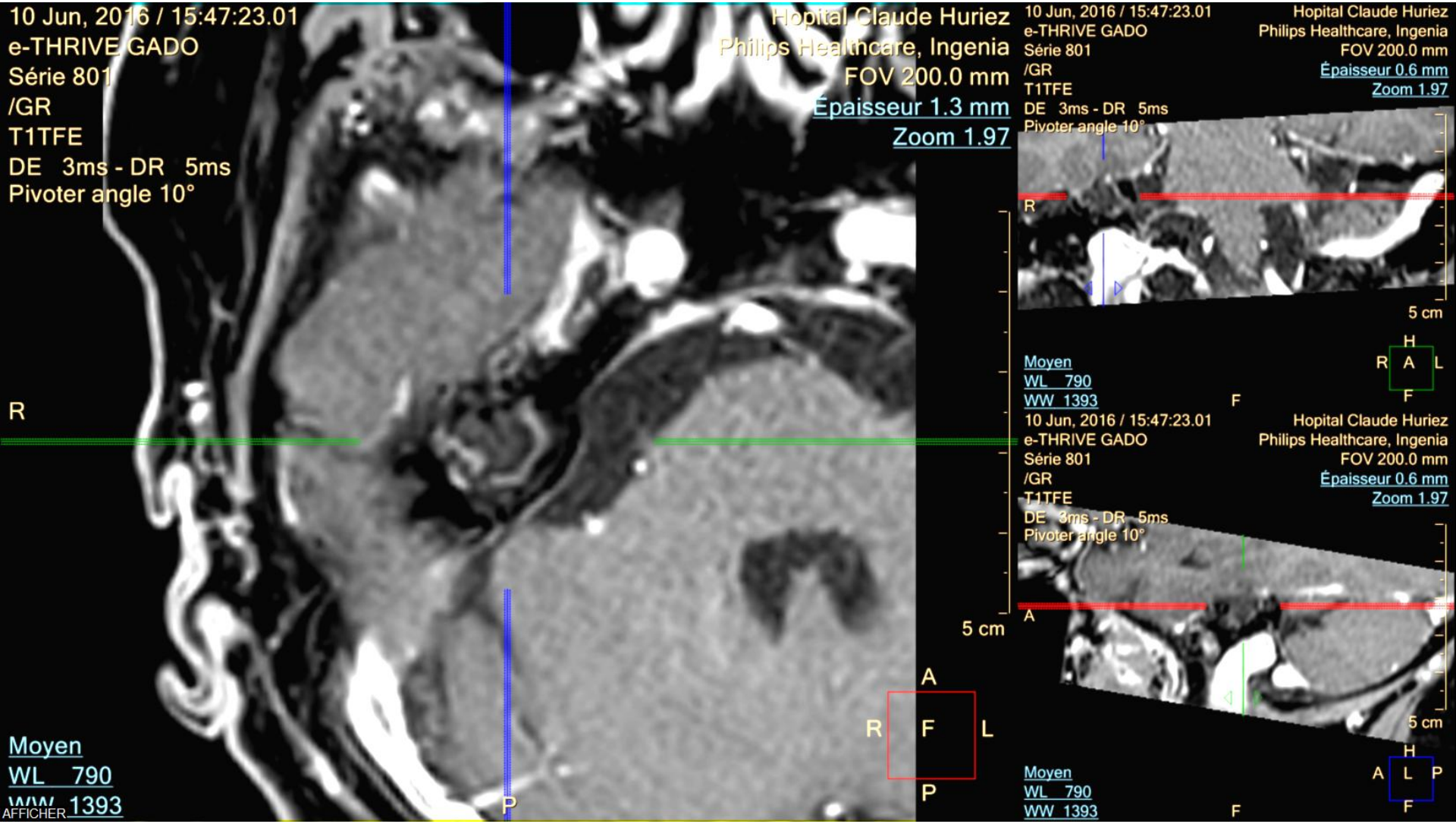
10 Jun, 2016 / 15:47:23.01
e-THRIVE GADO
Série 801
/GR
T1TFE
DE 3ms - DR 5ms
Pivoter angle 10°
Hopital Claude Huriez
Philips Healthcare, Ingenia
FOV 200.0 mm
Épaisseur 1.3 mm
Zoom 1.97
R
P
5 cm
A
R F L
P
Moyen
WL 790
WW 1393
AFFICHER
10 Jun, 2016 / 15:47:23.01
e-THRIVE GADO
Série 801
/GR
T1TFE
DE 3ms - DR 5ms
Pivoter angle 10°
Hopital Claude Huriez
Philips Healthcare, Ingenia
FOV 200.0 mm
Épaisseur 0.6 mm
Zoom 1.97
R
5 cm
Moyen
WL 790
WW 1393
F
H
R A L
F
10 Jun, 2016 / 15:47:23.01
e-THRIVE GADO
Série 801
/GR
T1TFE
DE 3ms - DR 5ms
Pivoter angle 10°
Hopital Claude Huriez
Philips Healthcare, Ingenia
FOV 200.0 mm
Épaisseur 0.6 mm
Zoom 1.97
A
5 cm
Moyen
WL 790
WW 1393
F
H
A L P
F

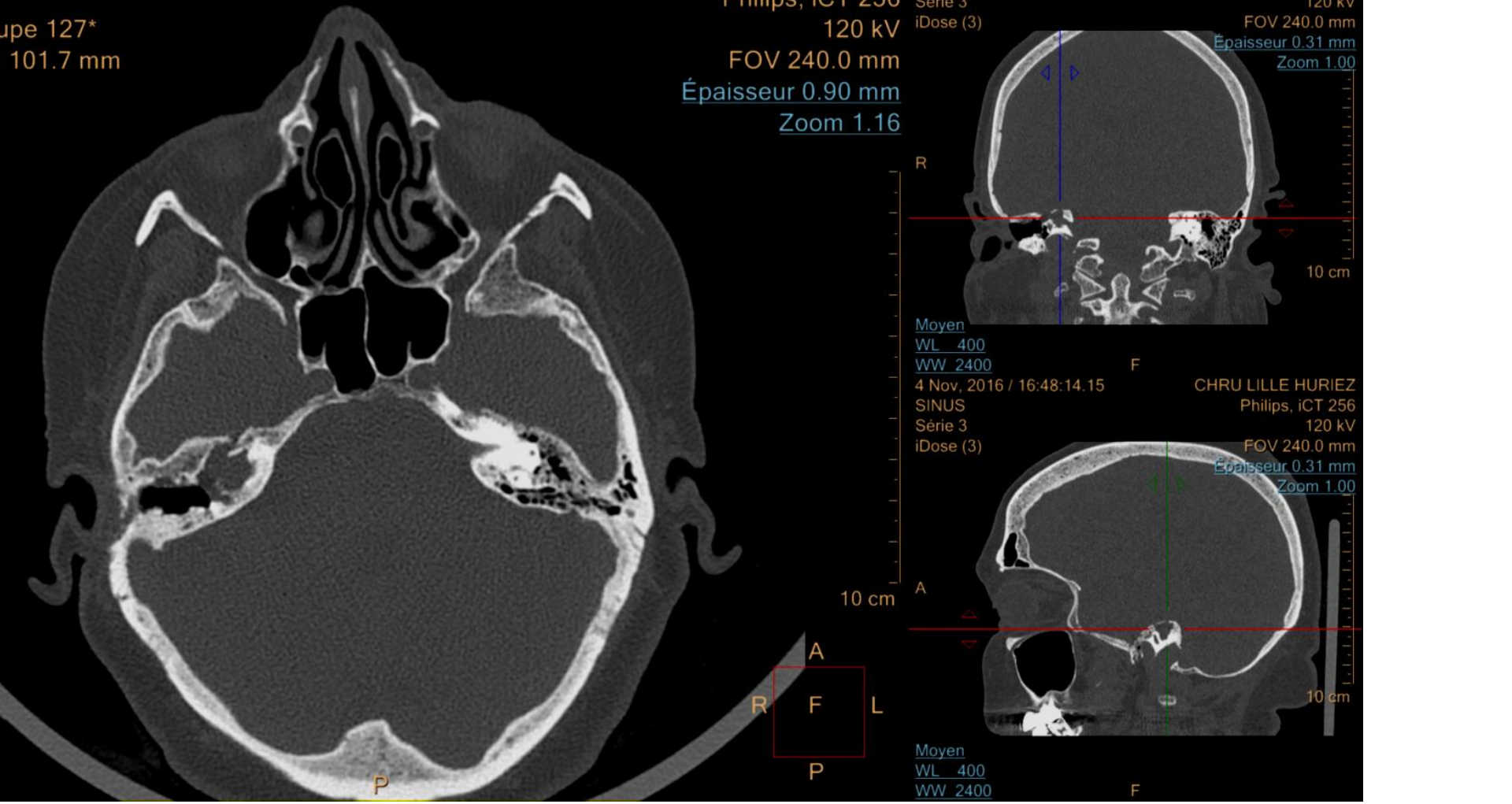
upe 127*
101.7 mm
Philips, iCT 256
120 kV
FOV 240.0 mm
Épaisseur 0.90 mm
Zoom 1.16
Série 3
iDose (3)
FOV 240.0 mm
Épaisseur 0.31 mm
Zoom 1.00
R
10 cm
Moyen
WL 400
WW 2400
F
4 Nov, 2016 / 16:48:14.15
SINUS
Série 3
iDose (3)
CHRU LILLE HURIEZ
Philips, iCT 256
120 kV
FOV 240.0 mm
Épaisseur 0.31 mm
Zoom 1.00
A
10 cm
A
R
F
L
P
P
Moyen
WL 400
WW 2400
F

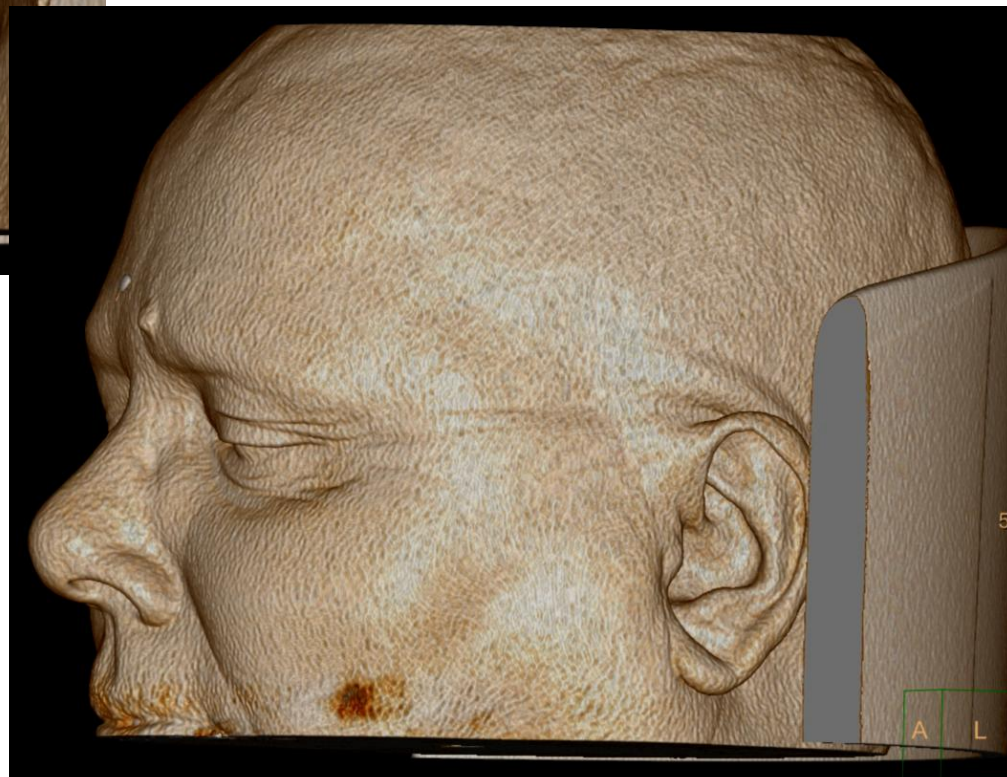
A
L

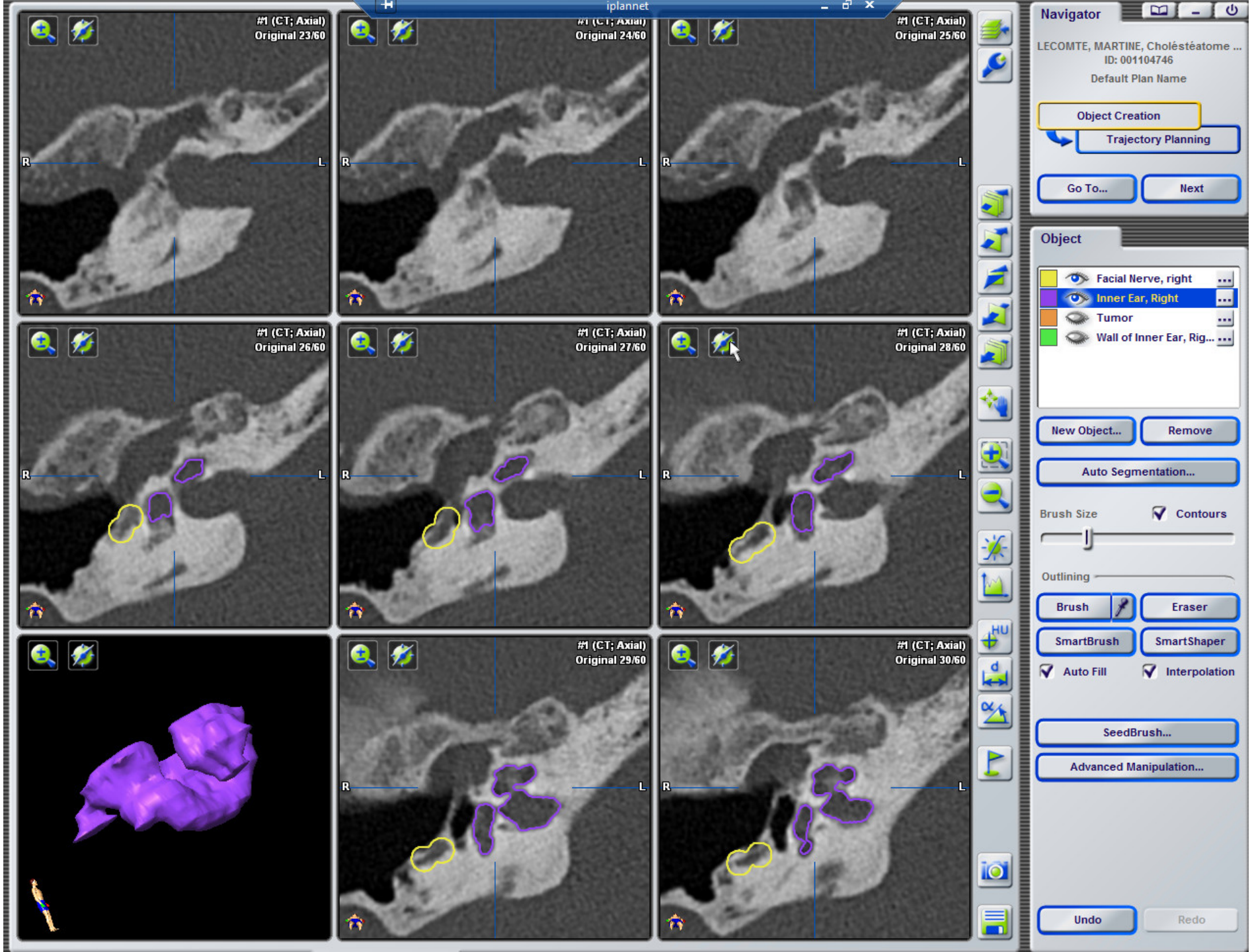
iplannet
#1 (CT; Axial)
Original 23/60
Original 24/60
Original 25/60
Original 26/60
Original 27/60
Original 28/60
Original 29/60
Original 30/60
R
L
Navigator
LECOMTE, MARTINE, Cholestéatome ...
ID: 001104746
Default Plan Name
Object Creation
Trajectory Planning
Go To...
Next
Object
Facial Nerve, right
Inner Ear, Right
Tumor
Wall of Inner Ear, Rig...
New Object...
Remove
Auto Segmentation...
Brush Size
Contours
Outlining
Brush
Eraser
SmartBrush
SmartShaper
Auto Fill
Interpolation
SeedBrush...
Advanced Manipulation...
Undo
Redo

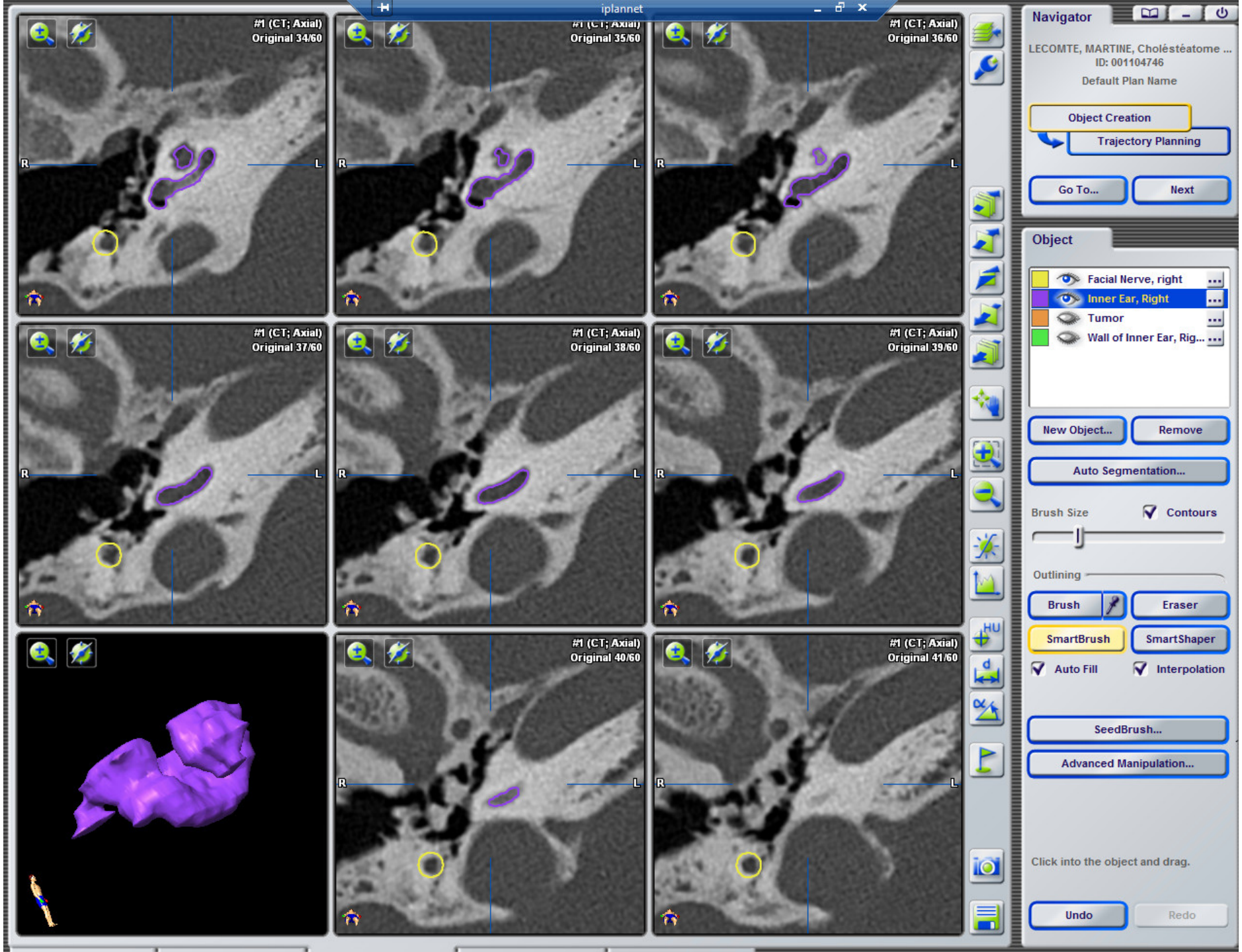
iplannet
#1 (CT; Axial)
Original 34/60
#1 (CT; Axial)
Original 35/60
#1 (CT; Axial)
Original 36/60
#1 (CT; Axial)
Original 37/60
#1 (CT; Axial)
Original 38/60
#1 (CT; Axial)
Original 39/60
#1 (CT; Axial)
Original 40/60
#1 (CT; Axial)
Original 41/60
R
L
Navigator
LECOMTE, MARTINE, Cholestéatome ...
ID: 001104746
Default Plan Name
Object Creation
Trajectory Planning
Go To...
Next
Object
Facial Nerve, right
Inner Ear, Right
Tumor
Wall of Inner Ear, Rig...
New Object...
Remove
Auto Segmentation...
Brush Size
Contours
Outlining
Brush
Eraser
SmartBrush
SmartShaper
Auto Fill
Interpolation
SeedBrush...
Advanced Manipulation...
Click into the object and drag.
Undo
Redo

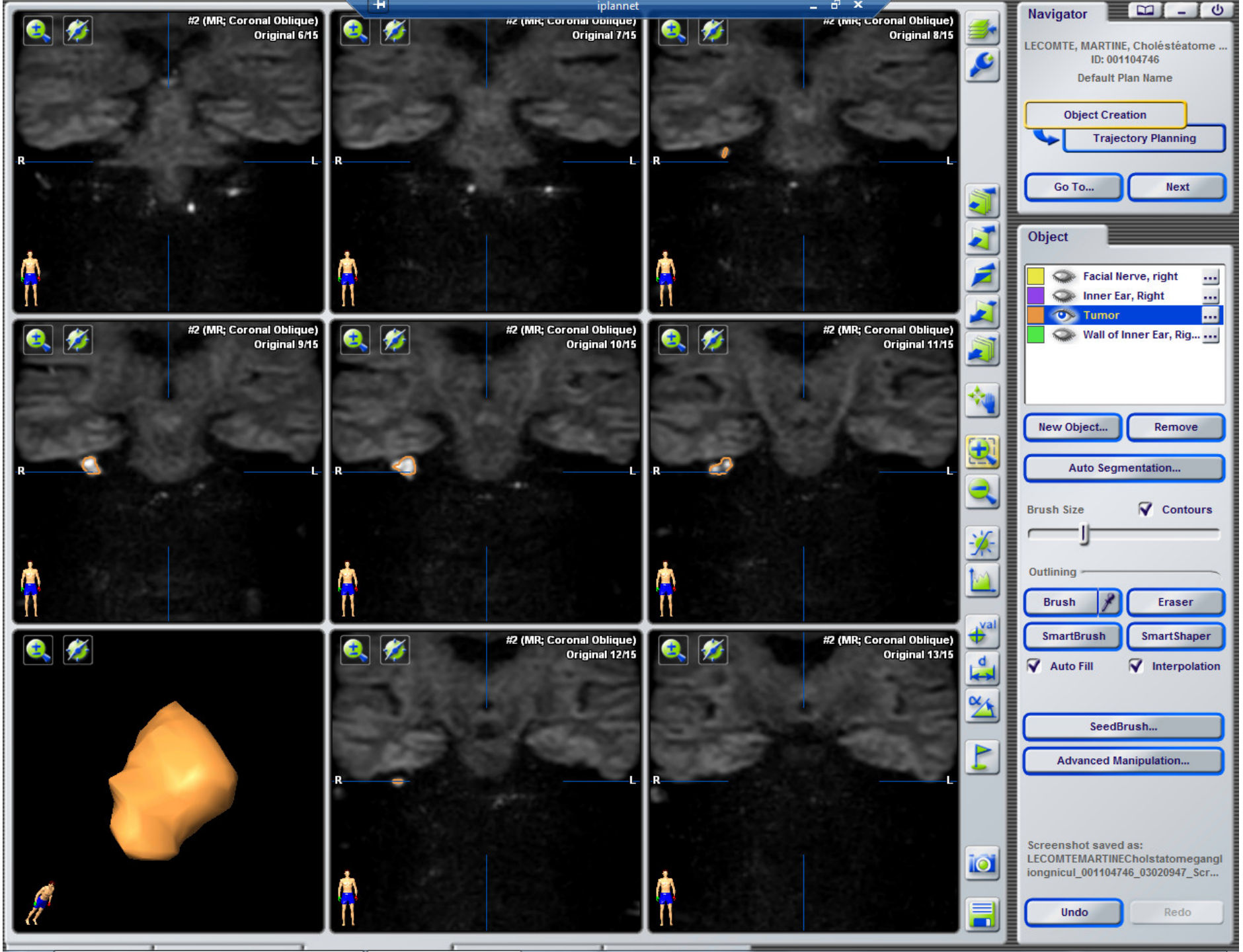
iplannet
#2 (MR; Coronal Oblique)
Original 6/15
Original 7/15
Original 8/15
Original 9/15
Original 10/15
Original 11/15
Original 12/15
Original 13/15
R
L
Navigator
LECOMTE, MARTINE, Cholestéatome ...
ID: 001104746
Default Plan Name
Object Creation
Trajectory Planning
Go To...
Next
Object
Facial Nerve, right
Inner Ear, Right
Tumor
Wall of Inner Ear, Rig...
New Object...
Remove
Auto Segmentation...
Brush Size
Contours
Outlining
Brush
Eraser
SmartBrush
SmartShaper
Auto Fill
Interpolation
SeedBrush...
Advanced Manipulation...
Screenshot saved as:
LECOMTEMARTINECholstatomegangl
iongnicul_001104746_03020947_Scr...
Undo
Redo

Set Selection

Image Sets	Images	Scan Date ▼	Comment
#4 (CT; Axial)	203	04-NOV-2016 16:56:32	SCAN SINUS; BRAINLAB; FD Sinus/FD
#3 (MR; Axial Oblique)	74	10-JUN-2016 15:47:23	IRM OREILLES +; e-THRIVE GADO; e-THRIVE GADO SENSE
#2 (MR; Coronal Oblique)	15	10-JUN-2016 15:32:07	IRM OREILLES +; DWI_TSE 2014; DWI_TSE 2014 SENSE
#1 (CT; Axial)	60	10-JUN-2016 15:09:10	SCAN OREILLES; ROCHER DROIT AXIAL; FD ROCHERS/FD

#1 (CT; Axial)
Original 31/60

R L

OK Cancel

Go To... Next

Trajectory

TLC

New Trajectory... Remove

Duplicate Parallel...

Trajectory Placement

Target Entry

Undo Redo

F F

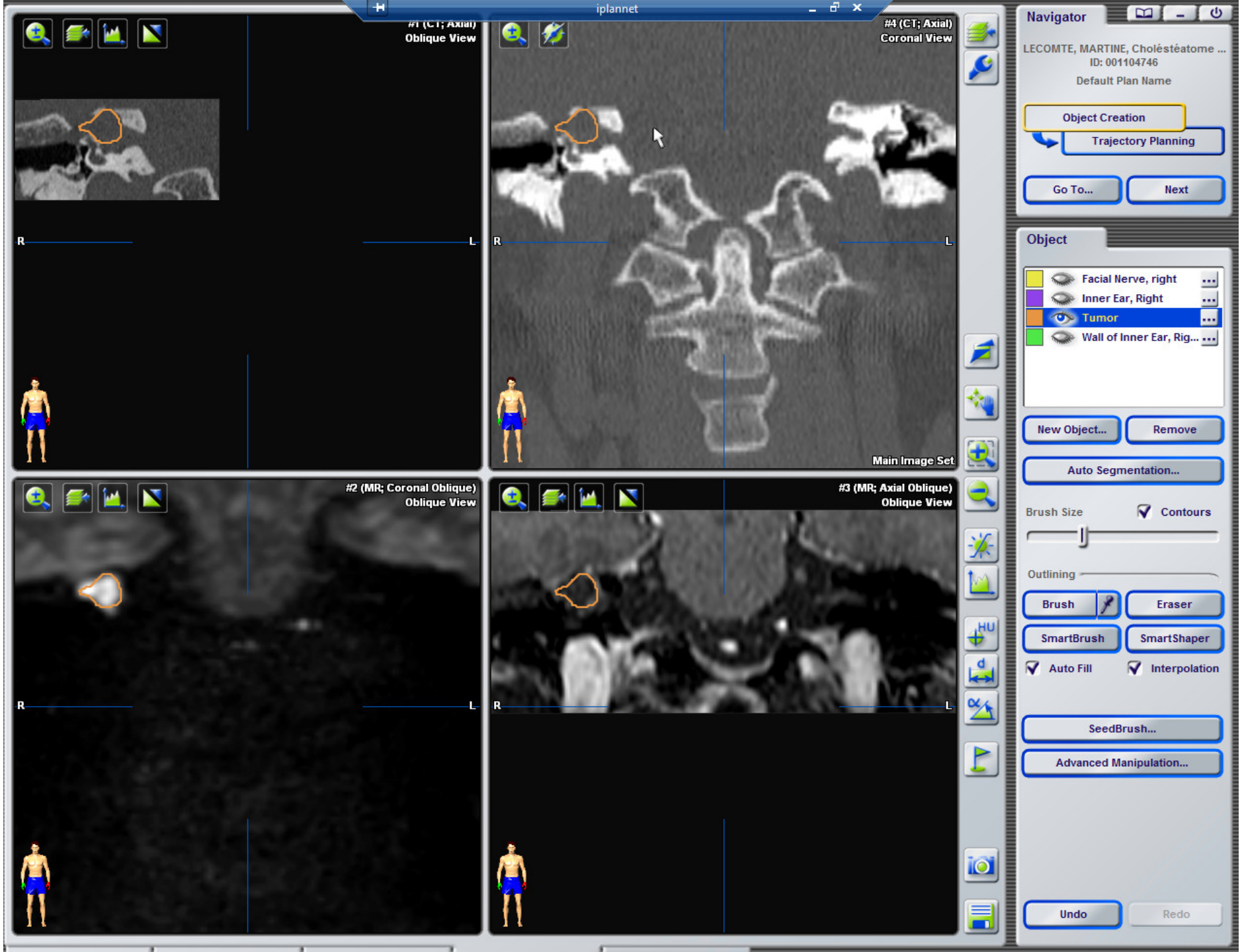
iplannet
#1 (CT; Axial)
Oblique View
#4 (CT; Axial)
Coronal View
Main Image Set
#2 (MR; Coronal Oblique)
Oblique View
#3 (MR; Axial Oblique)
Oblique View
R
L
Navigator
LECOMTE, MARTINE, Cholestéatome ...
ID: 001104746
Default Plan Name
Object Creation
Trajectory Planning
Go To...
Next
Object
Facial Nerve, right
Inner Ear, Right
Tumor
Wall of Inner Ear, Rig...
New Object...
Remove
Auto Segmentation...
Brush Size
Contours
Outlining
Brush
Eraser
SmartBrush
SmartShaper
Auto Fill
Interpolation
SeedBrush...
Advanced Manipulation...
Undo
Redo

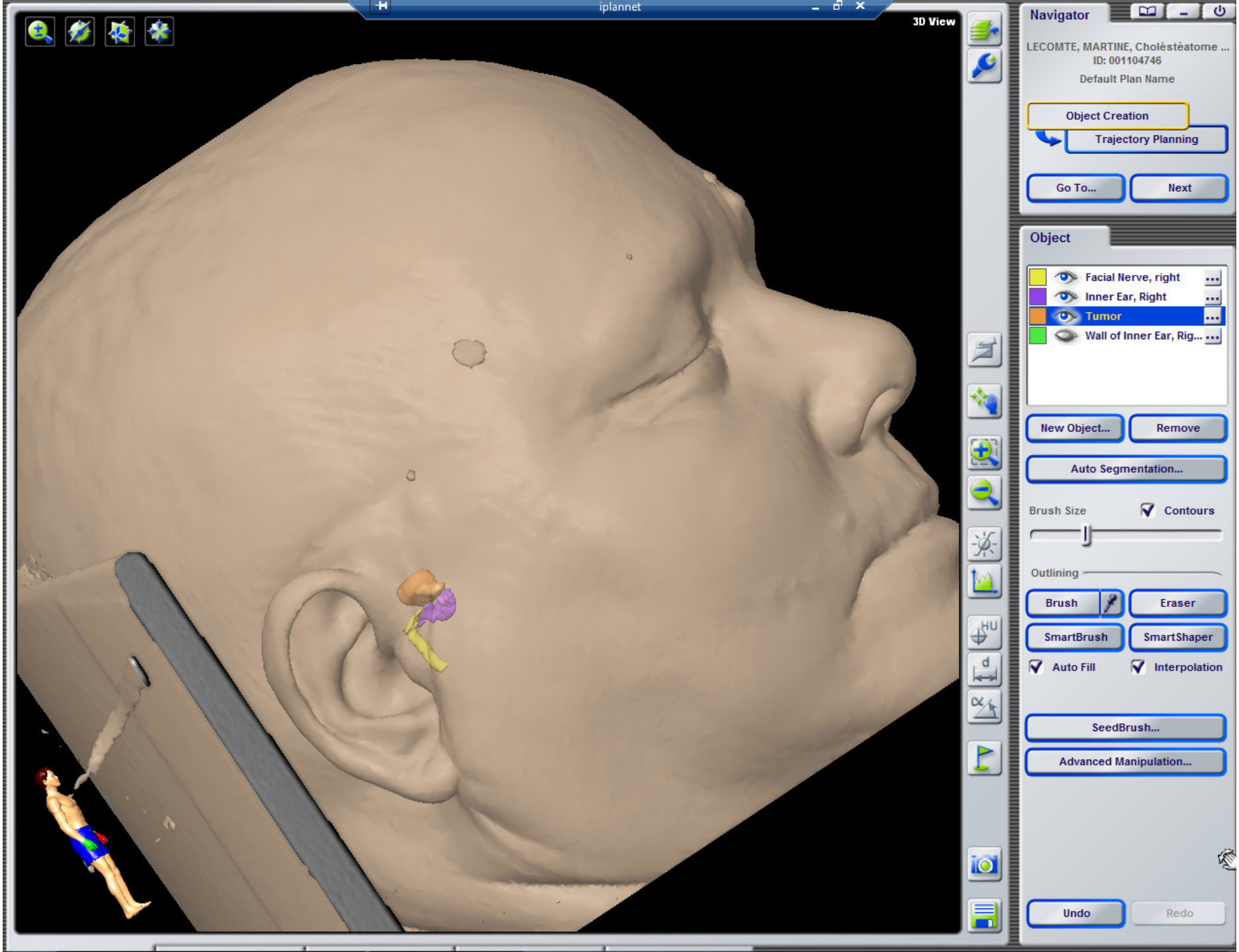
iplannet
3D View
Navigator
LECOMTE, MARTINE, Cholésteatome ...
ID: 001104746
Default Plan Name
Object Creation
Trajectory Planning
Go To...
Next
Object
Facial Nerve, right
Inner Ear, Right
Tumor
Wall of Inner Ear, Rig...
New Object...
Remove
Auto Segmentation...
Brush Size
Contours
Outlining
Brush
Eraser
SmartBrush
SmartShaper
Auto Fill
Interpolation
SeedBrush...
Advanced Manipulation...
Undo
Redo

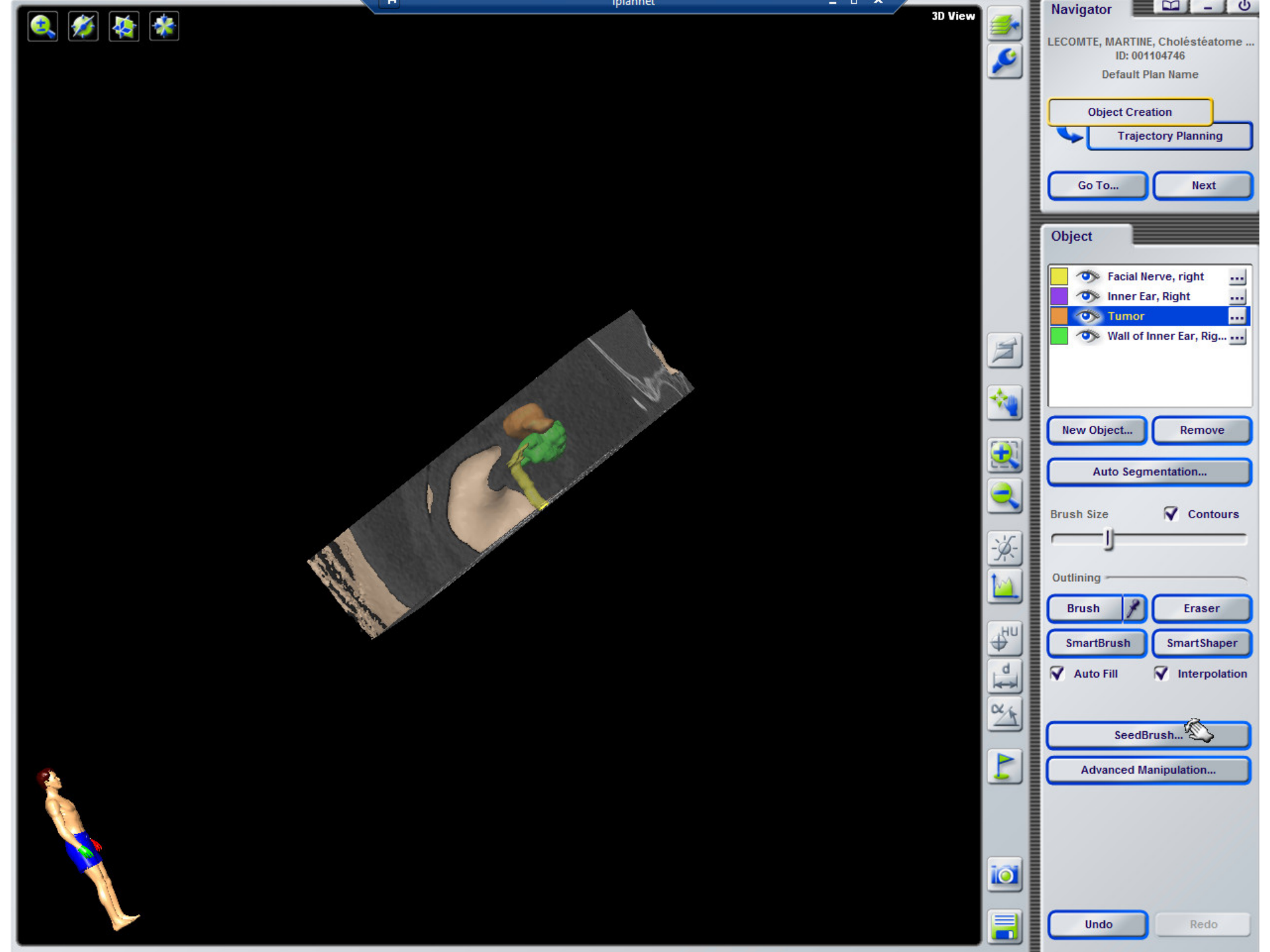
iplanner
3D View
Navigator
LECOMTE, MARTINE, Cholésteatome ...
ID: 001104746
Default Plan Name
Object Creation
Trajectory Planning
Go To...
Next
Object
Facial Nerve, right
Inner Ear, Right
Tumor
Wall of Inner Ear, Rig...
New Object...
Remove
Auto Segmentation...
Brush Size
Contours
Outlining
Brush
Eraser
SmartBrush
SmartShaper
Auto Fill
Interpolation
SeedBrush...
Advanced Manipulation...
Undo
Redo

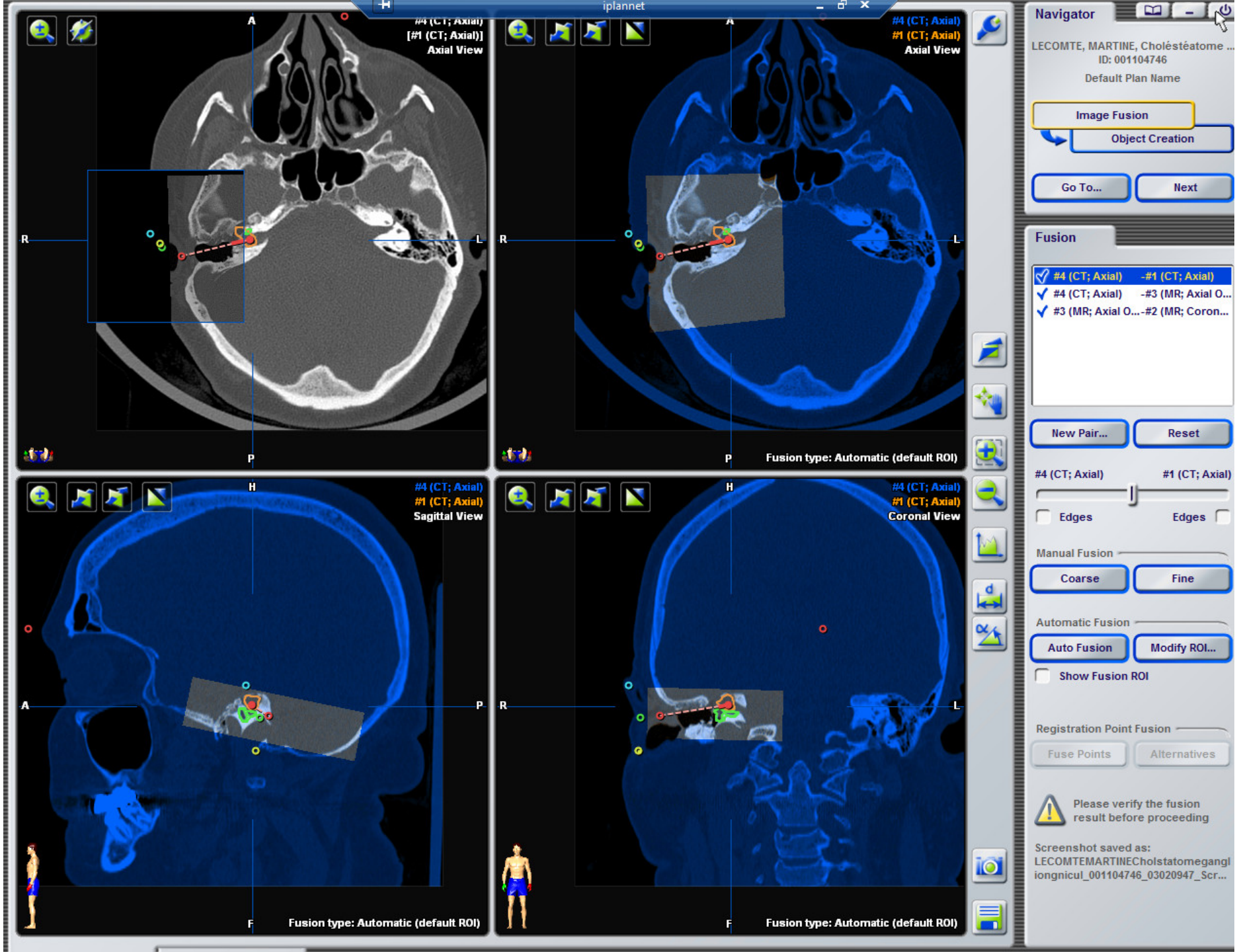
iplannet
#4 (CT; Axial)
[#1 (CT; Axial)]
Axial View
#4 (CT; Axial)
#1 (CT; Axial)
Axial View
Fusion type: Automatic (default ROI)
#4 (CT; Axial)
#1 (CT; Axial)
Sagittal View
Fusion type: Automatic (default ROI)
#4 (CT; Axial)
#1 (CT; Axial)
Coronal View
Fusion type: Automatic (default ROI)
Navigator
LECOMTE, MARTINE, Cholestéatome ...
ID: 001104746
Default Plan Name
Image Fusion
Object Creation
Go To...
Next
Fusion
#4 (CT; Axial) -#1 (CT; Axial)
#4 (CT; Axial) -#3 (MR; Axial O...
#3 (MR; Axial O...-#2 (MR; Coron...
New Pair...
Reset
#4 (CT; Axial)
#1 (CT; Axial)
Edges
Edges
Manual Fusion
Coarse
Fine
Automatic Fusion
Auto Fusion
Modify ROI...
Show Fusion ROI
Registration Point Fusion
Fuse Points
Alternatives
Please verify the fusion result before proceeding
Screenshot saved as:
LECOMTEMARTINECholstatomegangliongnicul_001104746_03020947_Scr...

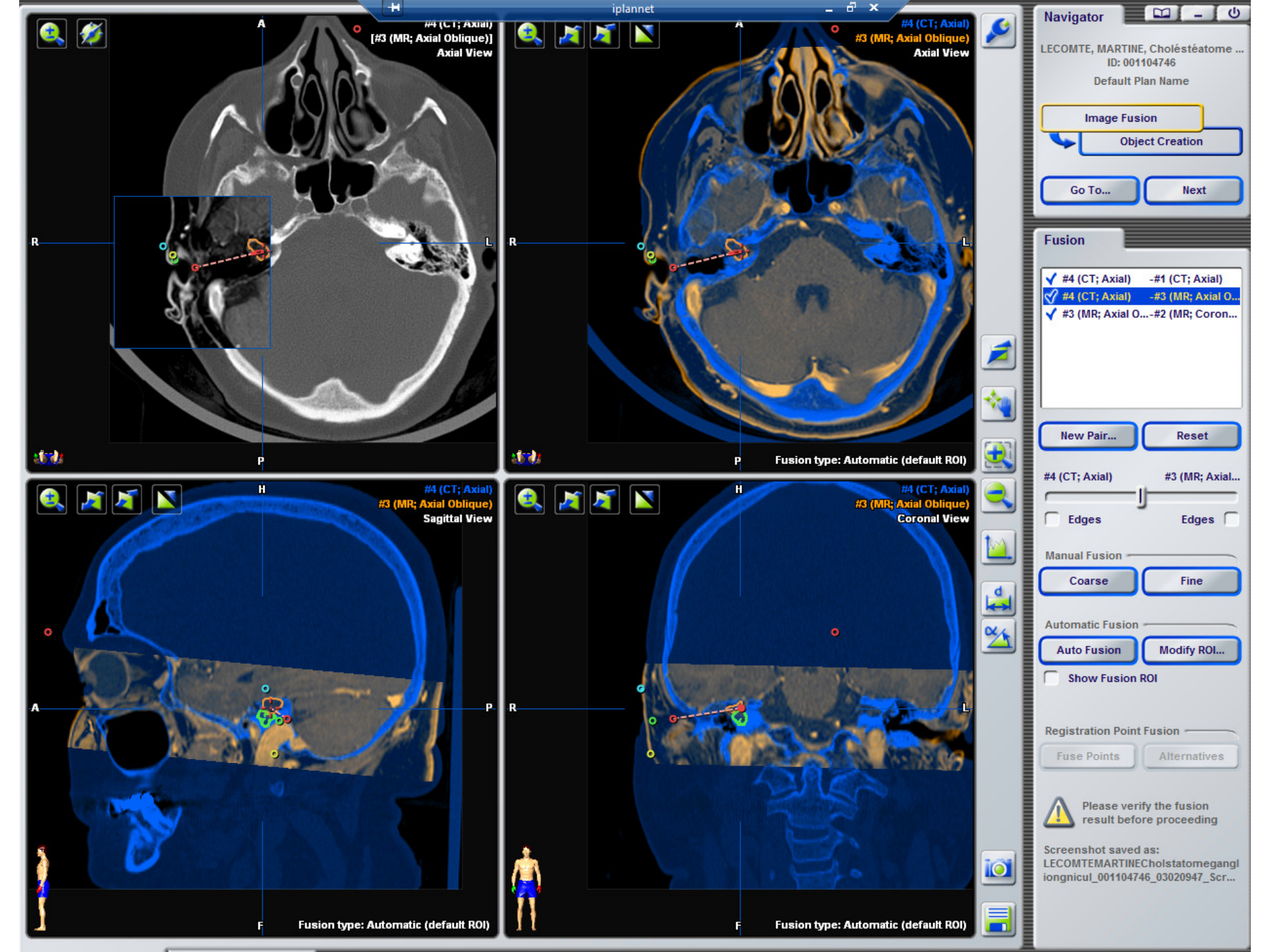
iplannet
#4 (CT; Axial)
[#3 (MR; Axial Oblique)]
Axial View
#4 (CT; Axial)
#3 (MR; Axial Oblique)
Axial View
Fusion type: Automatic (default ROI)
#4 (CT; Axial)
#3 (MR; Axial Oblique)
Sagittal View
Fusion type: Automatic (default ROI)
#4 (CT; Axial)
#3 (MR; Axial Oblique)
Coronal View
Fusion type: Automatic (default ROI)
Navigator
LECOMTE, MARTINE, Cholésteatome ...
ID: 001104746
Default Plan Name
Image Fusion
Object Creation
Go To...
Next
Fusion
#4 (CT; Axial) -#1 (CT; Axial)
#4 (CT; Axial) -#3 (MR; Axial O...
#3 (MR; Axial O...-#2 (MR; Coron...
New Pair...
Reset
#4 (CT; Axial)
#3 (MR; Axial...
Edges
Edges
Manual Fusion
Coarse
Fine
Automatic Fusion
Auto Fusion
Modify ROI...
Show Fusion ROI
Registration Point Fusion
Fuse Points
Alternatives
Please verify the fusion result before proceeding
Screenshot saved as:
LECOMTEMARTINECholstatomegangl
iongnicul_001104746_03020947_Scr...

iplannet

- Patient: LECOMTE, MARTINE, Choléstéatome ganglion g...
  - Treatment Plan: Default Plan Name
    - Image Sets
      - #1 (CT; Axial)
      - #2 (MR; Coronal Oblique)
      - #3 (MR; Axial Oblique)
      - #4 (CT; Axial)
    - Objects
      - Facial Nerve, right
      - Inner Ear, Right
      - Tumor
      - Wall of Inner Ear, Right
    - Registration Points
      - interhelicotragien (01)
      - base tragus (02)
      - HelixRoot (03)
      - Cutaneous nodule (04)
    - Trajectories
      - TLC

Properties

Name:	Default Plan Name
Creation Date:	08-NOV-2016
Version:	3
Application:	iPlan Cranial 3.0.6 RELEASE
Saved by:	nicolas.bonne
Saved at:	09-NOV-2016 18:06:37
State:	Planning in progress
Directory:	f:\patientdata\xbrain\otoneuro\lecomte_martine__chol_058217f5e\st...
Description:	

Paragangliomes multiples
Mutation SDHD

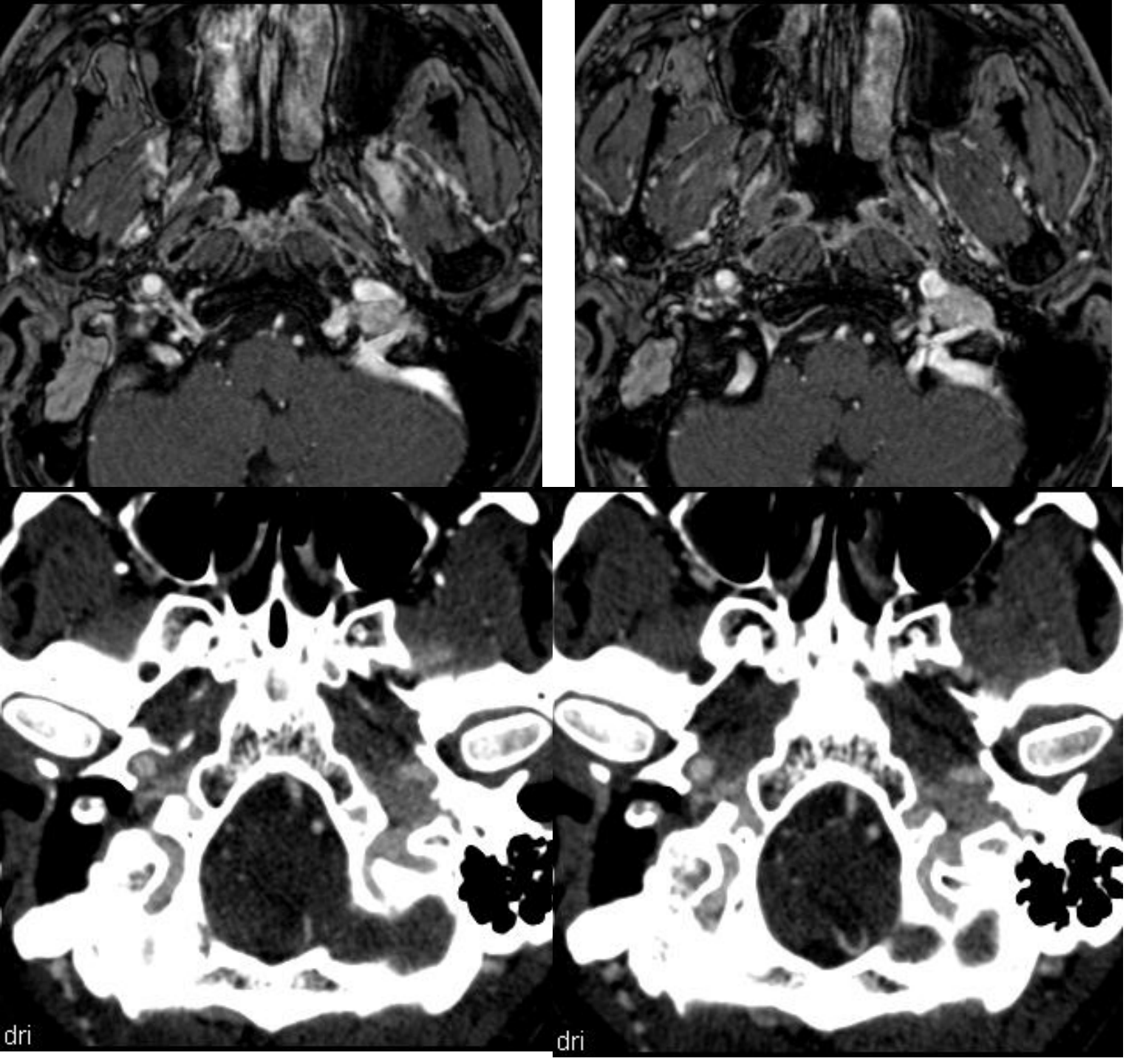
dri
dri

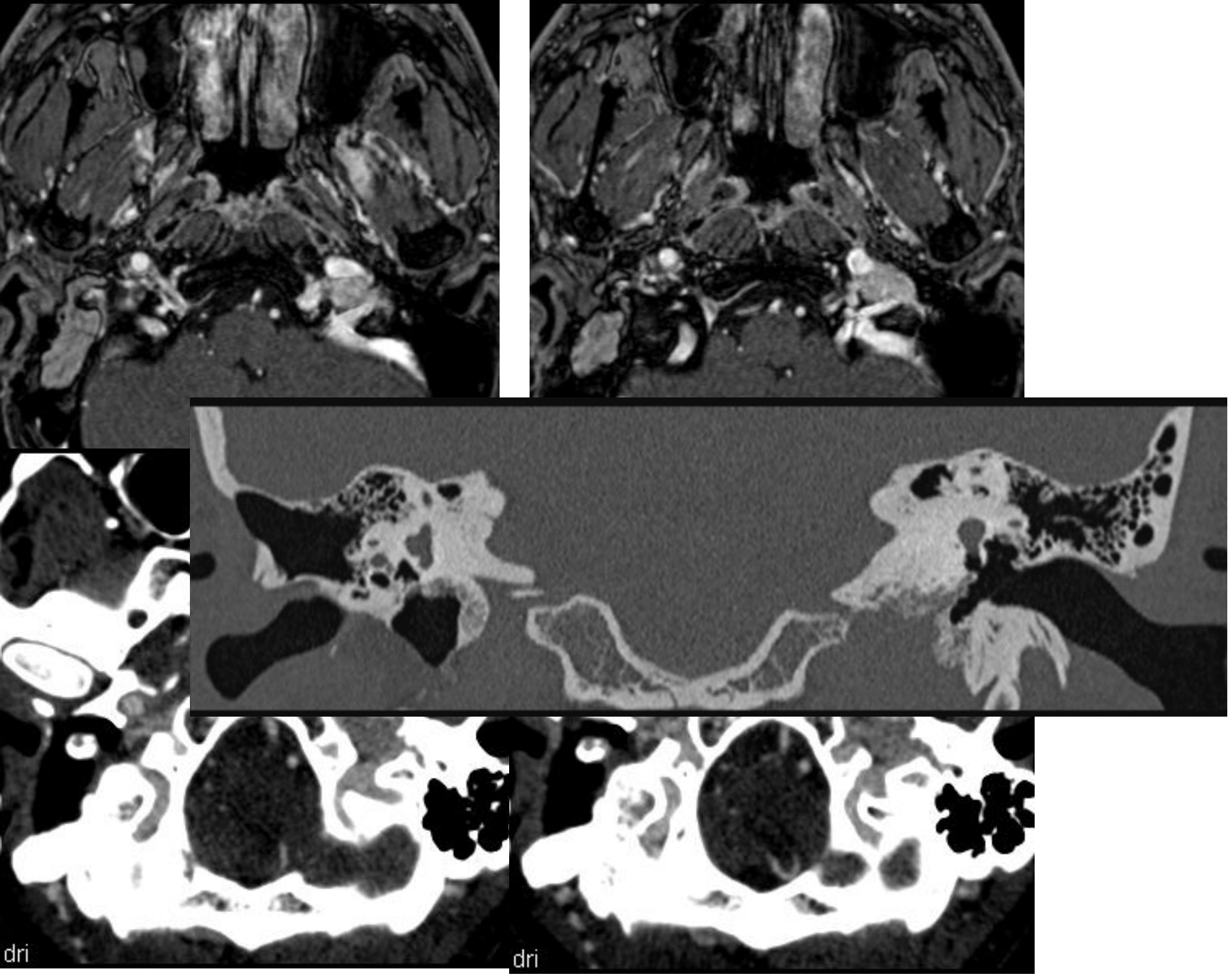
dri
dri

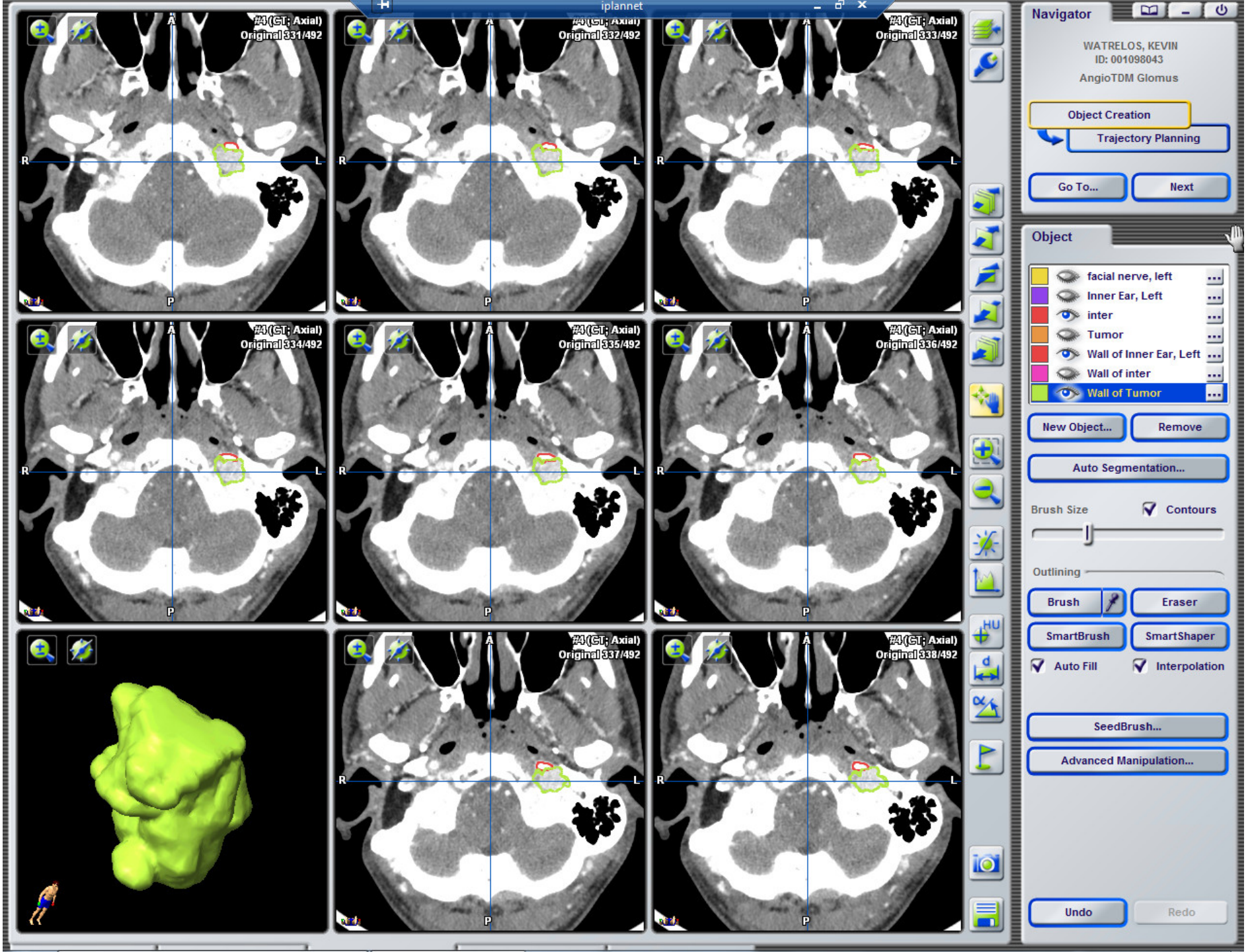
iplannet
#4 (CT; Axial)
Original 331/492
Original 332/492
Original 333/492
Original 334/492
Original 335/492
Original 336/492
Original 337/492
Original 338/492
A
P
R
L
Navigator
WATRELOS, KEVIN
ID: 001098043
AngioTDM Glomus
Object Creation
Trajectory Planning
Go To...
Next
Object
facial nerve, left
Inner Ear, Left
inter
Tumor
Wall of Inner Ear, Left
Wall of inter
Wall of Tumor
New Object...
Remove
Auto Segmentation...
Brush Size
Contours
Outlining
Brush
Eraser
SmartBrush
SmartShaper
Auto Fill
Interpolation
SeedBrush...
Advanced Manipulation...
Undo
Redo

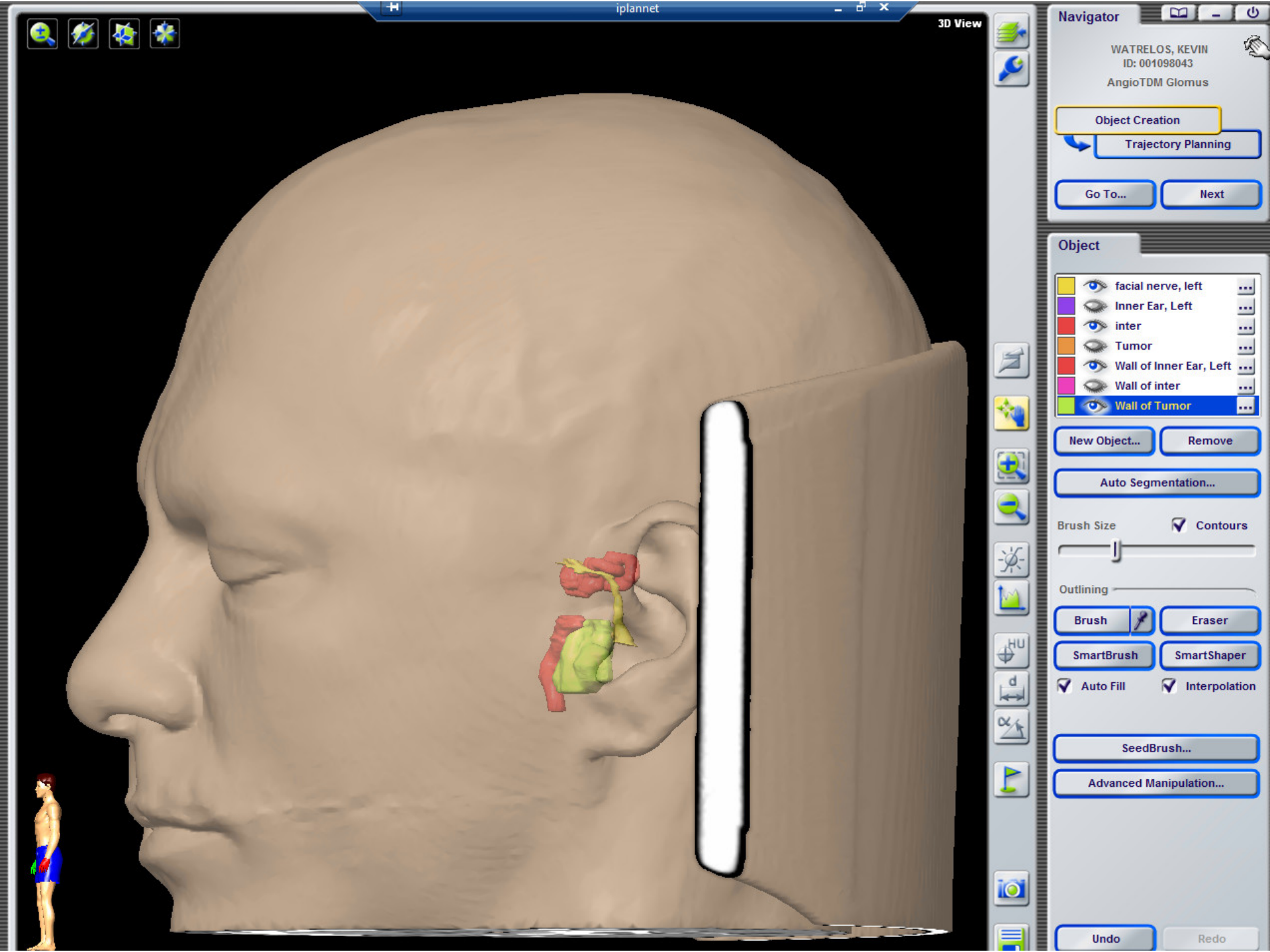
iplannet
3D View
Navigator
WATRELOS, KEVIN
ID: 001098043
AngioTDM Glomus
Object Creation
Trajectory Planning
Go To...
Next
Object
facial nerve, left
Inner Ear, Left
inter
Tumor
Wall of Inner Ear, Left
Wall of inter
Wall of Tumor
New Object...
Remove
Auto Segmentation...
Brush Size
Contours
Outlining
Brush
Eraser
SmartBrush
SmartShaper
Auto Fill
Interpolation
SeedBrush...
Advanced Manipulation...
Undo
Redo

en bleu axe microscope et point focal

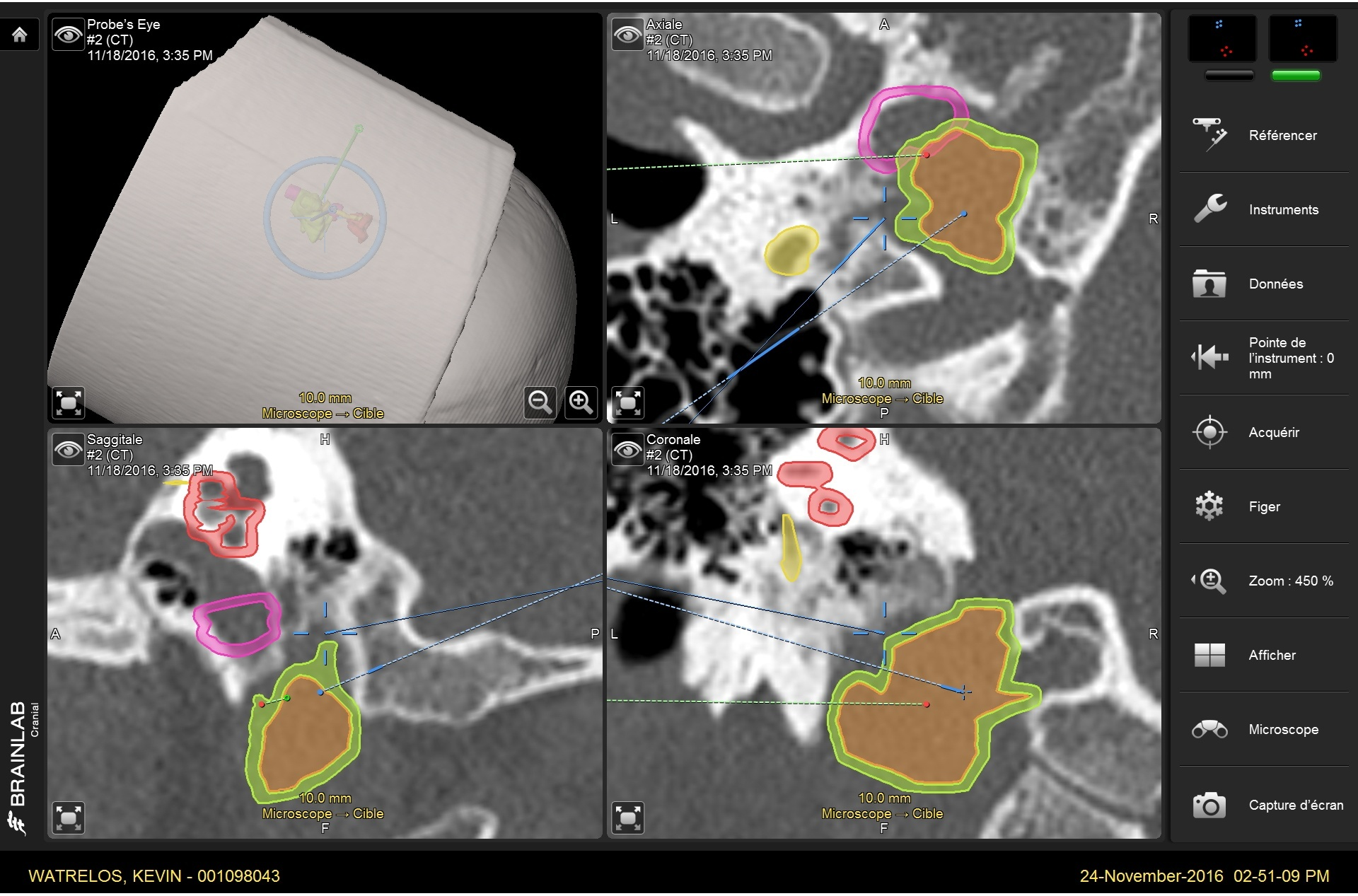

Vue peropératoire avec représentation schématique des zones projetées

Vue peropératoire en réalité augmentée

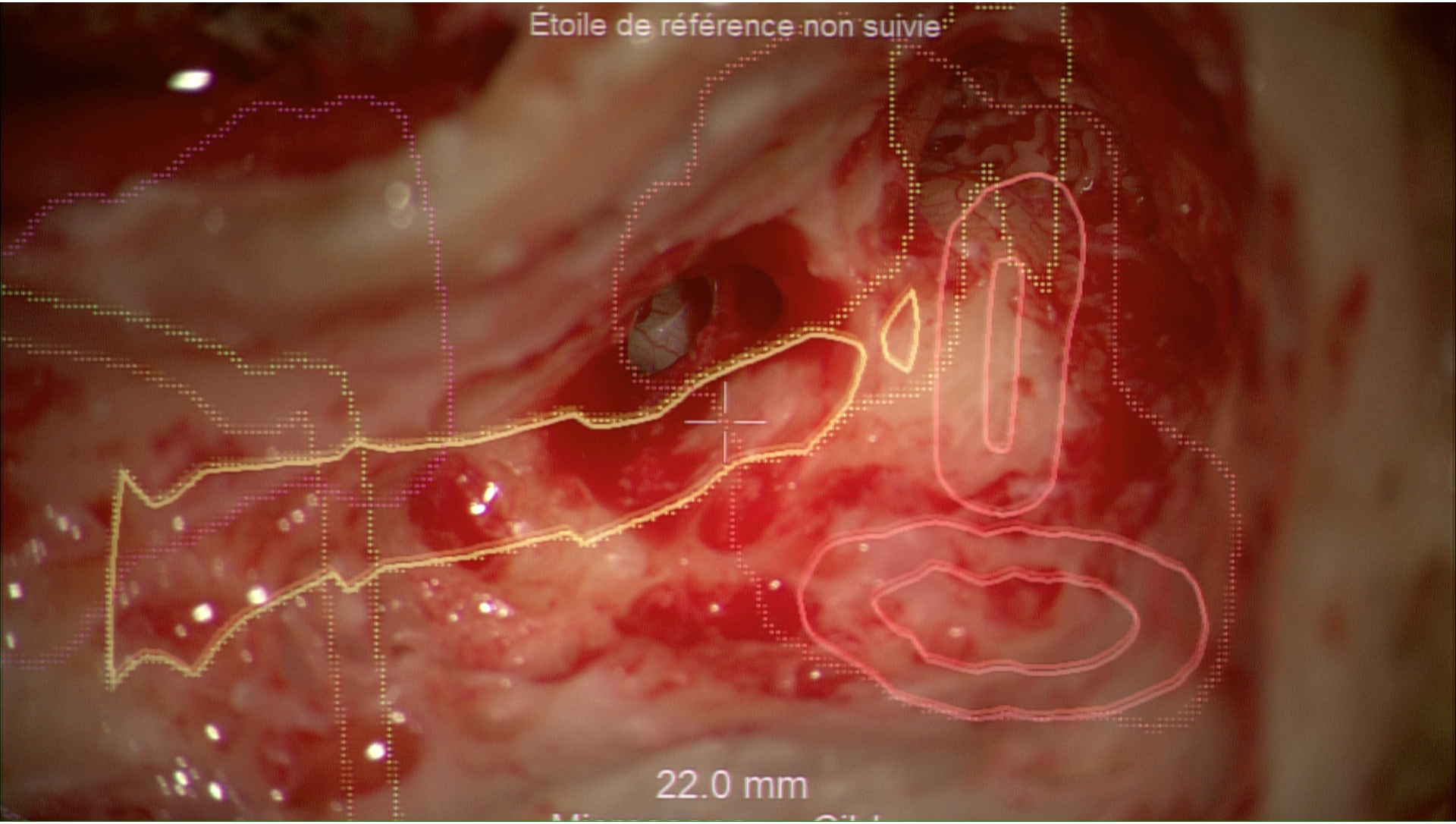

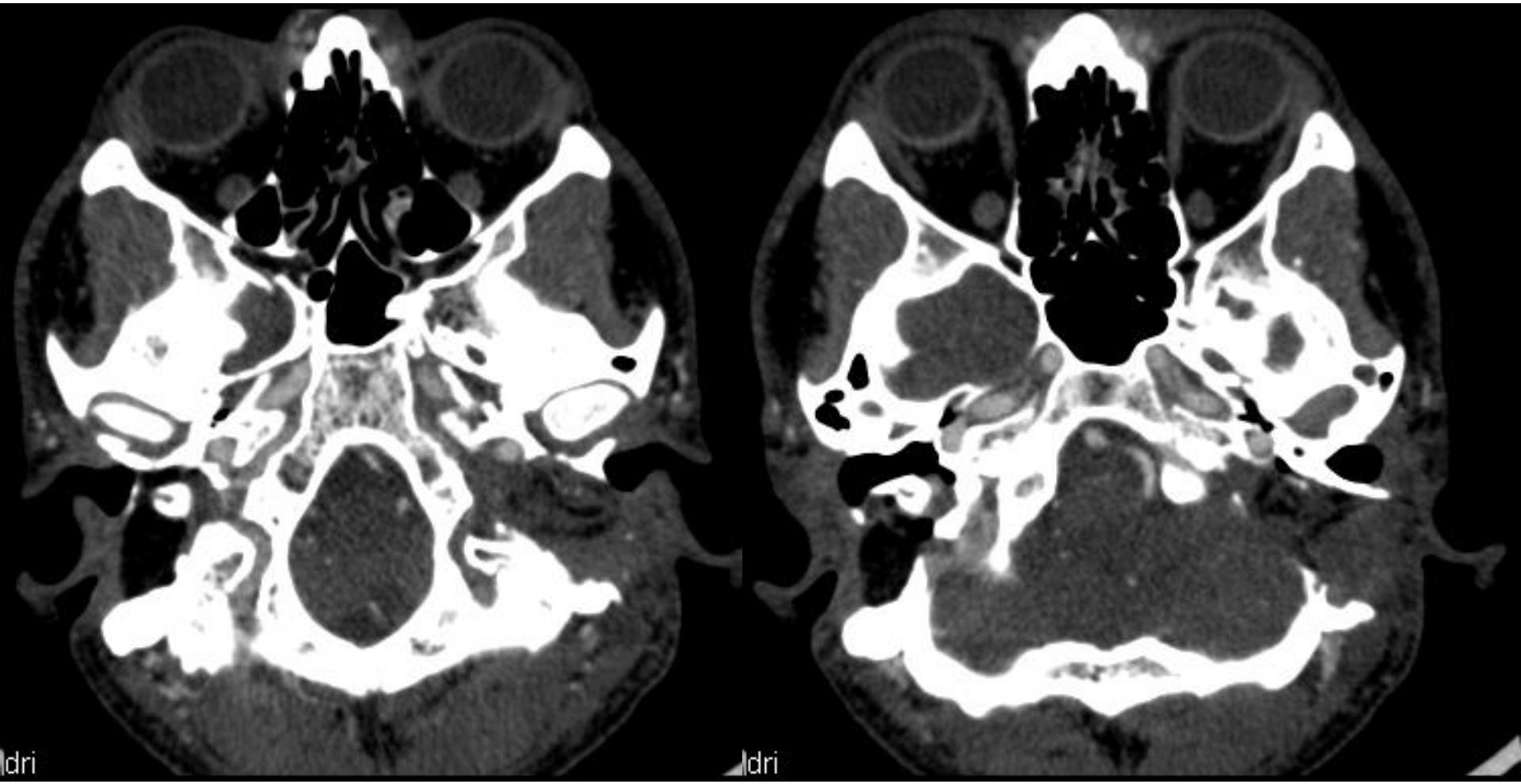
dri
dri

Patiente granulome à cholesterine de l’apex pétreux

Récidive

biloculé

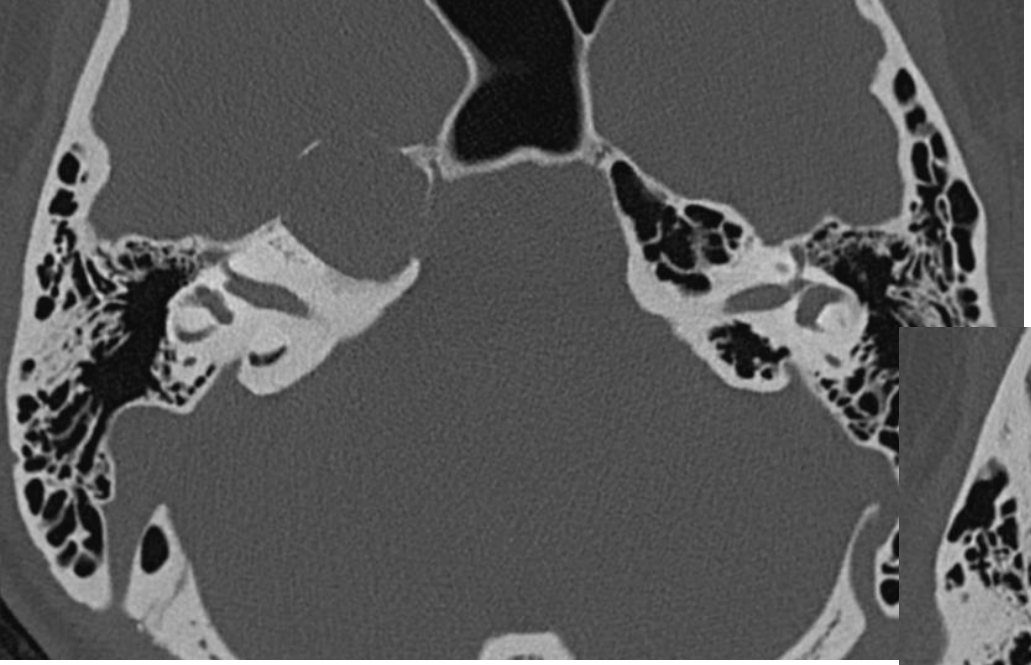

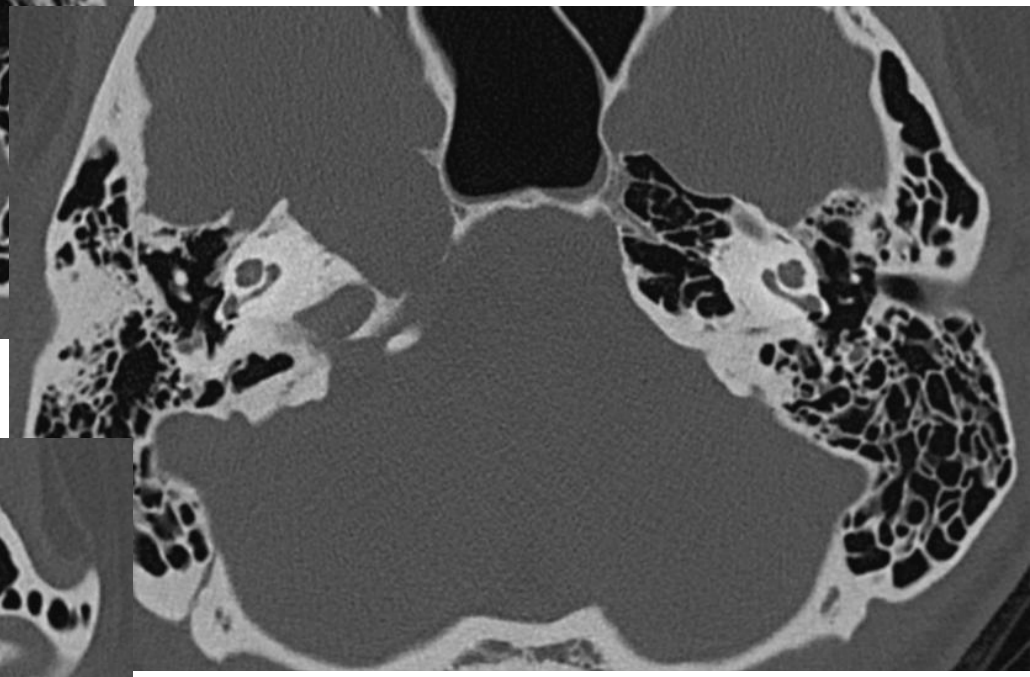

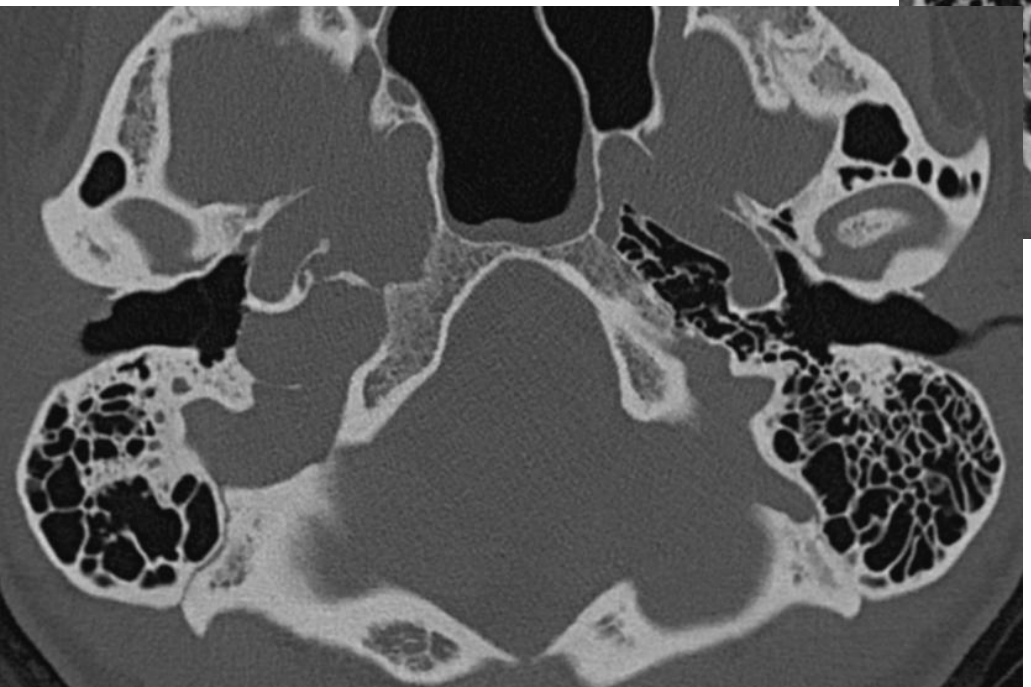

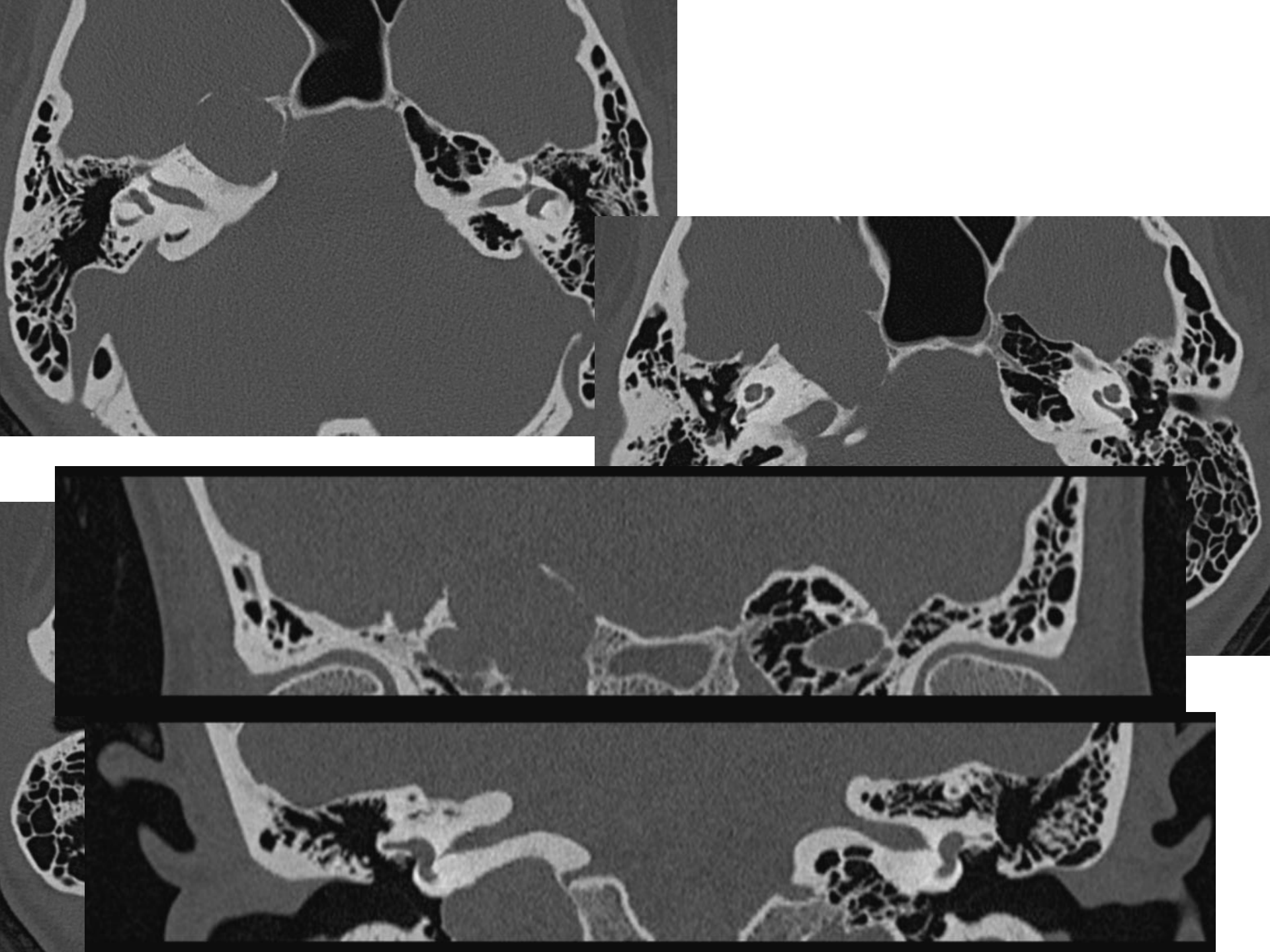

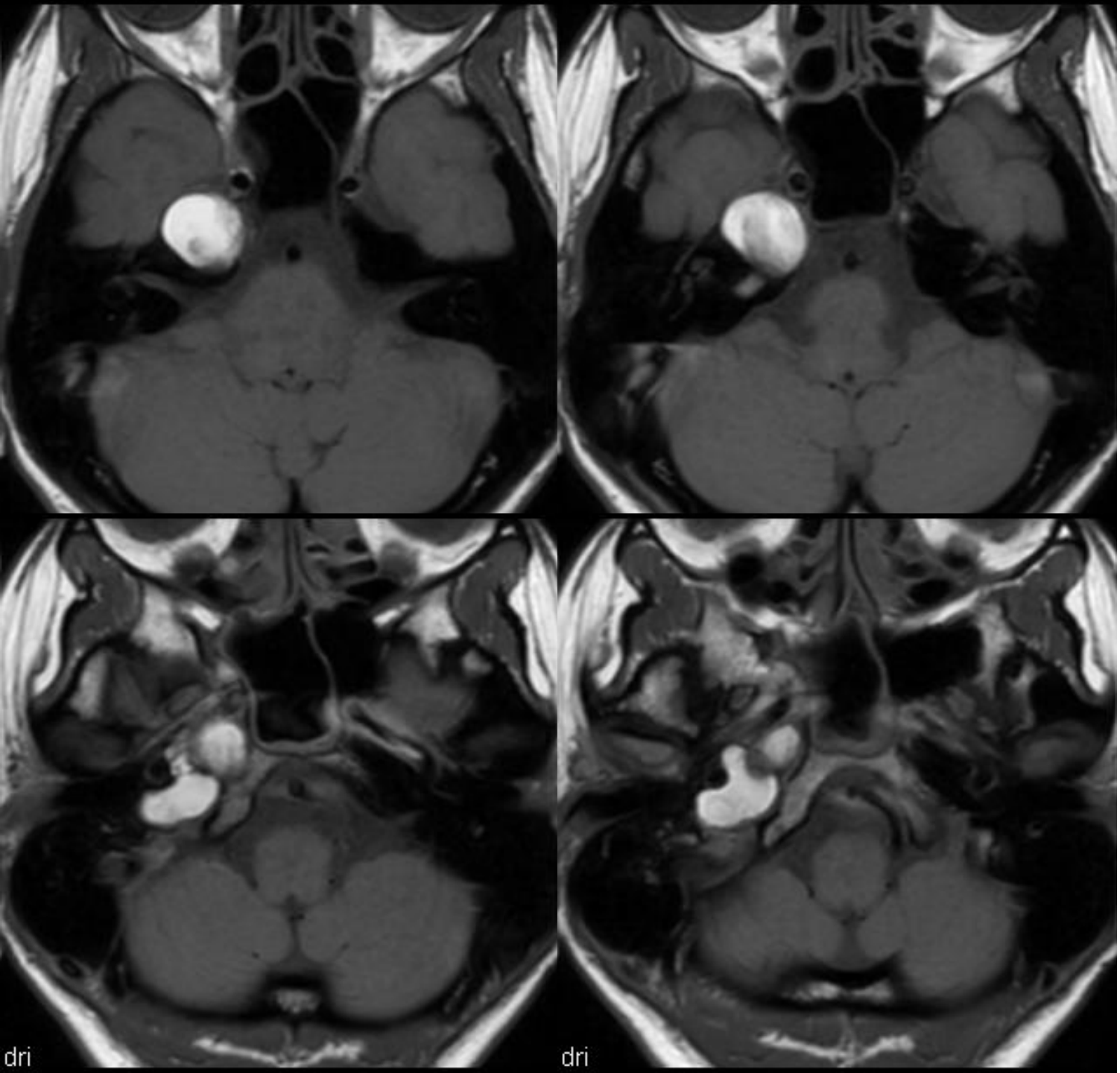

IRM
Série T1
sans inj

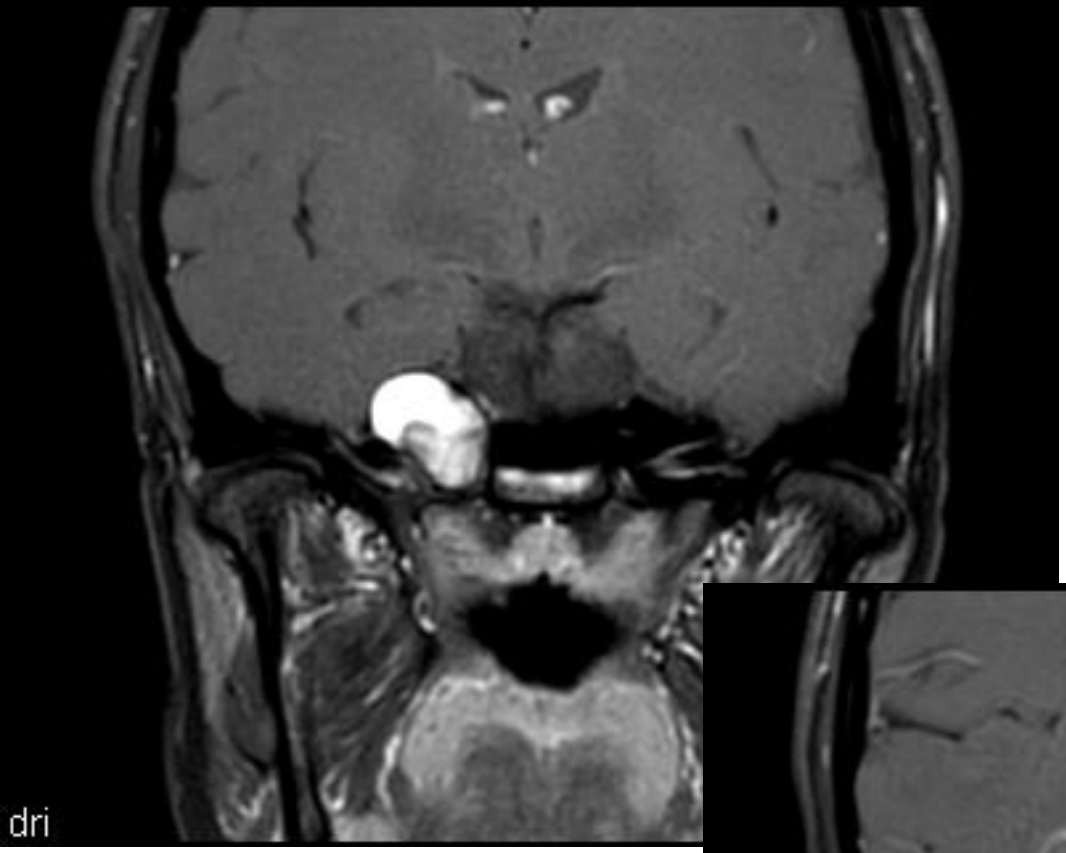

IRM
Série T1 sans inj

IRM
Série angio TOF gado

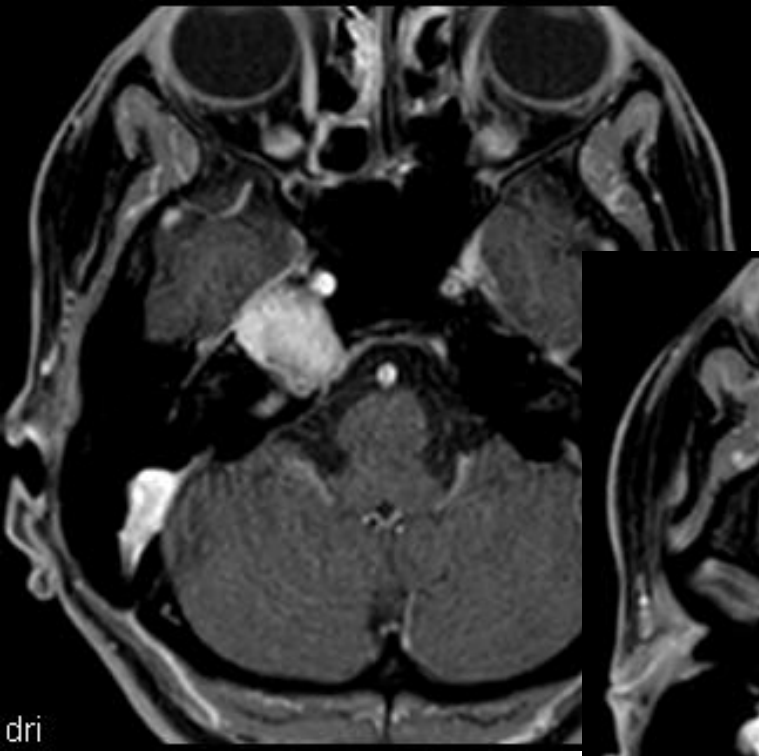

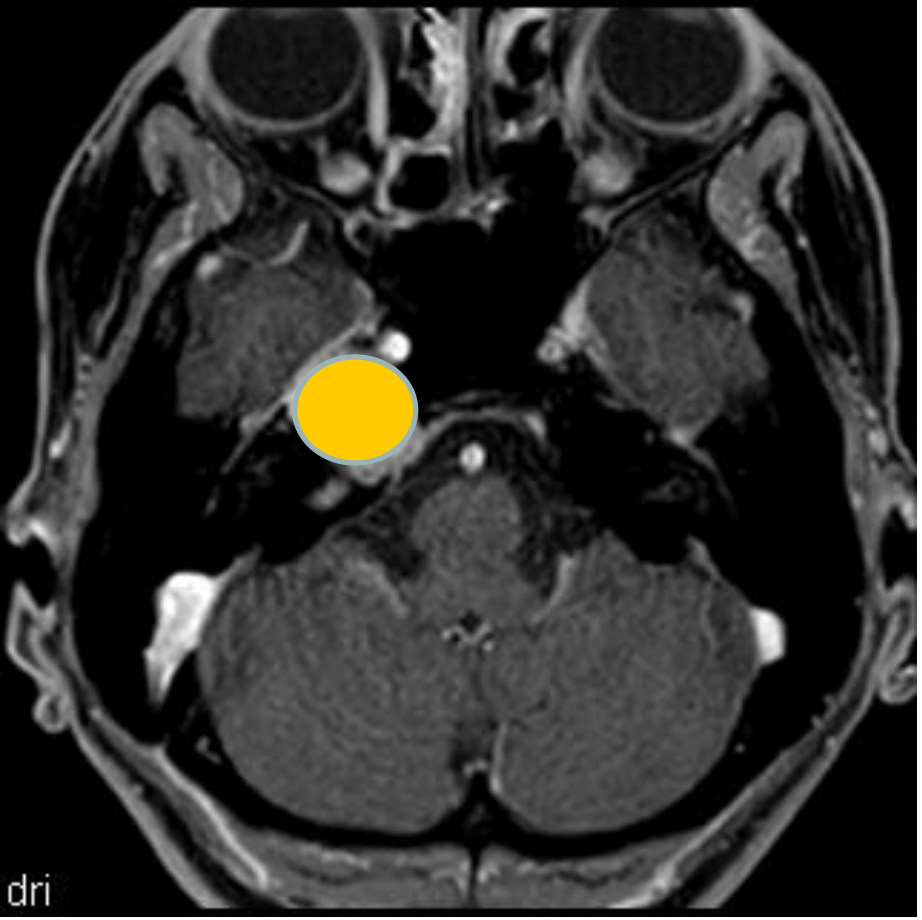
dri

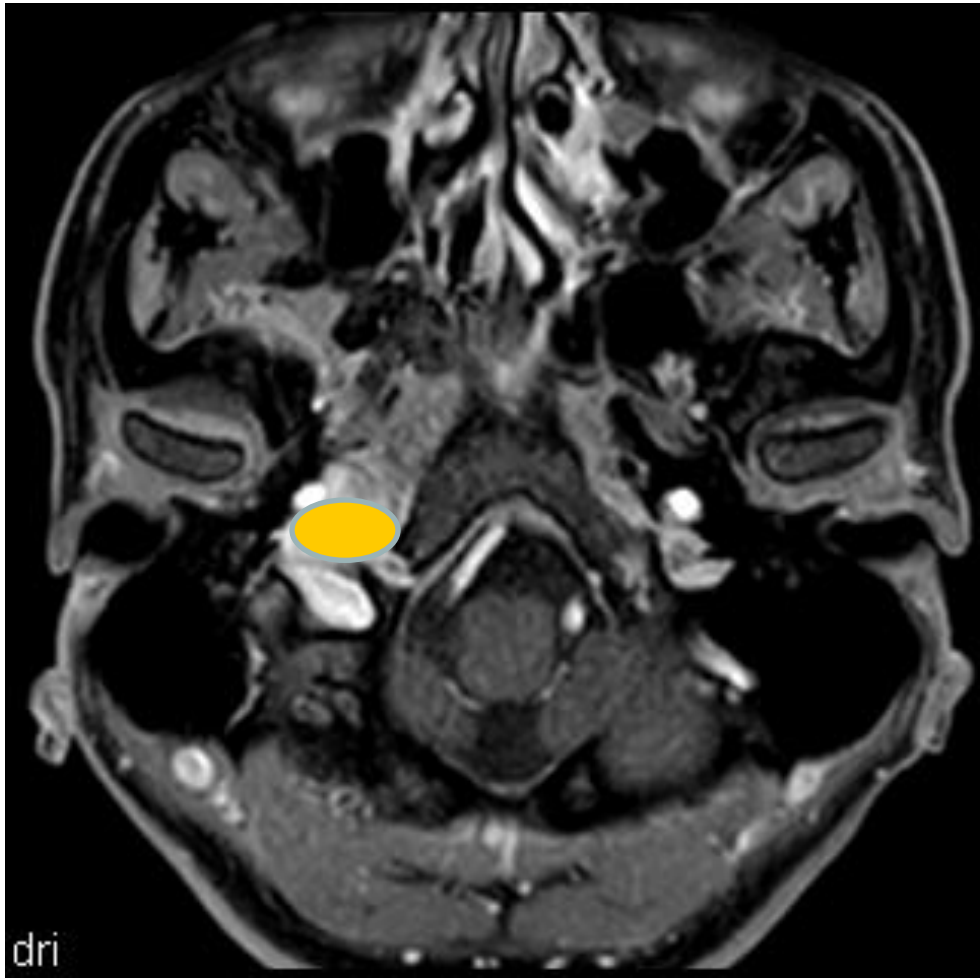
dri

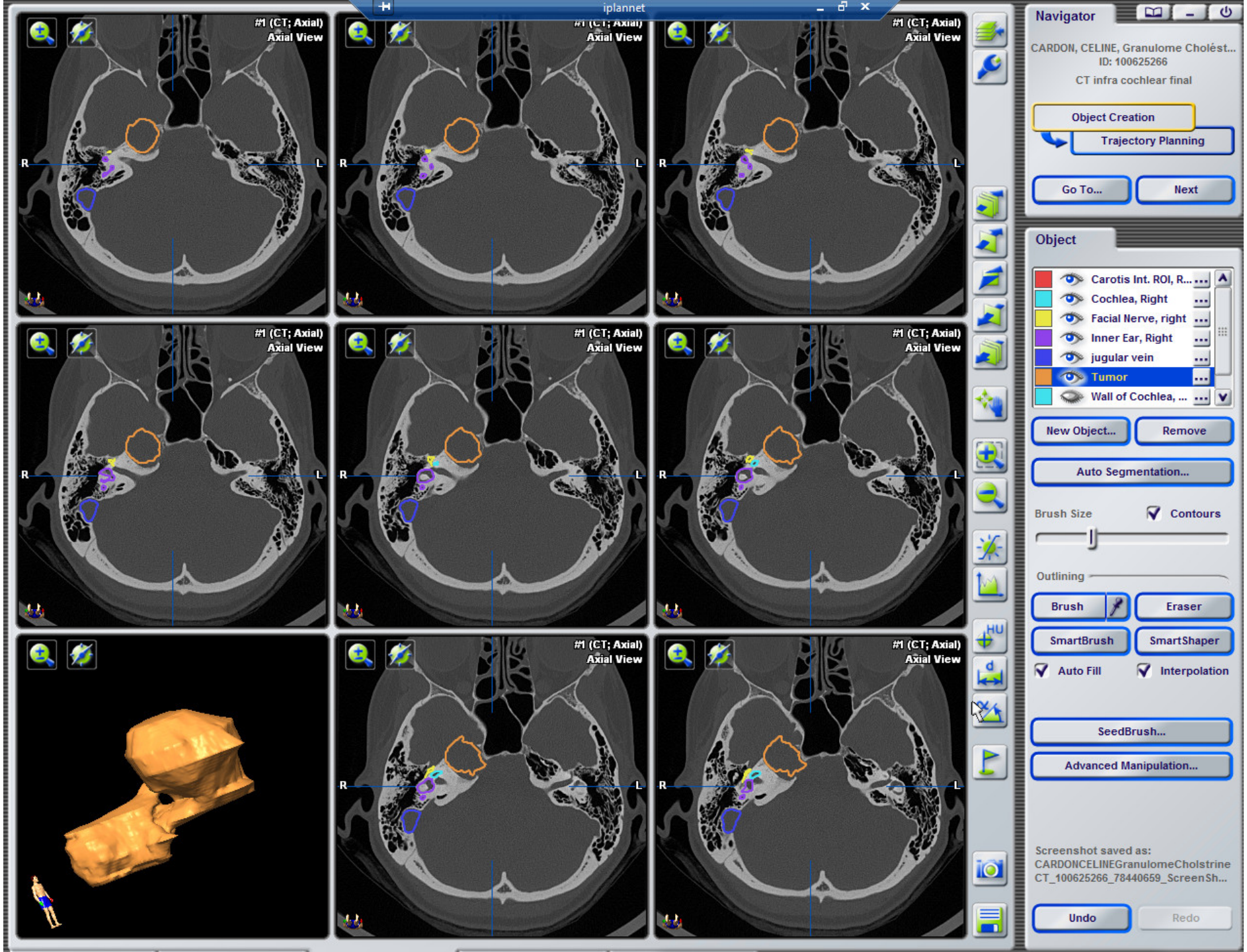
iplannet
#1 (CT; Axial)
Axial View
R
L
Navigator
CARDON, CELINE, Granulome Cholést...
ID: 100625266
CT infra cochlear final
Object Creation
Trajectory Planning
Go To...
Next
Object
Carotis Int. ROI, R...
Cochlea, Right
Facial Nerve, right
Inner Ear, Right
jugular vein
Tumor
Wall of Cochlea, ...
New Object...
Remove
Auto Segmentation...
Brush Size
Contours
Outlining
Brush
Eraser
SmartBrush
SmartShaper
Auto Fill
Interpolation
SeedBrush...
Advanced Manipulation...
Screenshot saved as:
CARDONCELINEGranulomeCholstrine
CT_100625266_78440659_ScreenSh...
Undo
Redo

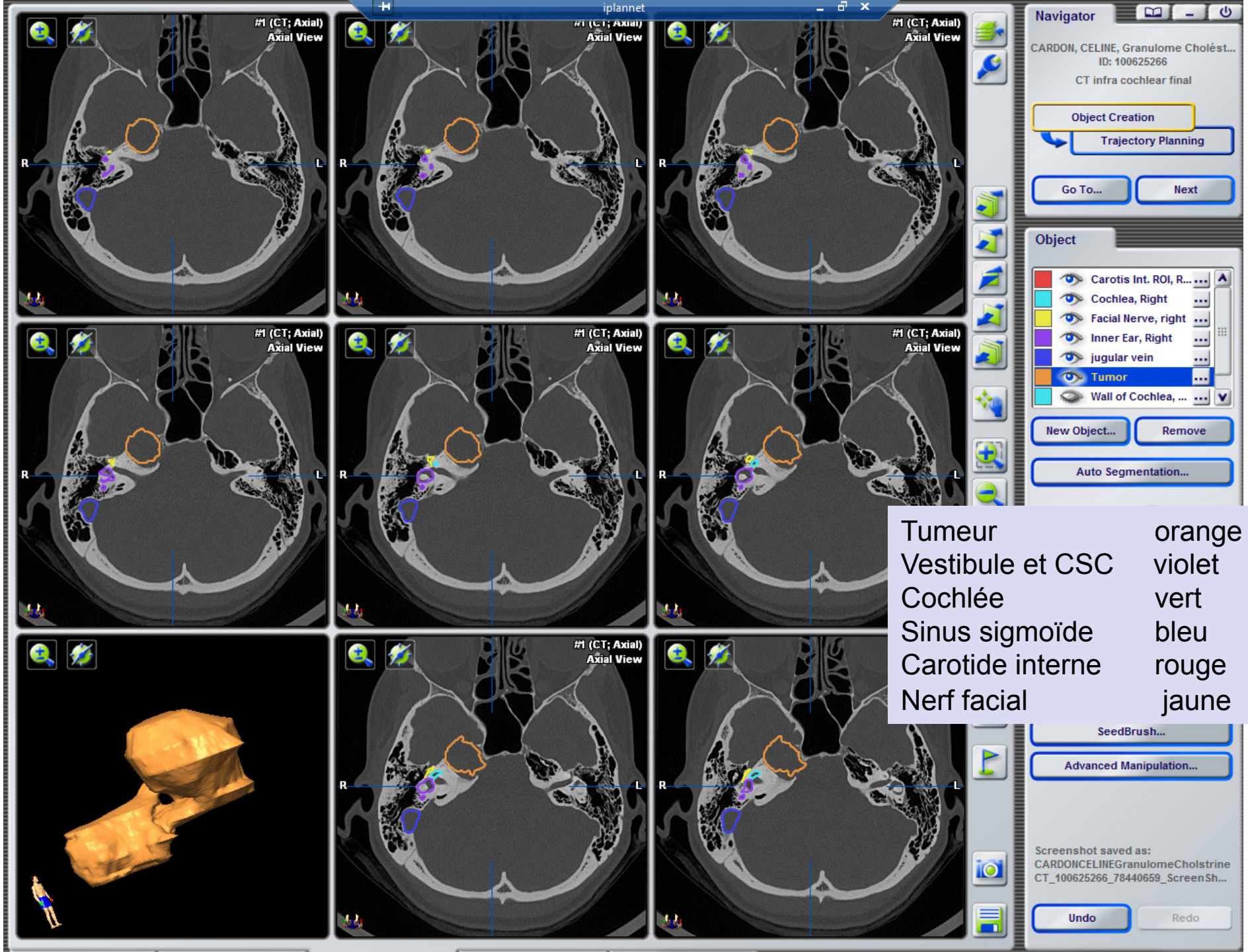

Tumeur	orange
Vestibule et CSC	violet
Cochlée	vert
Sinus sigmoïde	bleu
Carotide interne	rouge
Nerf facial	jaune

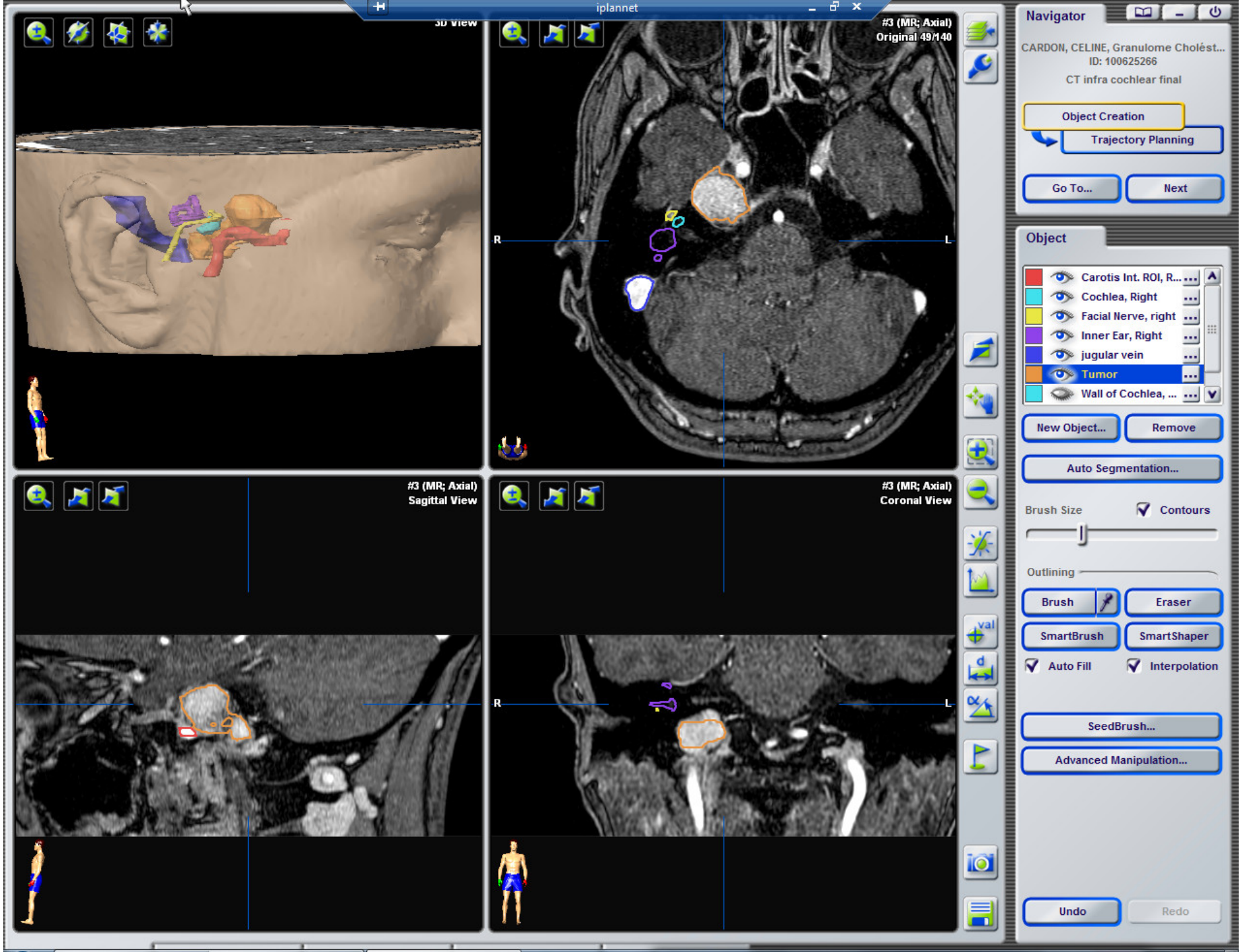
iplannet
3D View
#3 (MR; Axial)
Original 49/140
R
L
#3 (MR; Axial)
Sagittal View
#3 (MR; Axial)
Coronal View
R
L
Navigator
CARDON, CELINE, Granulome Cholést...
ID: 100625266
CT infra cochlear final
Object Creation
Trajectory Planning
Go To...
Next
Object
Carotis Int. ROI, R...
Cochlea, Right
Facial Nerve, right
Inner Ear, Right
jugular vein
Tumor
Wall of Cochlea, ...
New Object...
Remove
Auto Segmentation...
Brush Size
Contours
Outlining
Brush
Eraser
SmartBrush
SmartShaper
Auto Fill
Interpolation
SeedBrush...
Advanced Manipulation...
Undo
Redo

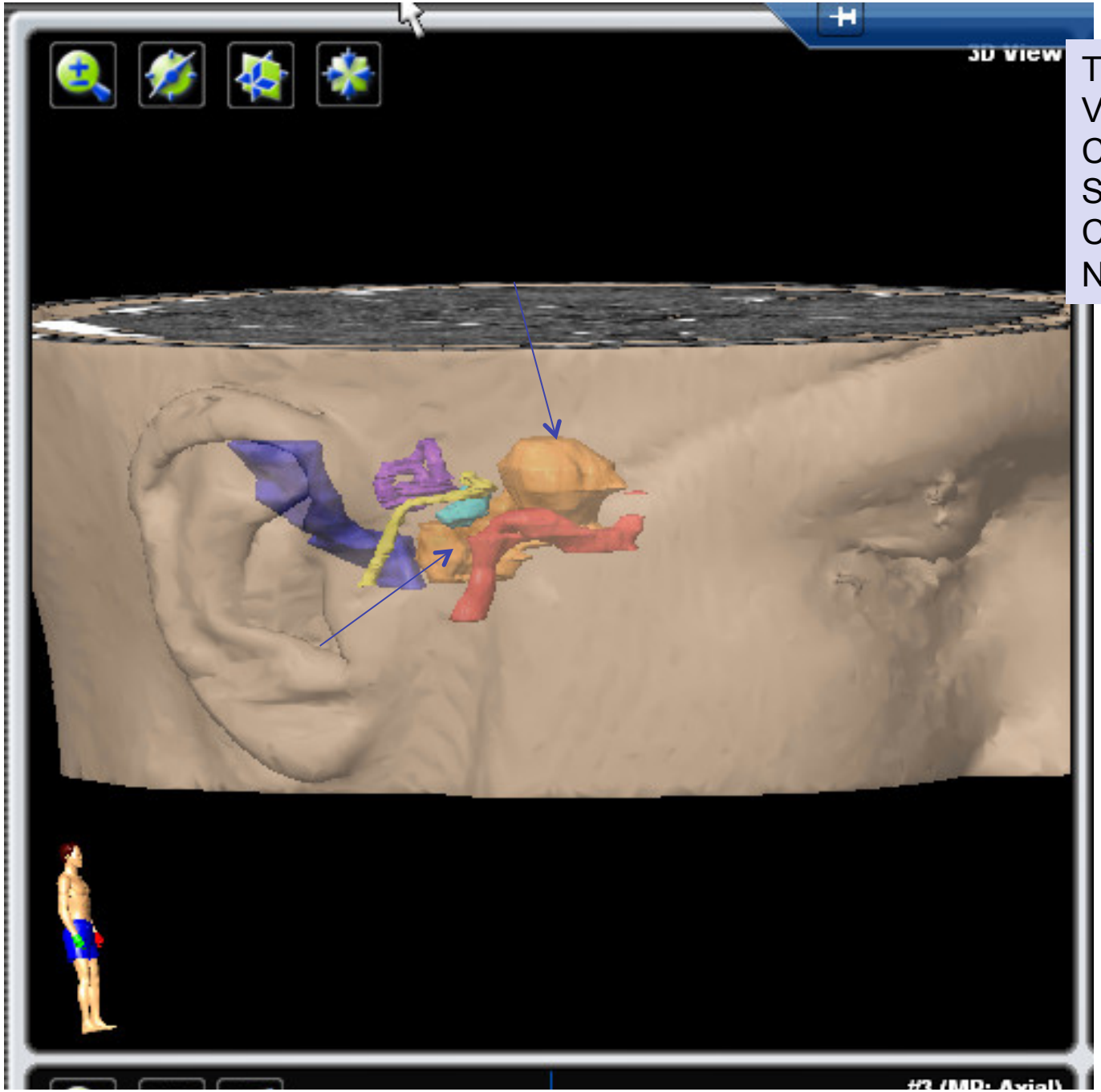

Tumeur	orange
Vestibule et CSC	violet
Cochlée	vert
Sinus sigmoïde	bleu
Carotide interne	rouge
Nerf facial	jaune

Sus pétreuse

Et infracochléaire

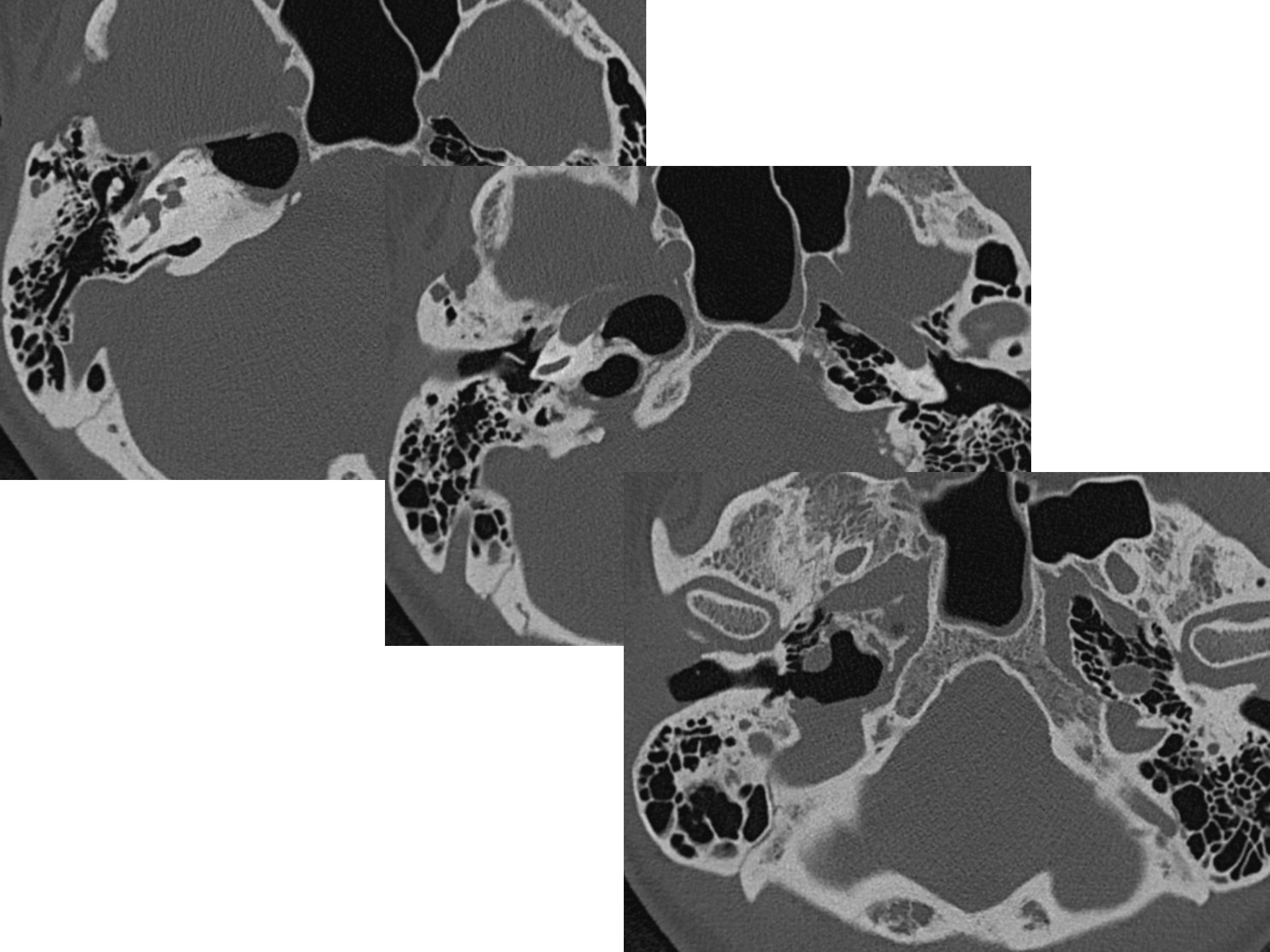

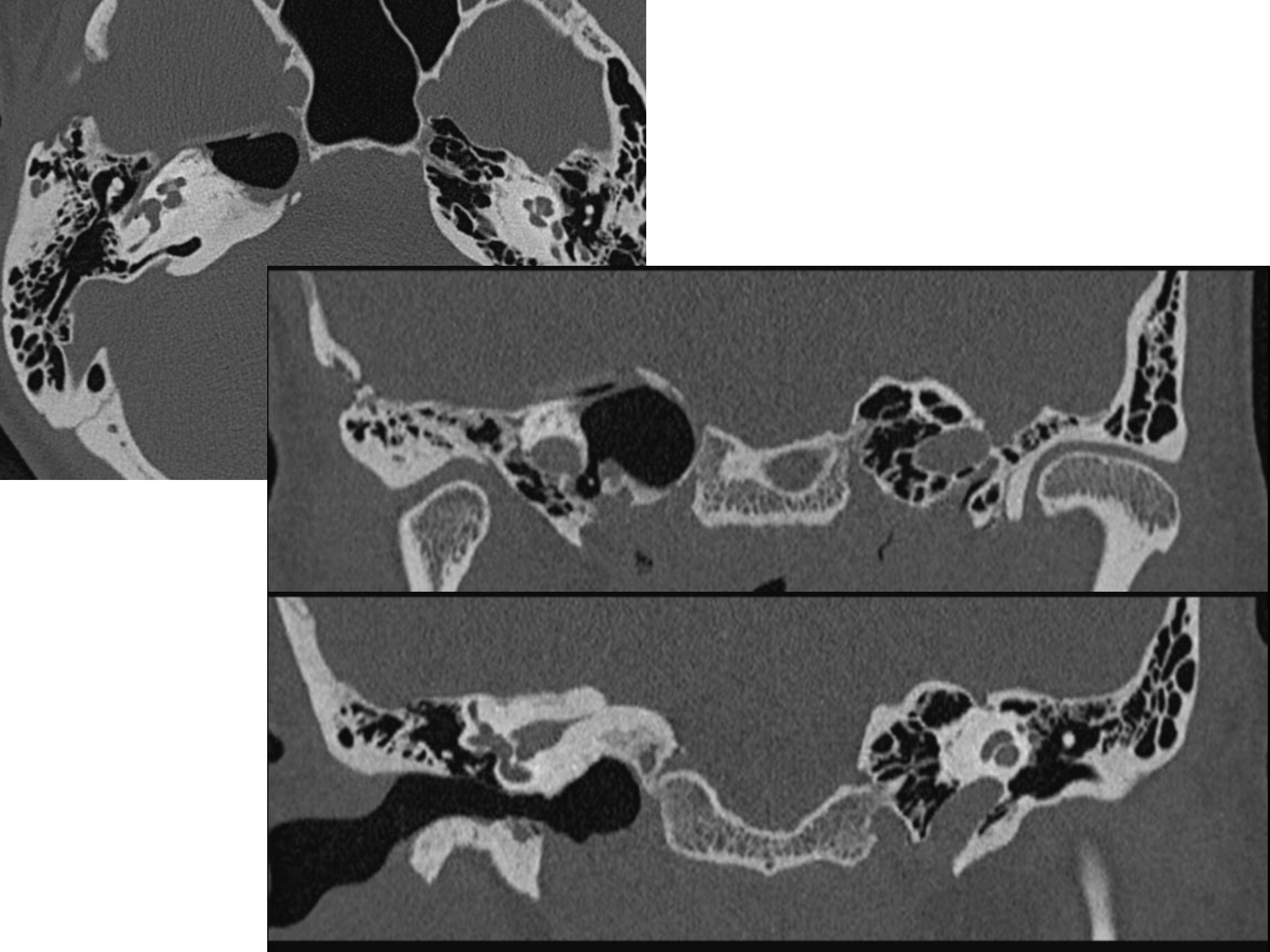

R
5 cm
PHILIPS
F

Mr PAL…. H 50 ans

Névralgie faciale droite
Hypoesthésie V2 et V3

Découverte d’une infiltration V droit

Biopsies chirurgicales

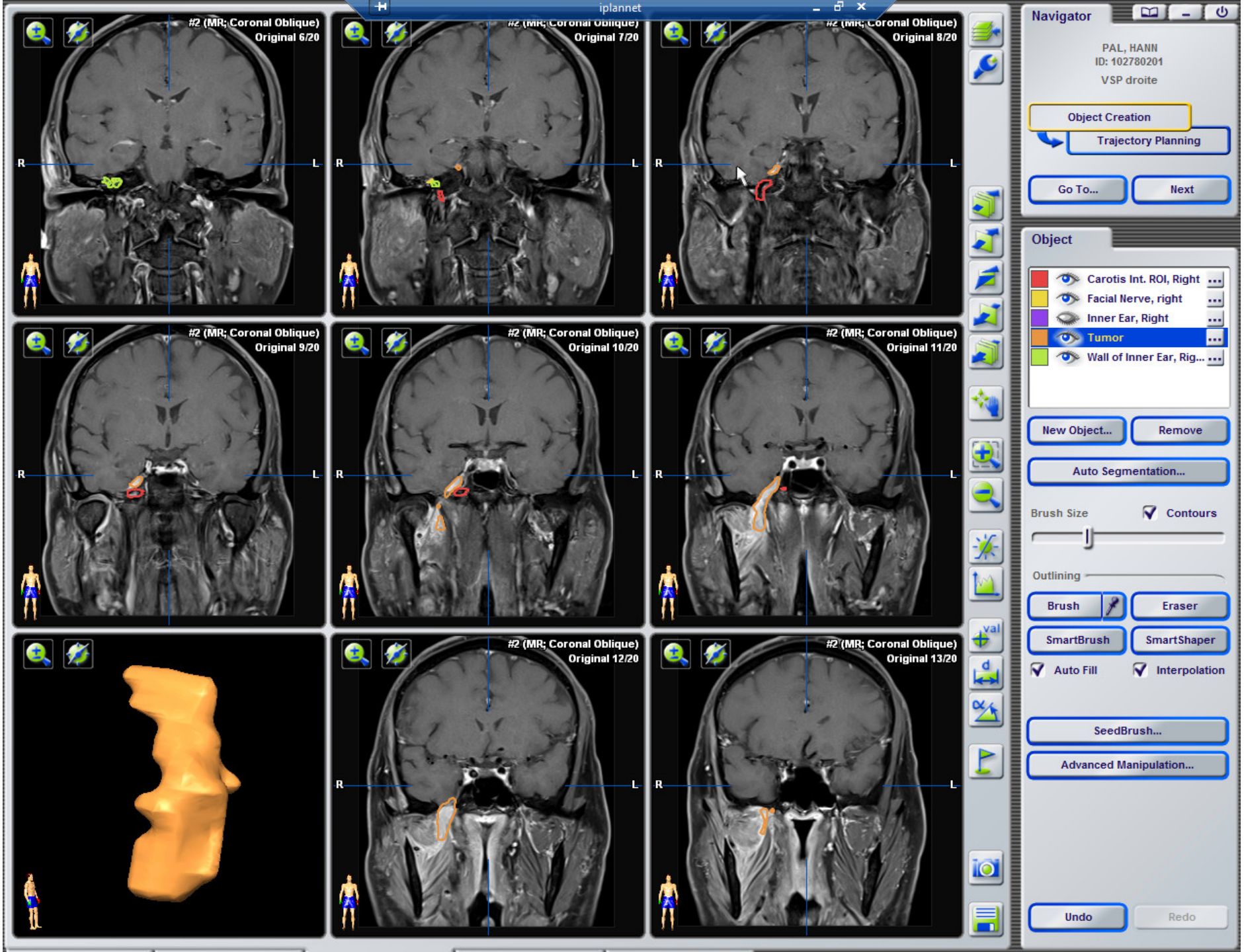
iplannet
#2 (MR; Coronal Oblique)
Original 6/20
Original 7/20
Original 8/20
Original 9/20
Original 10/20
Original 11/20
Original 12/20
Original 13/20
R
L
Navigator
PAL, HANN
ID: 102780201
VSP droite
Object Creation
Trajectory Planning
Go To...
Next
Object
Carotis Int. ROI, Right
Facial Nerve, right
Inner Ear, Right
Tumor
Wall of Inner Ear, Rig...
New Object...
Remove
Auto Segmentation...
Brush Size
Contours
Outlining
Brush
Eraser
SmartBrush
SmartShaper
Auto Fill
Interpolation
SeedBrush...
Advanced Manipulation...
Undo
Redo

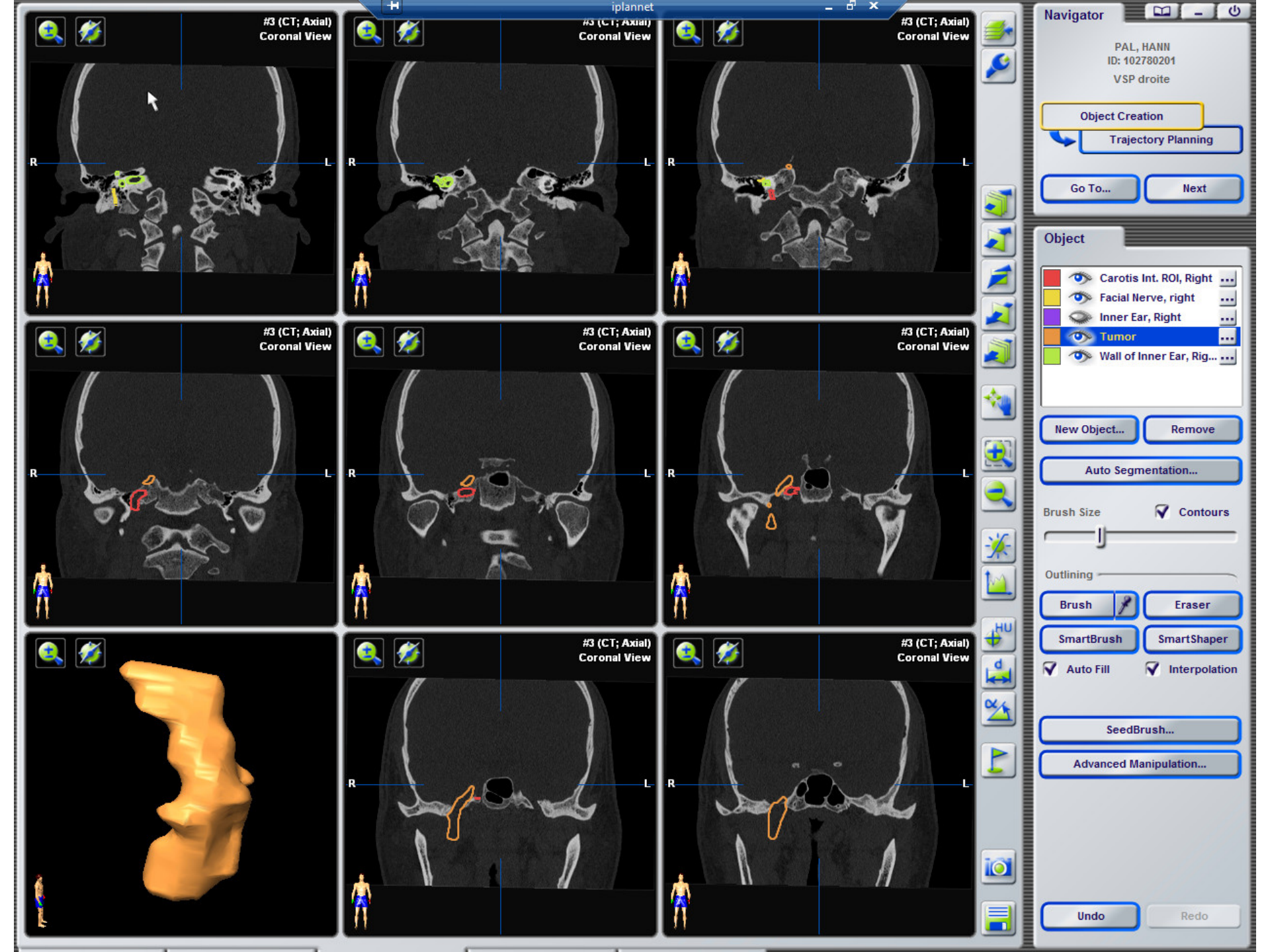
iplannet
#3 (CT; Axial)
Coronal View
R
L
Navigator
PAL, HANN
ID: 102780201
VSP droite
Object Creation
Trajectory Planning
Go To...
Next
Object
Carotis Int. ROI, Right
Facial Nerve, right
Inner Ear, Right
Tumor
Wall of Inner Ear, Rig...
New Object...
Remove
Auto Segmentation...
Brush Size
Contours
Outlining
Brush
Eraser
SmartBrush
SmartShaper
Auto Fill
Interpolation
SeedBrush...
Advanced Manipulation...
Undo
Redo

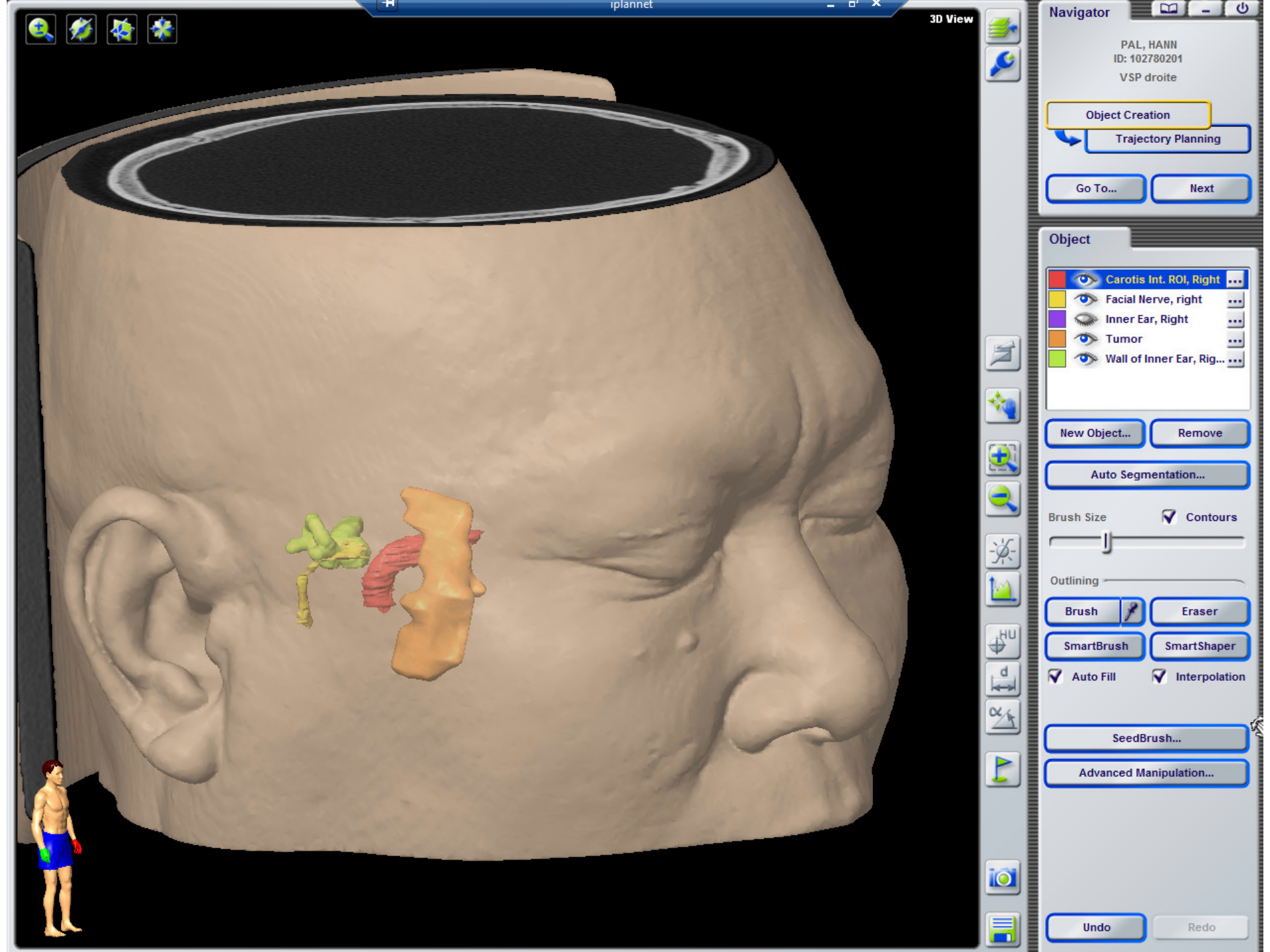
iplannet
3D View
Navigator
PAL, HANN
ID: 102780201
VSP droite
Object Creation
Trajectory Planning
Go To...
Next
Object
Carotis Int. ROI, Right
Facial Nerve, right
Inner Ear, Right
Tumor
Wall of Inner Ear, Rig...
New Object...
Remove
Auto Segmentation...
Brush Size
Contours
Outlining
Brush
Eraser
SmartBrush
SmartShaper
Auto Fill
Interpolation
SeedBrush...
Advanced Manipulation...
Undo
Redo

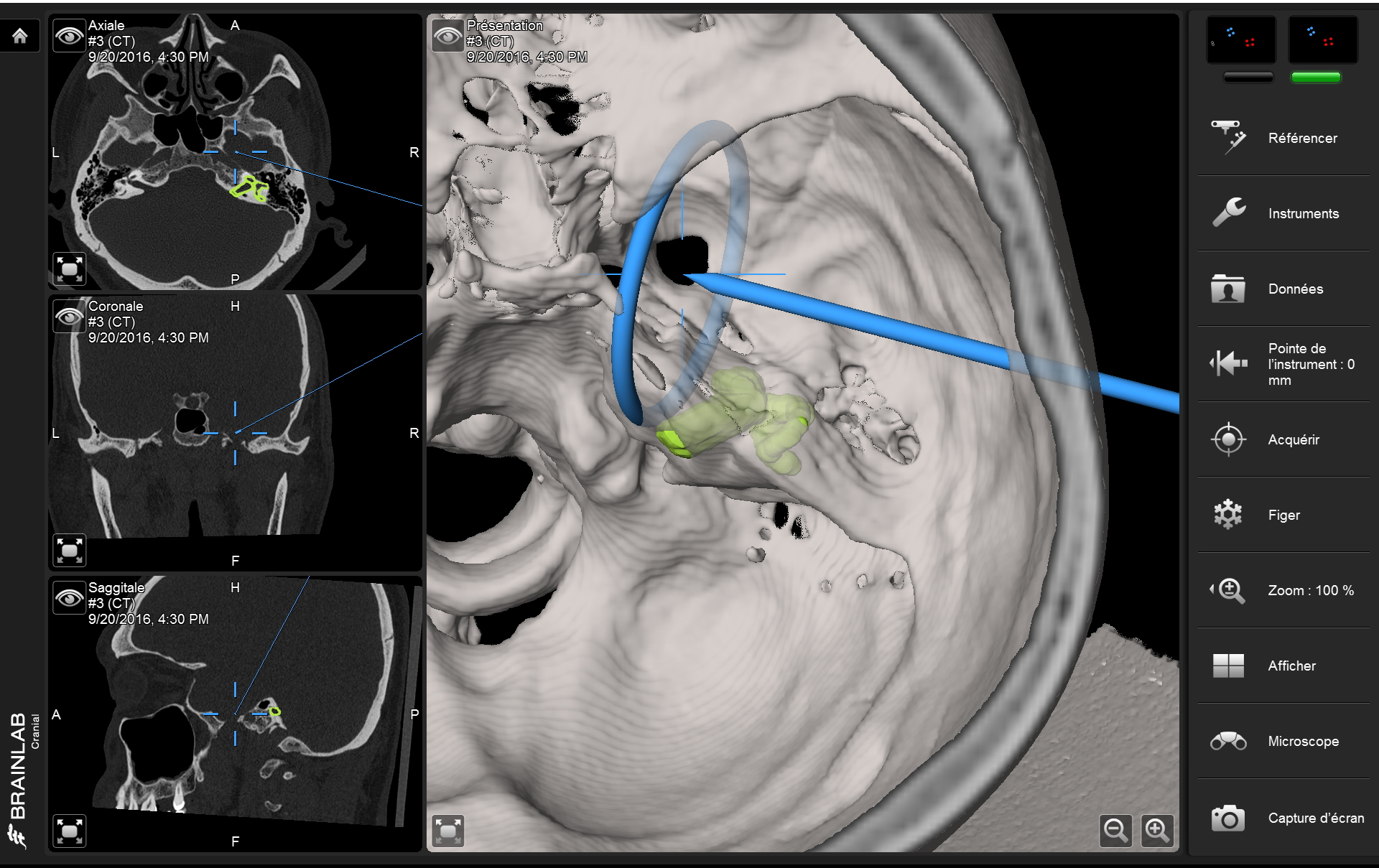

PAL, HANN - 102780201

16-November-2016 12-39-08 PM

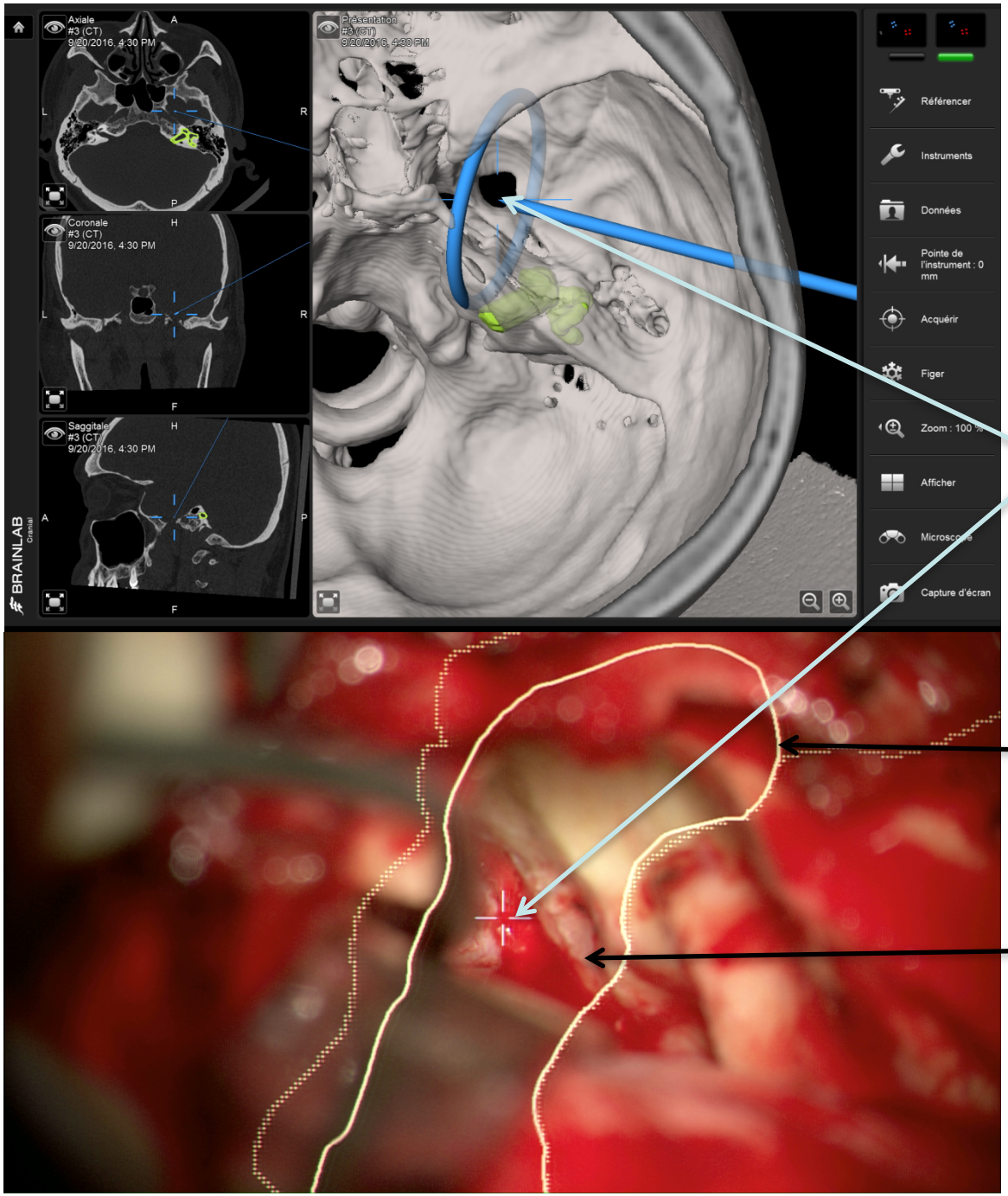

Localisation au point focale

Projection de la lésion

Bordure du Foramen Ovale

Voie rétrosigmoïde pour neurimome de l'acoustique de stade 2

VOLUMETRIC REPORT

Patient Name:		User:	Autologin User
Patient ID:		Report Date:	Mar/21/2017, 11:56:18 AM
Date of Birth:	Feb/12/1984	Object Name:	tumeur

Scan Date:	Sep/28/2016, 11:50:54 AM
Modality:	MR
Series Description:	IRM OREILLES +; e-THRIVE GADO; e-THRIVE GADO; ABDOMEN

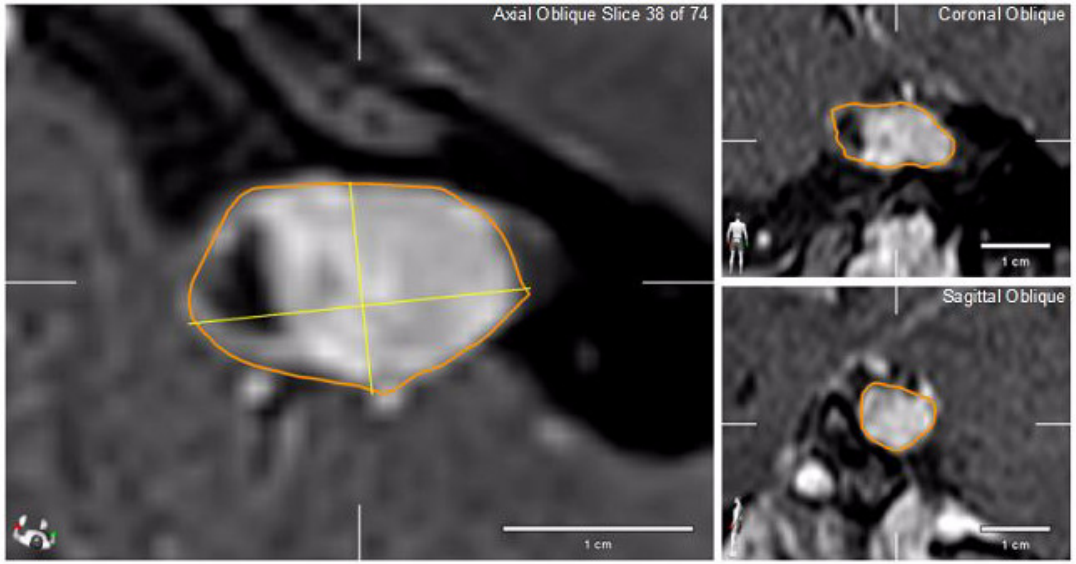

Volume:	1.1 cm³
Macdonald Criteria*:	2.1 (= 1.8 cm x 1.1 cm)
RECIST**:	1.8 cm

Comment:	Created by Smartbrush

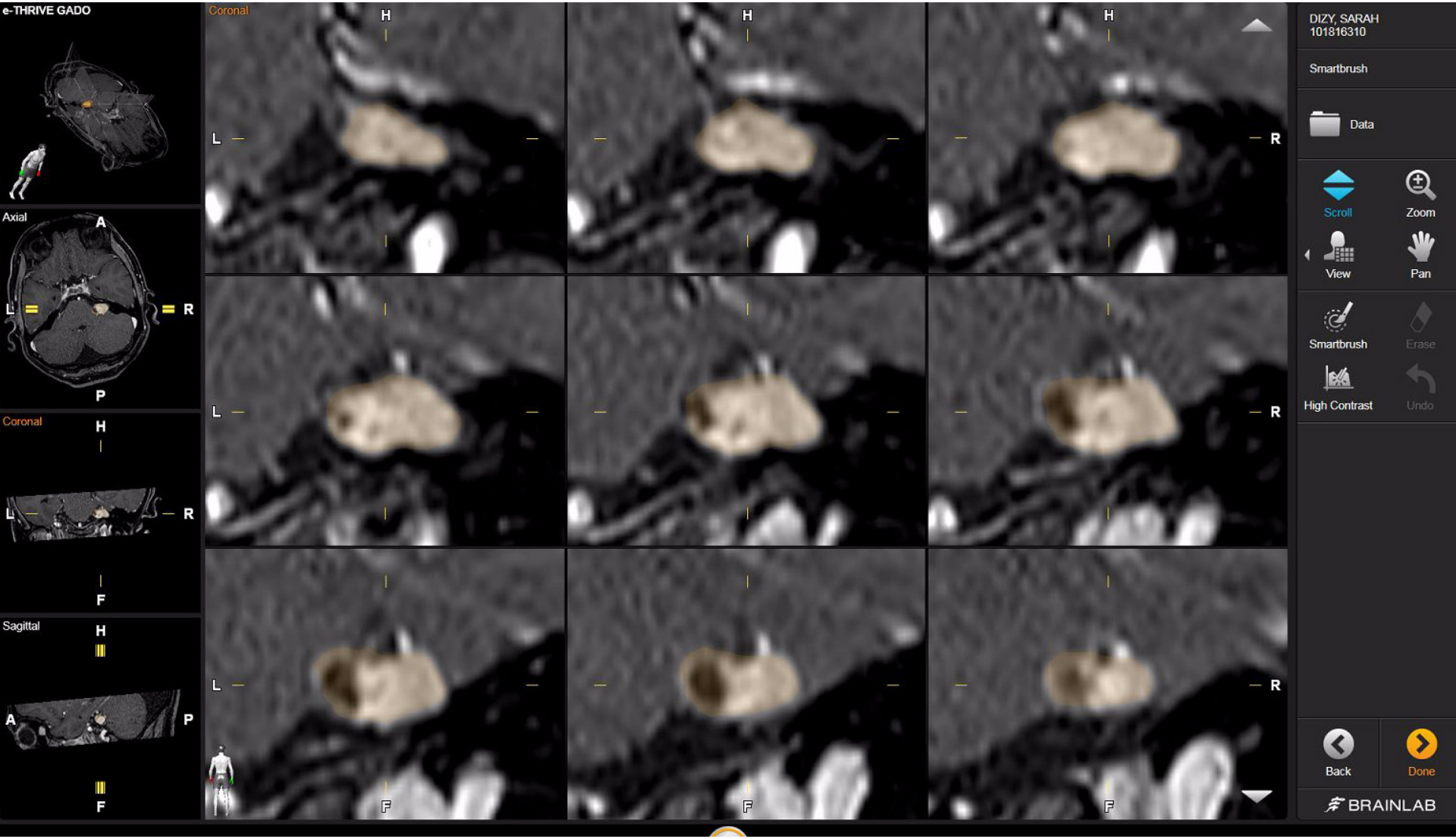
e-THRIVE GADO
Axial
A
L
R
P
Coronal
H
L
R
F
Sagittal
H
A
P
F
Coronal
H
L
R
F
DIZY, SARAH
101816310
Smartbrush
Data
Scroll
Zoom
View
Pan
Smartbrush
Erase
High Contrast
Undo
Back
Done
BRAINLAB

T20s 3 3/3 3/3

Default Plan Name 24/01/2017, 19:03:51

0.5 mm MRI 66 #1
0.3 mm CT 97 #2
0.9 mm CT 280 #3
0.3 cm³ emissary vein
0.1 cm³ Inner Ear, Right
0.4 cm³ Inner Ear, Right (01)
0.2 cm³ jugular

Select All

Less

SCAN OREILLES 12/01/2017, 10:36:41

0.3 mm CT 97 ROCHERS
0.5 mm CT 560 SINUS
0.9 mm CT 280 BRAIN LAB OS
0.4 mm CT 60 ROCHER DROIT AXIAL
0.4 mm CT 60 ROCHER DROIT CORO

More

IRM OREILLES + 28/09/2016, 11:36:48

11.0 mm
6.0 mm
7.0 mm
0.5 mm
2.2 mm

SELECTED DATA

DIZY, SARAH
101816310

0.5 mm MRI 66 #1
0.3 mm CT 97 #2
0.9 mm CT 280 #3
0.6 mm MRI 74 e-THRIVE GADO
0.3 cm³ emissary vein
0.1 cm³ Inner Ear, Right
0.4 cm³ Inner Ear, Right (01)
0.2 cm³ jugular
1.1 cm³ new tumeur

OK

BRAINLAB

#1
Axial Oblique Slice 32 of 66
28/09/2016, 11:40:18

#1
Skin
28/09/2016, 11:40:18

#1
Skin/Vessels
28/09/2016, 11:40:18

#2
Axial Slice 29 of 97
12/01/2017, 10:39:02

#3
Axial Slice 144 of 280
12/01/2017, 10:41:22

e-THRIVE GADO
Axial Oblique Slice 36 of 74
28/09/2016, 11:50:54

e-THRIVE GADO
Skin
28/09/2016, 11:50:54

#1
Axial Oblique Slice 32 of 66
28/09/2016, 11:40:18

DIZY, SARAH
101816310

DICOM Viewer

Data

Scroll
Zoom
Pan

3D Options

Threshold
Crop
Select ROI
Reset
Add View

#1
Axial Oblique Slice 37 of 66
28/09/2016, 11:40:18

#1
Skin
28/09/2016, 11:40:18

#1
Skin/Vessels
28/09/2016, 11:40:18

#2
Axial Slice 36 of 97
12/01/2017, 10:39:02

#3
Axial Slice 146 of 280
12/01/2017, 10:41:22

e-THRIVE GADO
Axial Oblique Slice 40 of 74
28/09/2016, 11:50:54

e-THRIVE GADO
Skin
28/09/2016, 11:50:54

#1
Axial Oblique Slice 37 of 66
28/09/2016, 11:40:18

DIZY, SARAH
101816310

DICOM Viewer

Data

Scroll
Zoom
Pan

3D Options

Threshold
Crop
Select ROI
Reset
Add View

Back
Done

BRAINLAB

Axe de la voie d'abord et point focal sur le fond du CAI

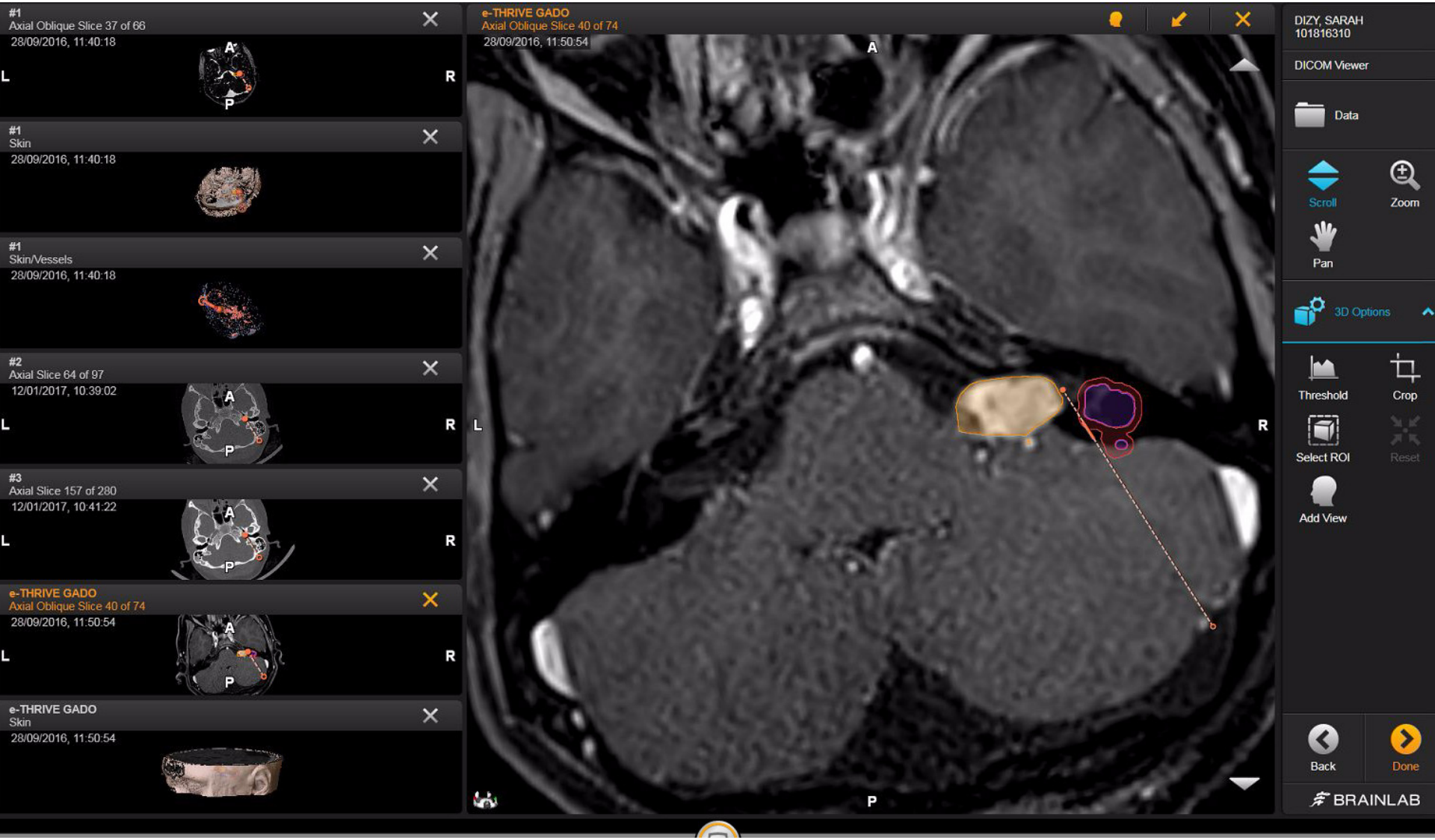

Axe de la voie d'abord et point focal sur le fond du CAI

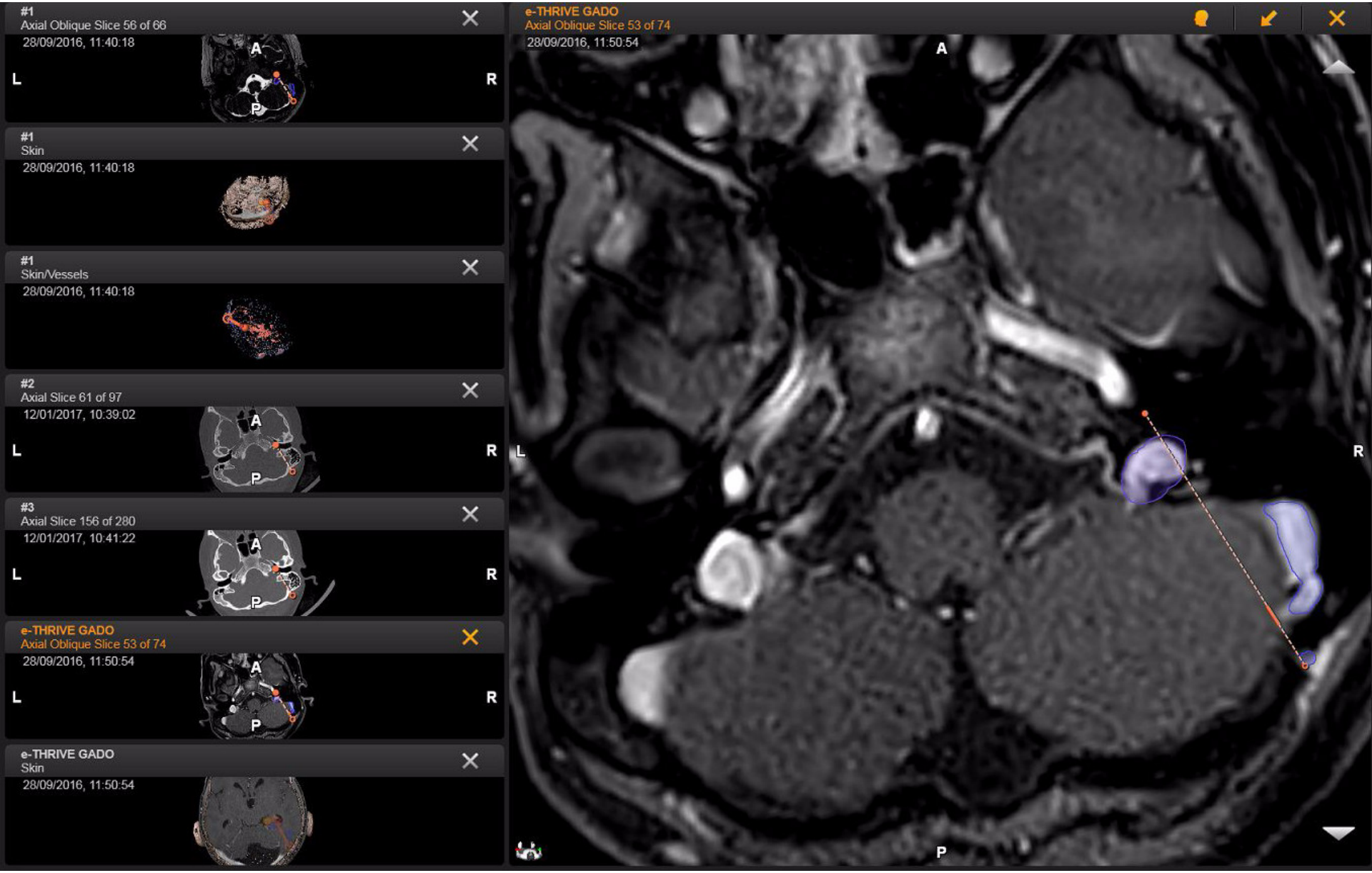

Axe de la voie d'abord et point focal sur le fond du CAI

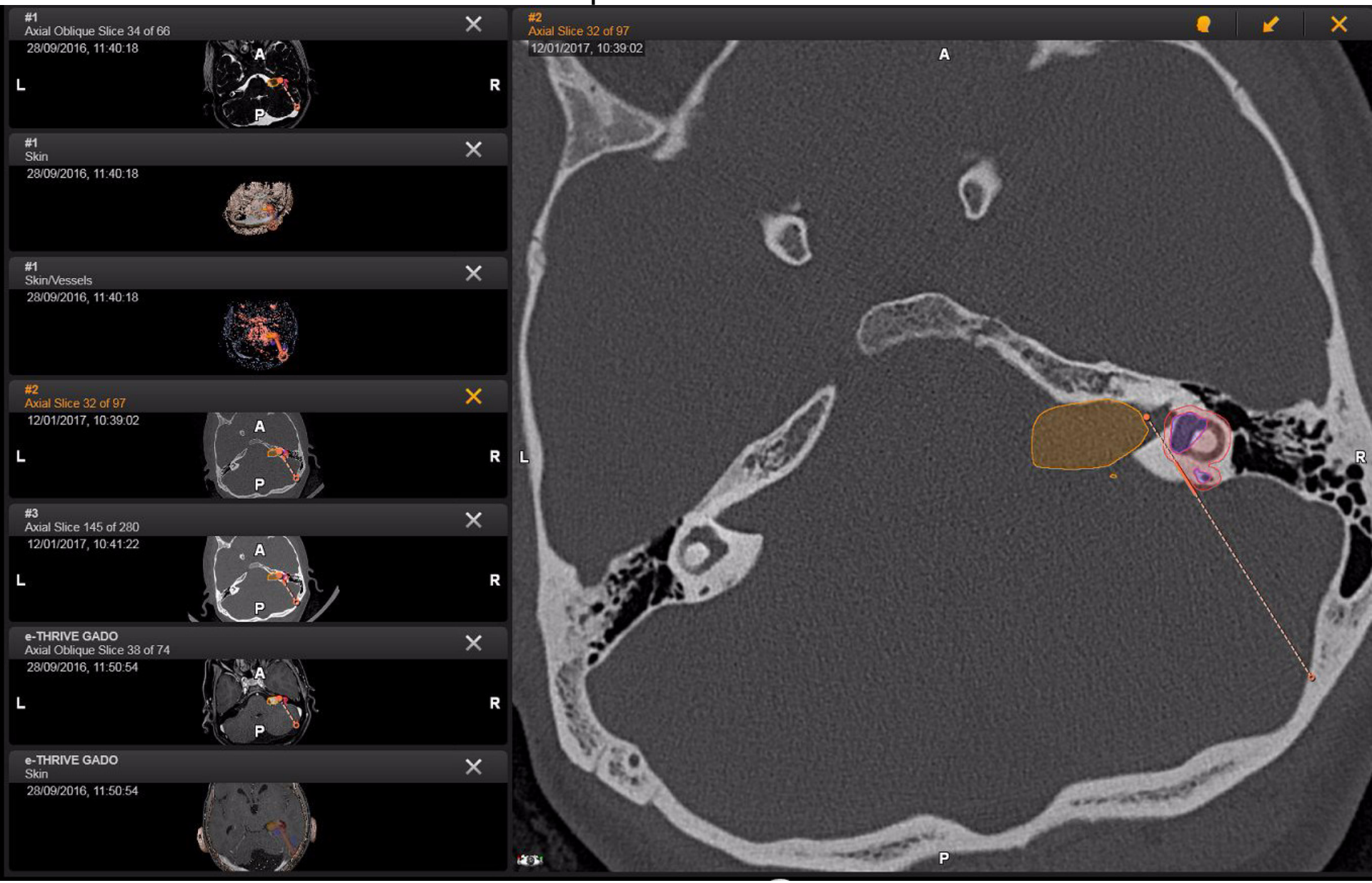

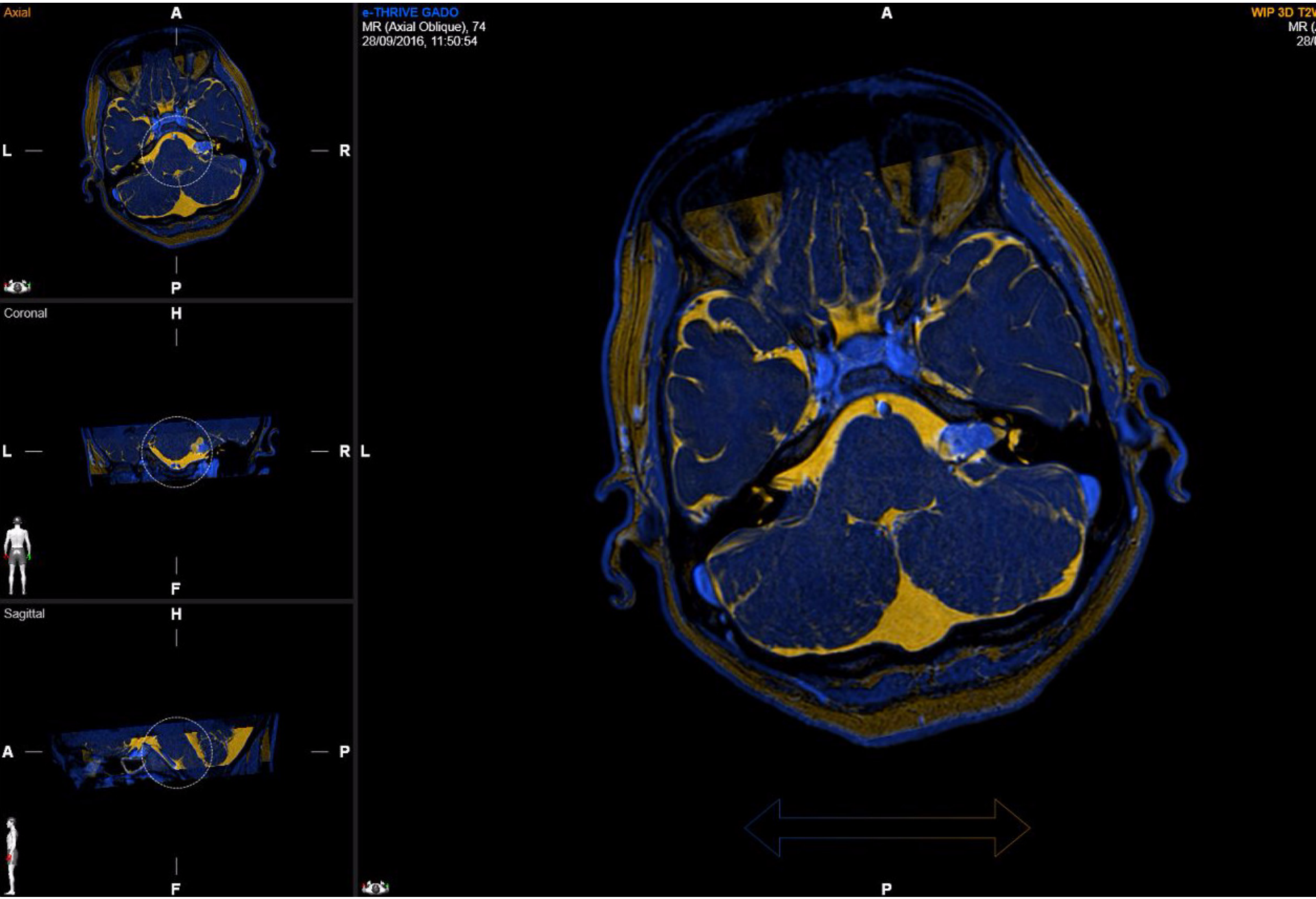
Axial
A
L
R
P
Coronal
H
L
R
F
Sagittal
H
A
P
F
e-THRIVE GADO
MR (Axial Oblique), 74
28/09/2016, 11:50:54
A
L
P
WIP 3D T2

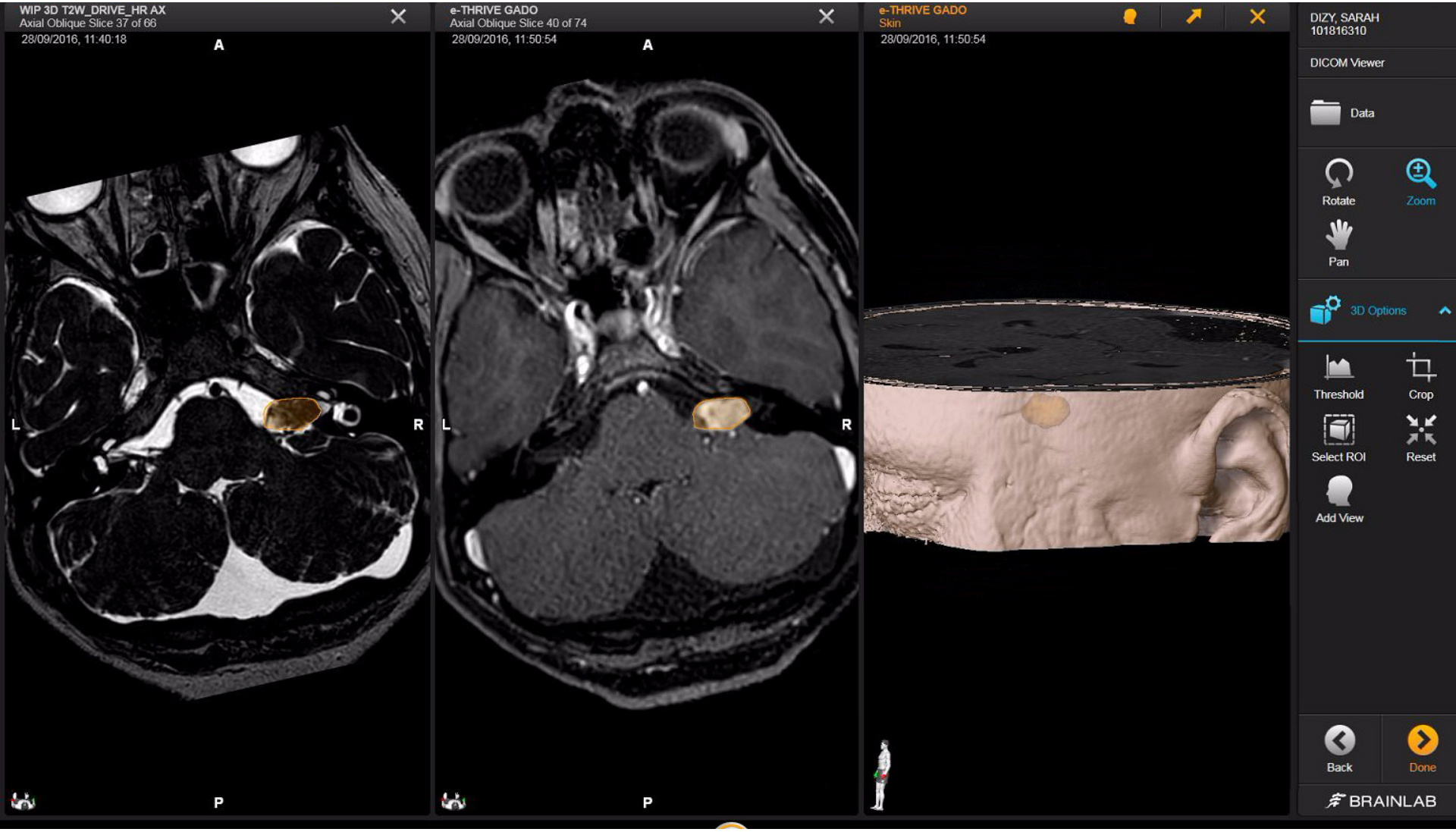
WIP 3D T2W_DRIVE_HR AX
Axial Oblique Slice 37 of 66
28/09/2016, 11:40:18
A
L
R
P
e-THRIVE GADO
Axial Oblique Slice 40 of 74
28/09/2016, 11:50:54
A
L
R
P
e-THRIVE GADO
Skin
28/09/2016, 11:50:54
DIZY, SARAH
101816310
DICOM Viewer
Data
Rotate
Zoom
Pan
3D Options
Threshold
Crop
Select ROI
Reset
Add View
Back
Done
BRAINLAB

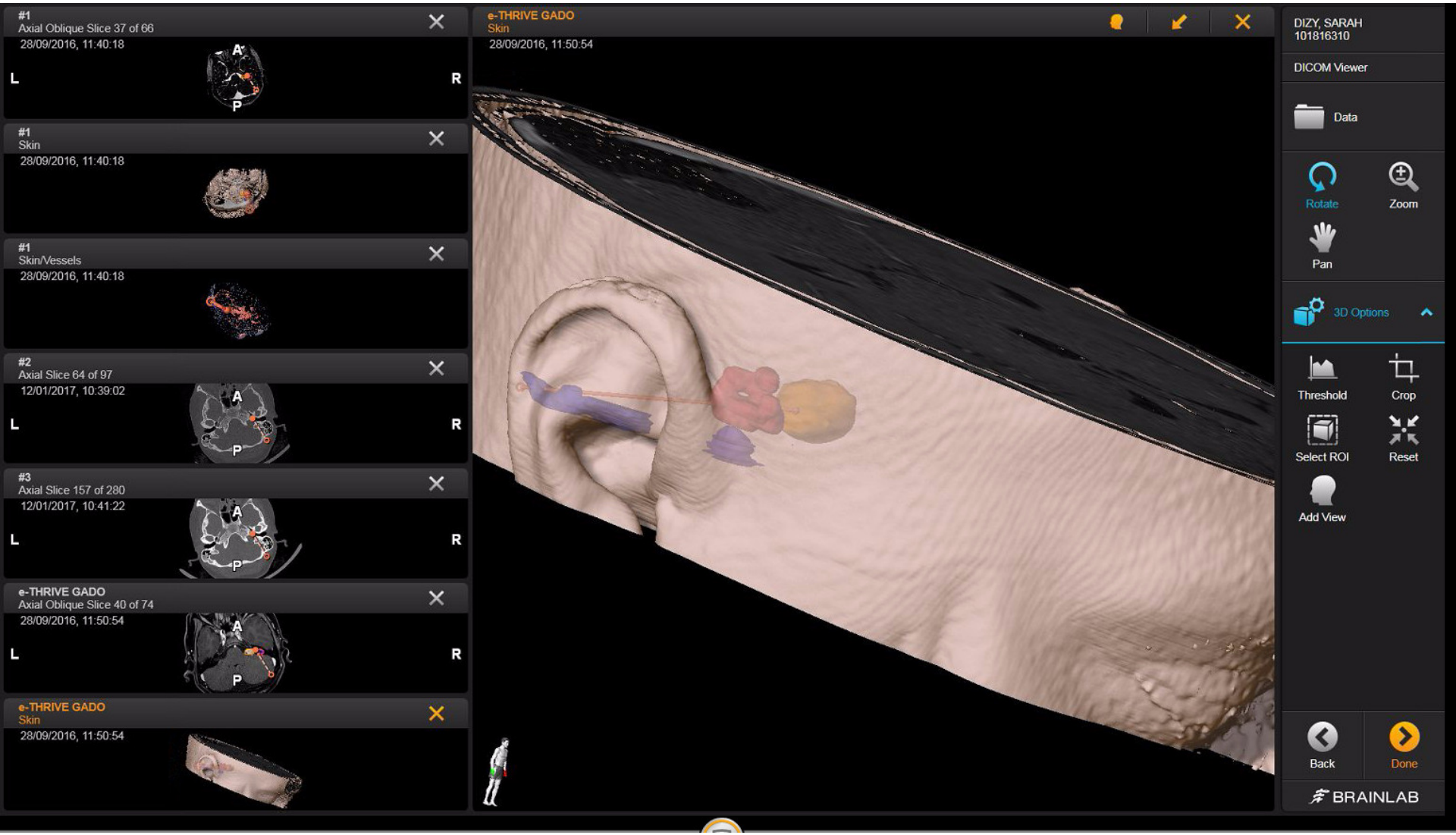
#1
Axial Oblique Slice 37 of 66
28/09/2016, 11:40:18
A
P
L
R
#1
Skin
28/09/2016, 11:40:18
#1
Skin/Vessels
28/09/2016, 11:40:18
#2
Axial Slice 64 of 97
12/01/2017, 10:39:02
A
P
L
R
#3
Axial Slice 157 of 280
12/01/2017, 10:41:22
A
P
L
R
e-THRIVE GADO
Axial Oblique Slice 40 of 74
28/09/2016, 11:50:54
A
P
L
R
e-THRIVE GADO
Skin
28/09/2016, 11:50:54
e-THRIVE GADO
Skin
28/09/2016, 11:50:54
DIZY, SARAH
101816310
DICOM Viewer
Data
Rotate
Zoom
Pan
3D Options
Threshold
Crop
Select ROI
Reset
Add View
Back
Done
BRAINLAB

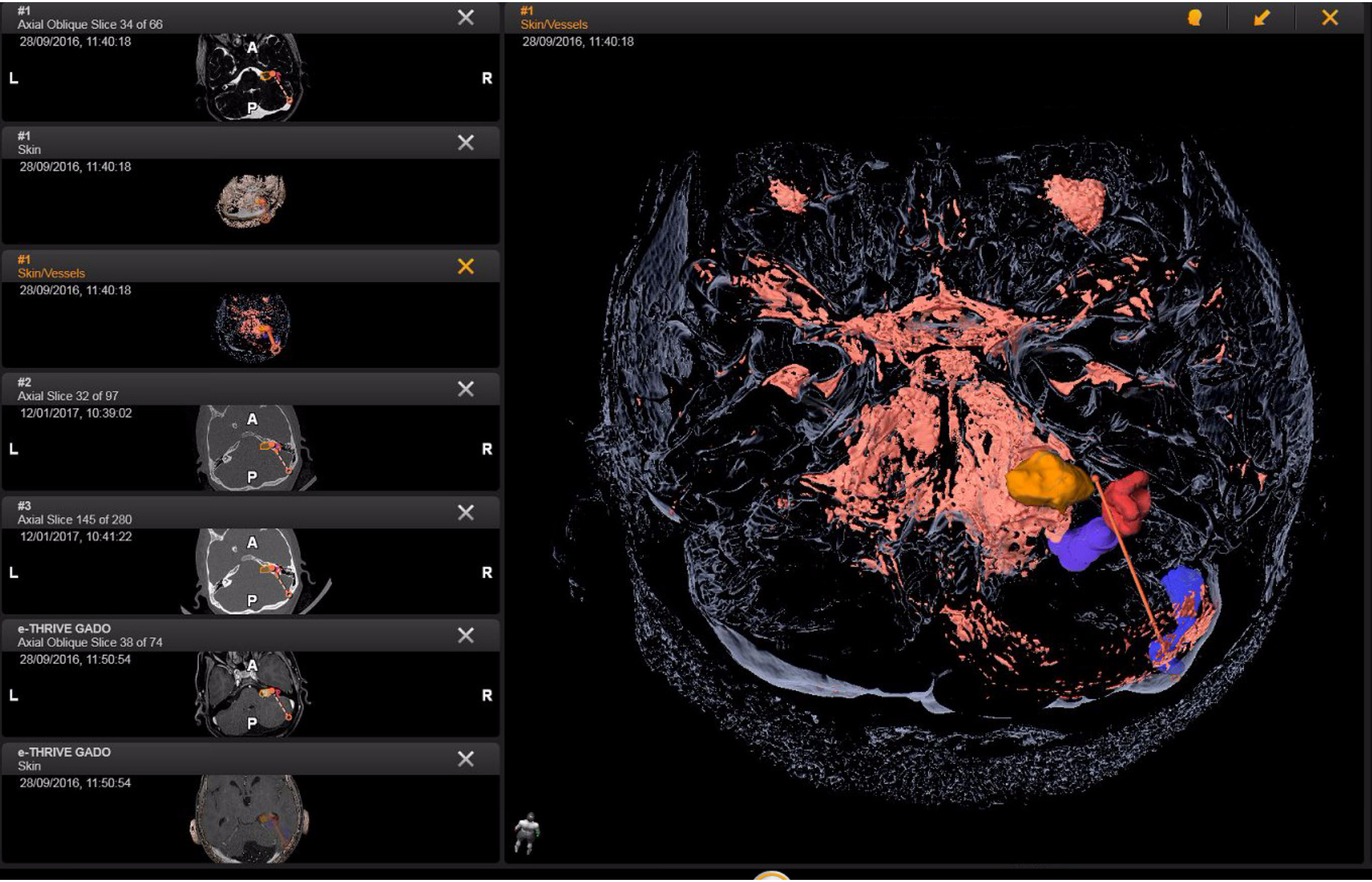
#1
Axial Oblique Slice 34 of 66
28/09/2016, 11:40:18
A
P
L
R
#1
Skin
28/09/2016, 11:40:18
#1
Skin/Vessels
28/09/2016, 11:40:18
#2
Axial Slice 32 of 97
12/01/2017, 10:39:02
A
P
L
R
#3
Axial Slice 145 of 280
12/01/2017, 10:41:22
A
P
L
R
e-THRIVE GADO
Axial Oblique Slice 38 of 74
28/09/2016, 11:50:54
A
P
L
R
e-THRIVE GADO
Skin
28/09/2016, 11:50:54
#1
Skin/Vessels
28/09/2016, 11:40:18

Vue perop en bleu axe microscope et point focal

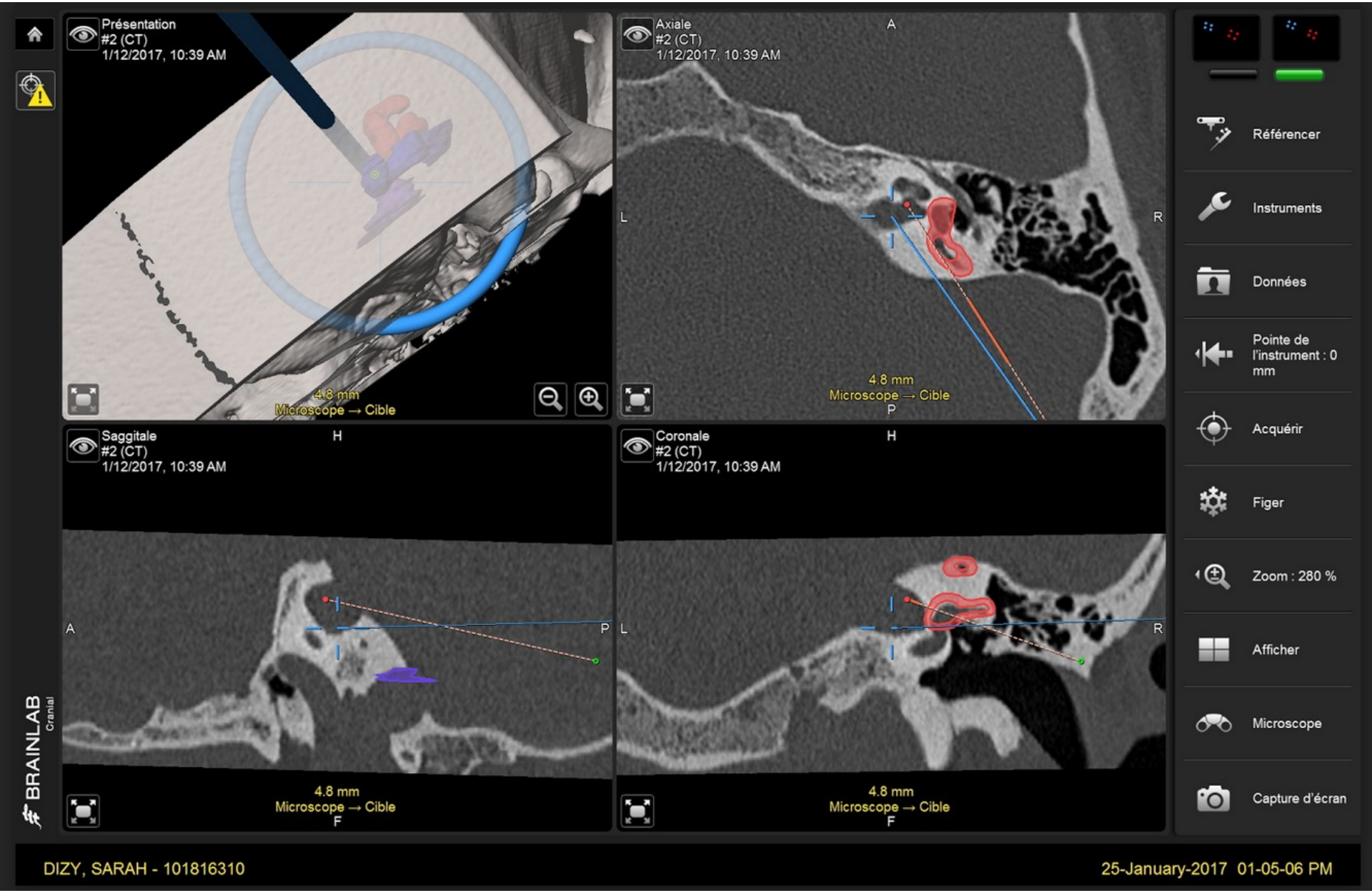

Voie retrosigmoidienne droite
Vue per-opératoire en réalité augmentée

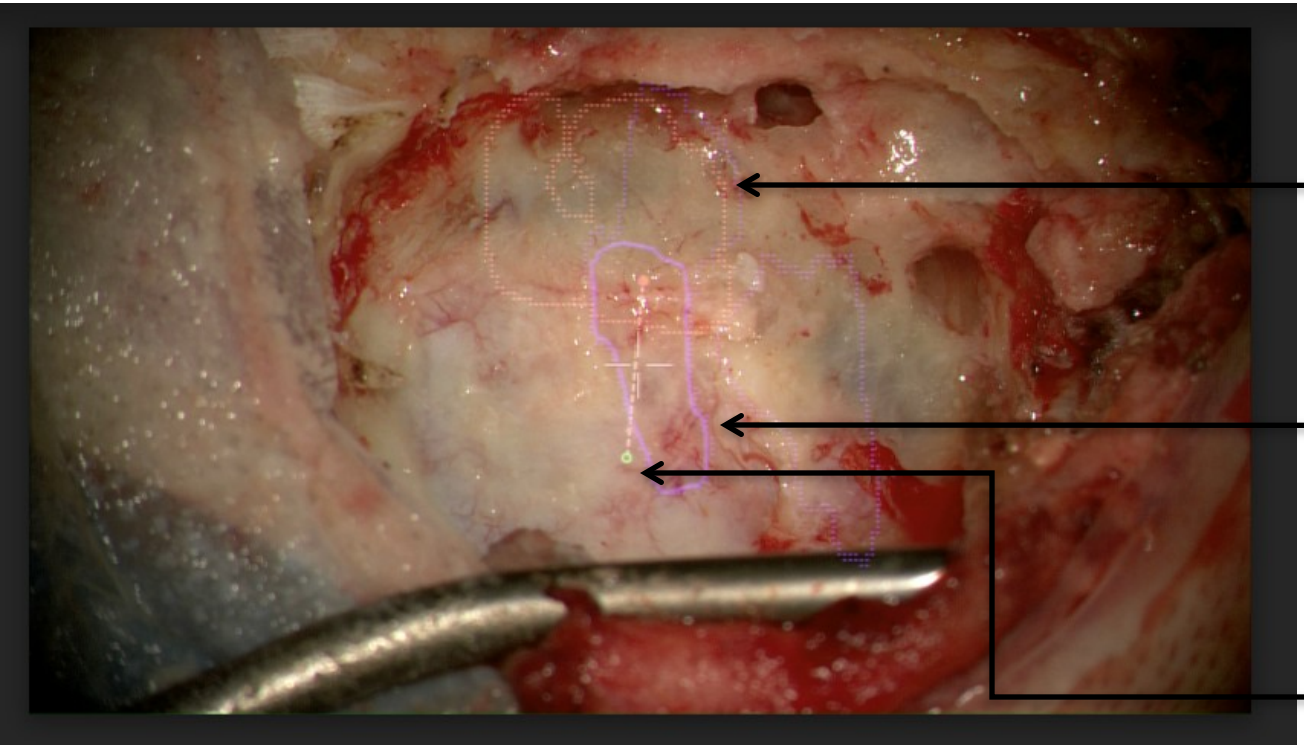

Projection du labyrinthe osseux

Projection du dôme de la jugulaire

Trajectoire planifiée pour la visualisation du fond du CAI

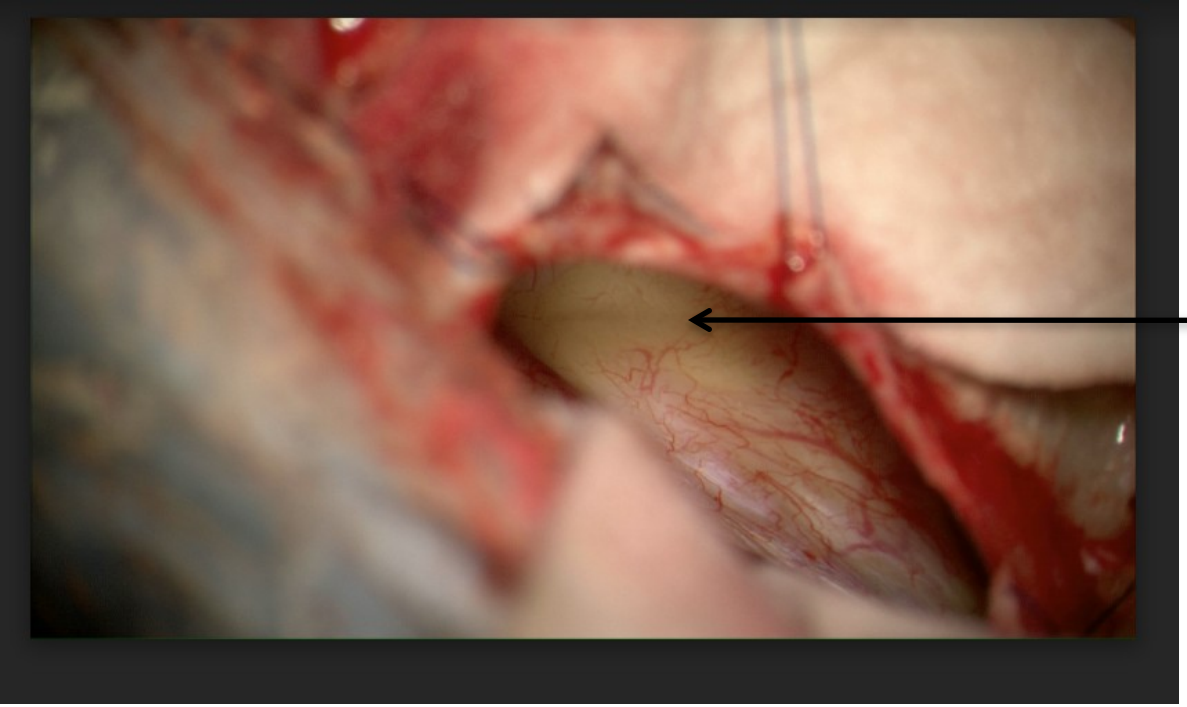

Ligne bleue du canal semi-circulaire postérieur

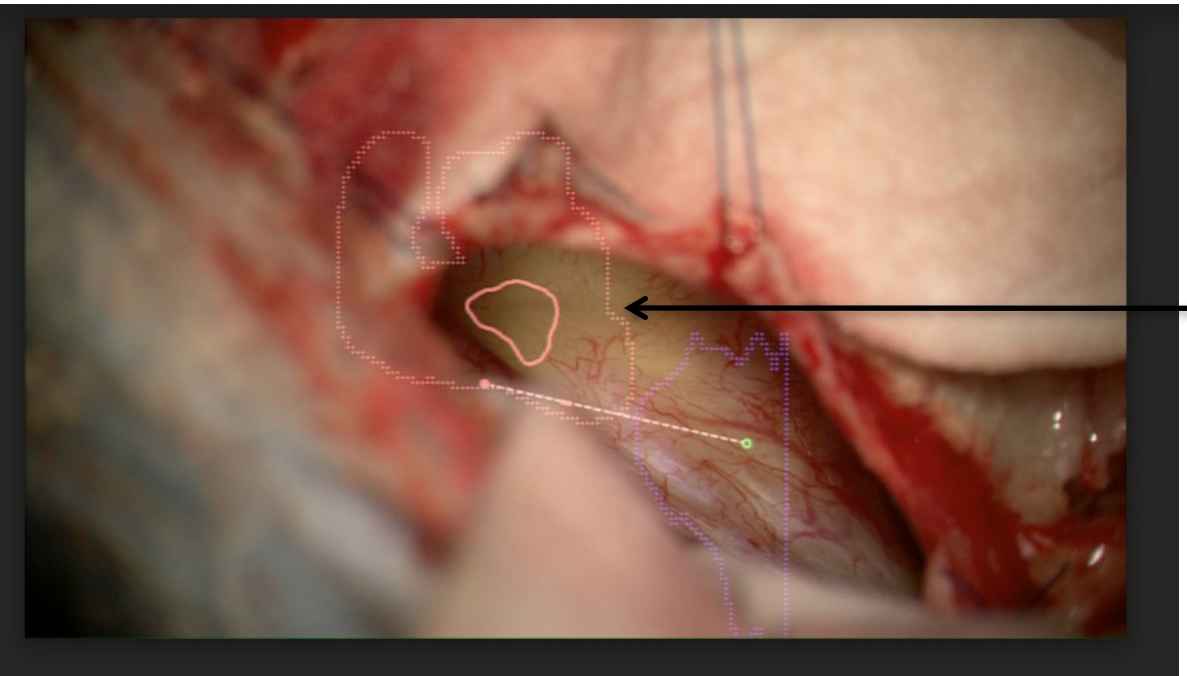

Volume projeté du labyrinthe osseux concordant avec le CSC post

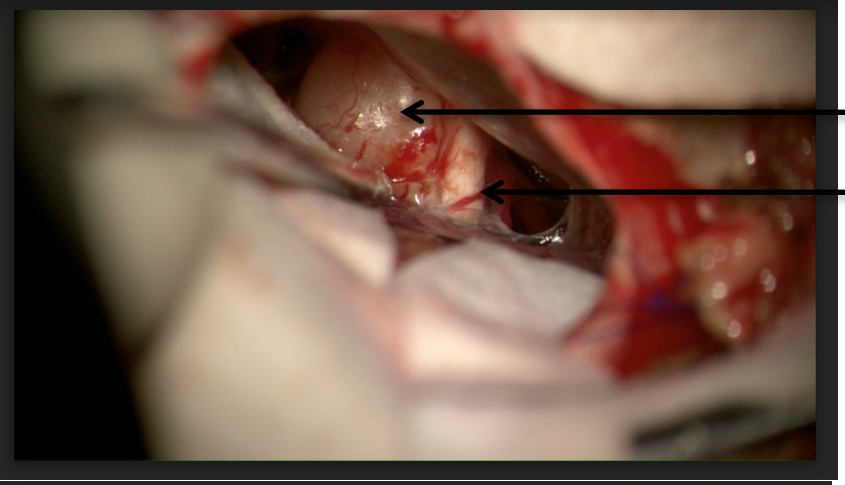

Schwannome vestibulaire

Nerf cochléaire sain

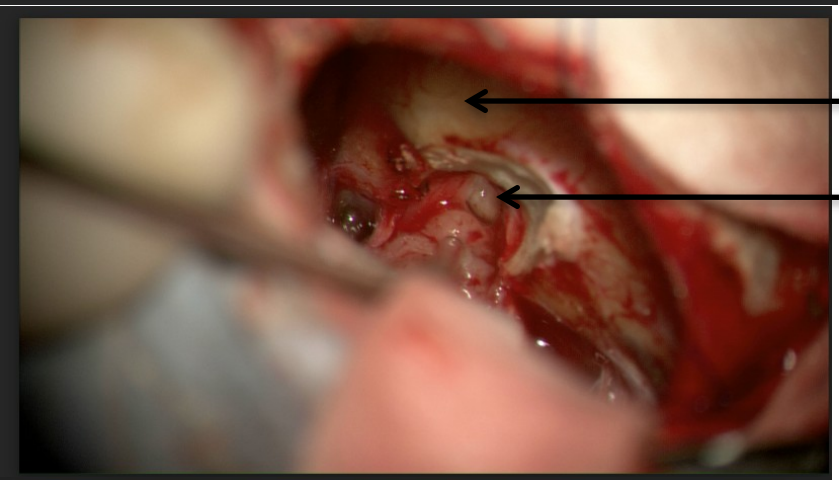

Canal semi-circulaire post

Fraisage du CAI exposant la partie saine de nerfs dont VII

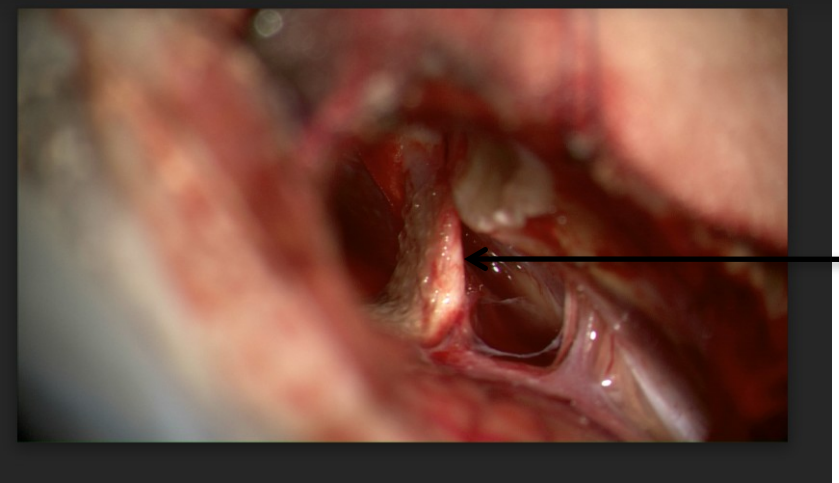

Nerf cochléaire préservé, exérèse complète

Visualisation des liquides endolyphatiques - hydrops FLAIR HR 4h après gadolinium

Frédérique Dubrulle

MD - PhD

CHU Lille - France

- **Hydrops endolymphatique**

  distention des structures contenant de l'endolymphe

  canal endolympatique cochléaire

  saccule

  utricule

  ampoules

- **Un changement de volume de ces structures est corrélé avec un Sd Menieriforme**

  - analyse anatomique du saccule 3D HR T2

  - **visualisation endolymphe – périlymphe**

    FLAIR HR 4h après injection de gadolinium sur 3T

- **anatomie oreille interne – endolymphe**

- **l'hydrops**
  - analyse anatomique du saccule 3D HR T2
  - visualisation endolymphe – périlymphe FLAIR HR avec injection

- **autres pathologies**

anatomie oreille interne – endolymphe à 1.5 T

- **anatomie de l'endolymphe possible à 1.5 T**
  - macule utriculaire
  - saccule
  - utricule

séquence 3D HR T2 oreille interne

Drive HR

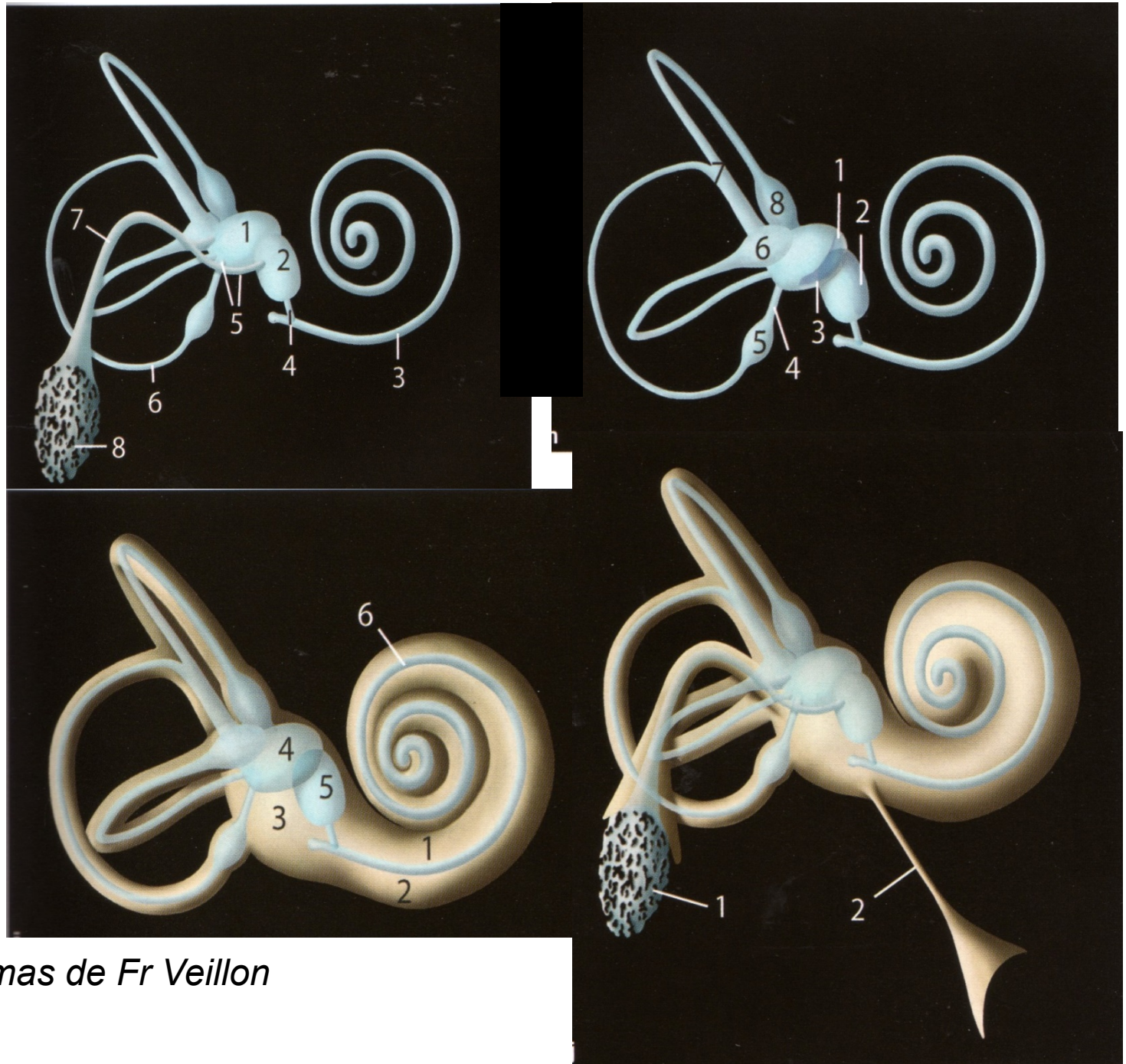

schémas de Fr Veillon

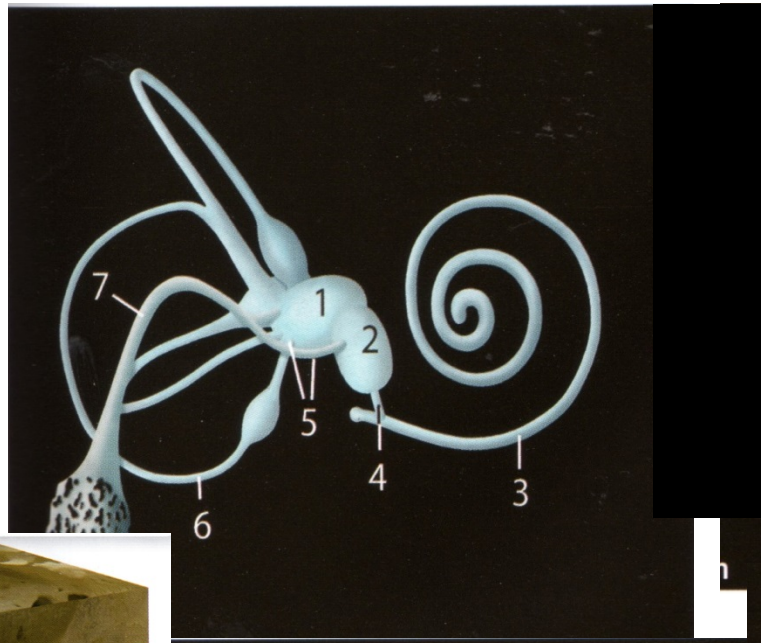

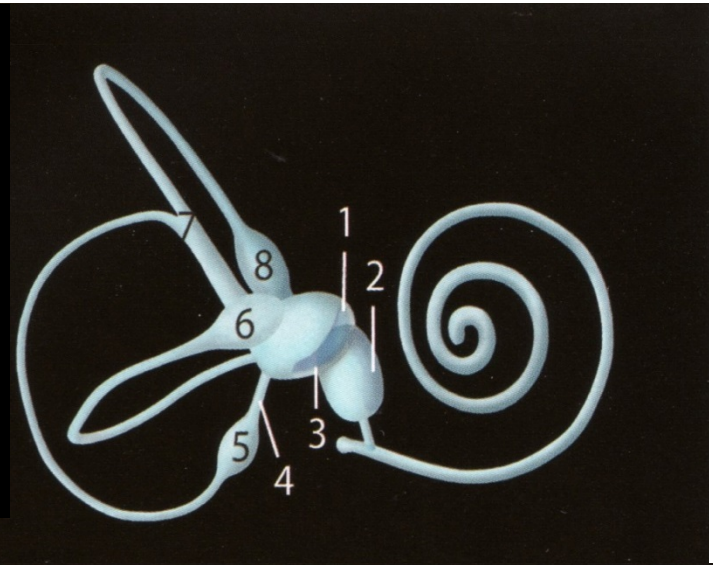



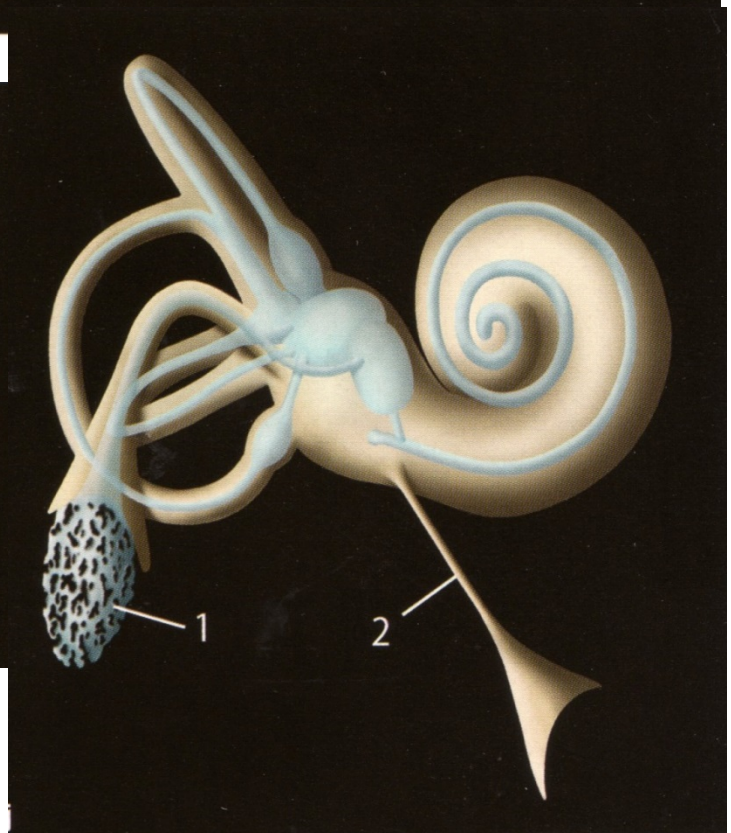

schémas de Francis Veillon



schémas de Fr Veillon

schémas de Fr Veillon

Utricule
Saccule



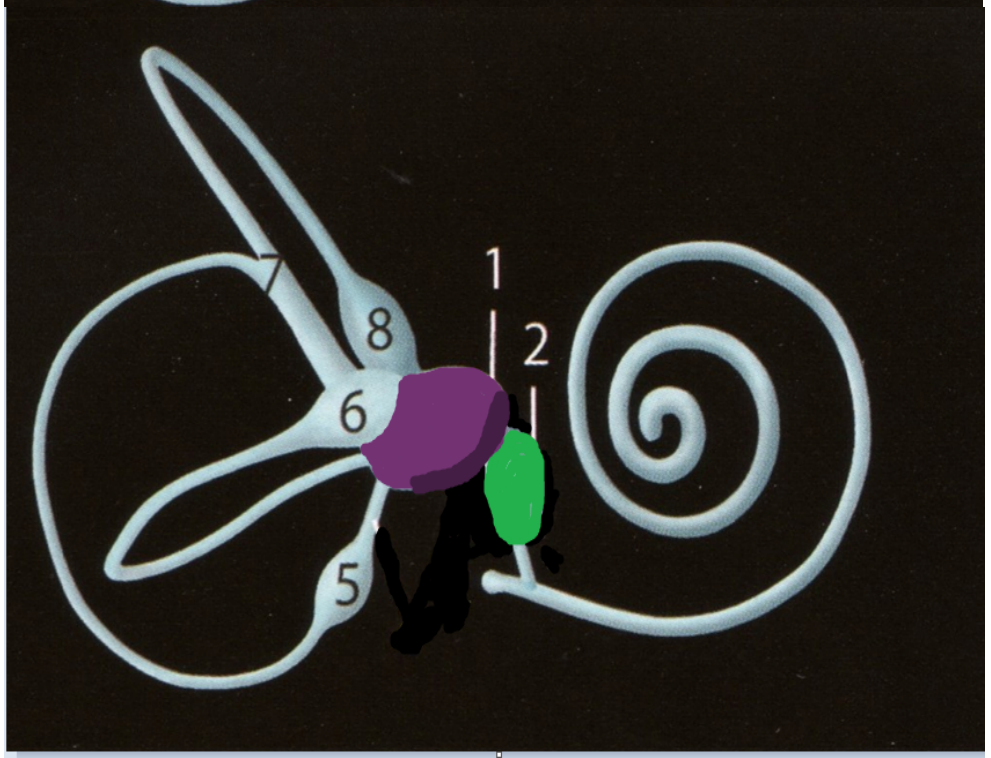

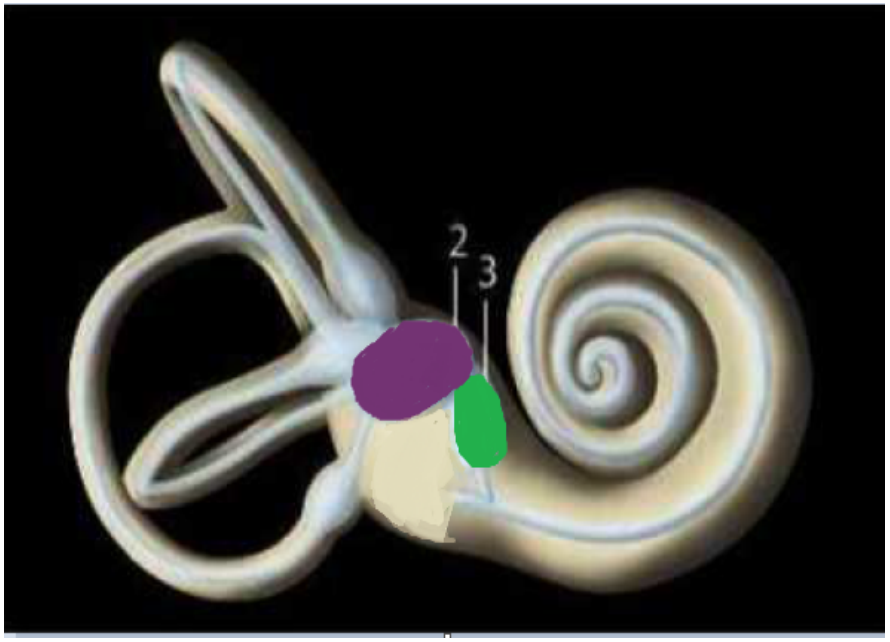

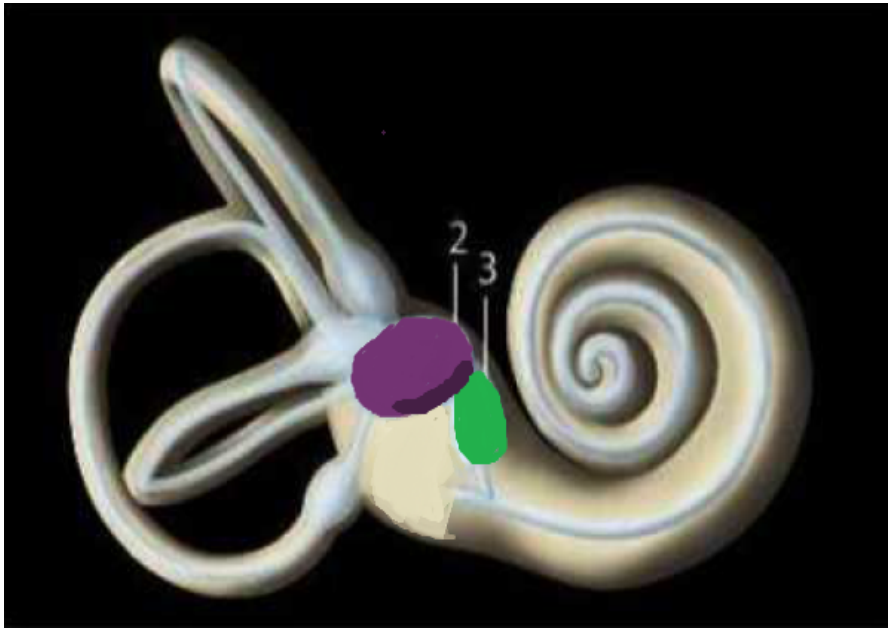

Utricule
Saccule

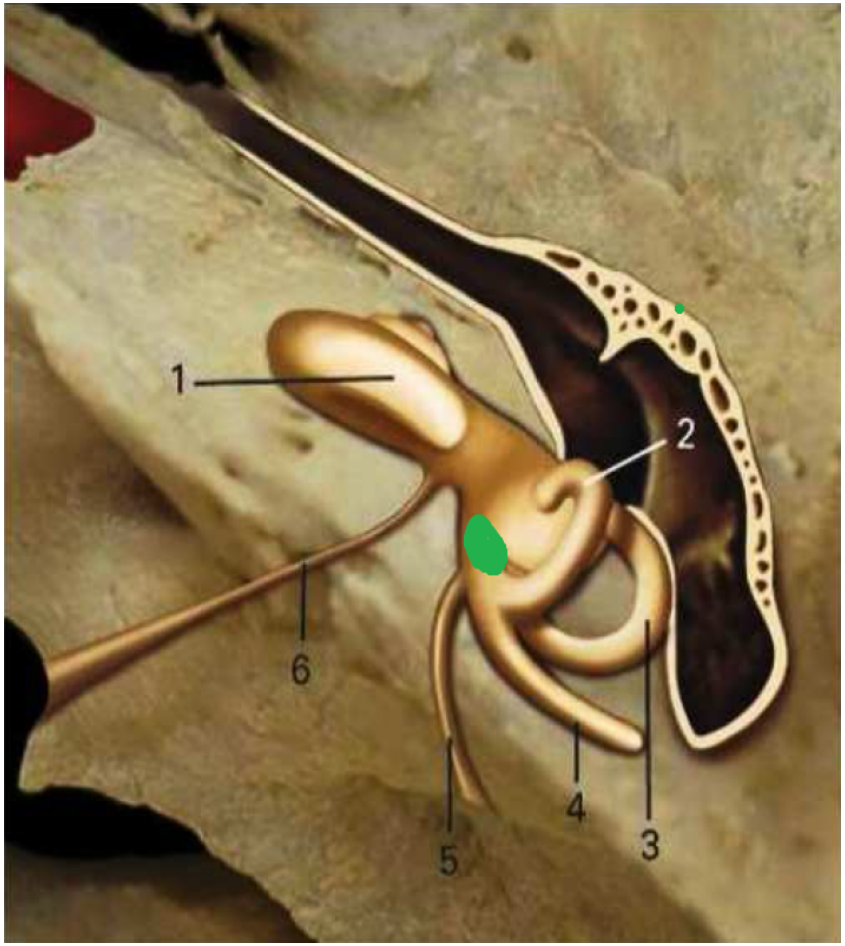

Utricule
Saccule

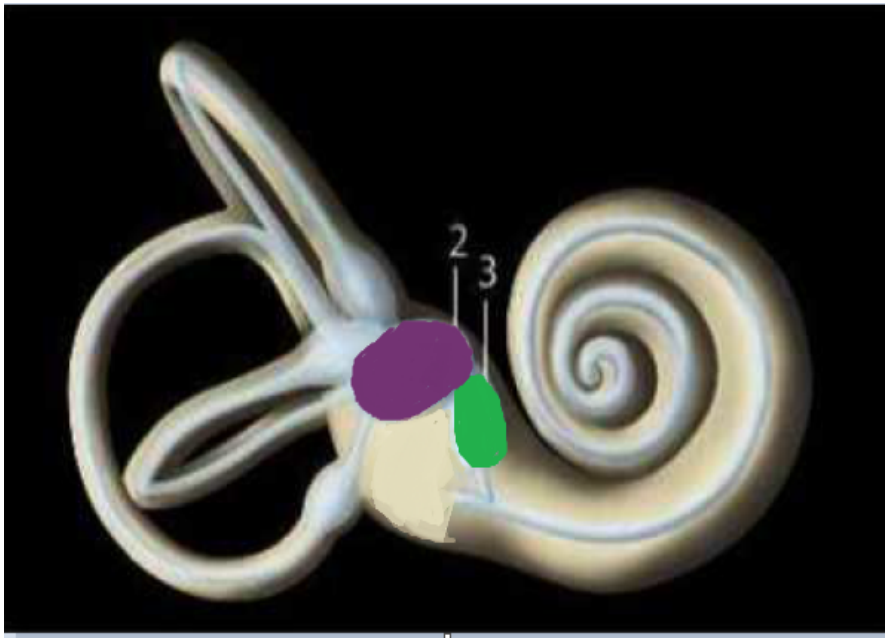

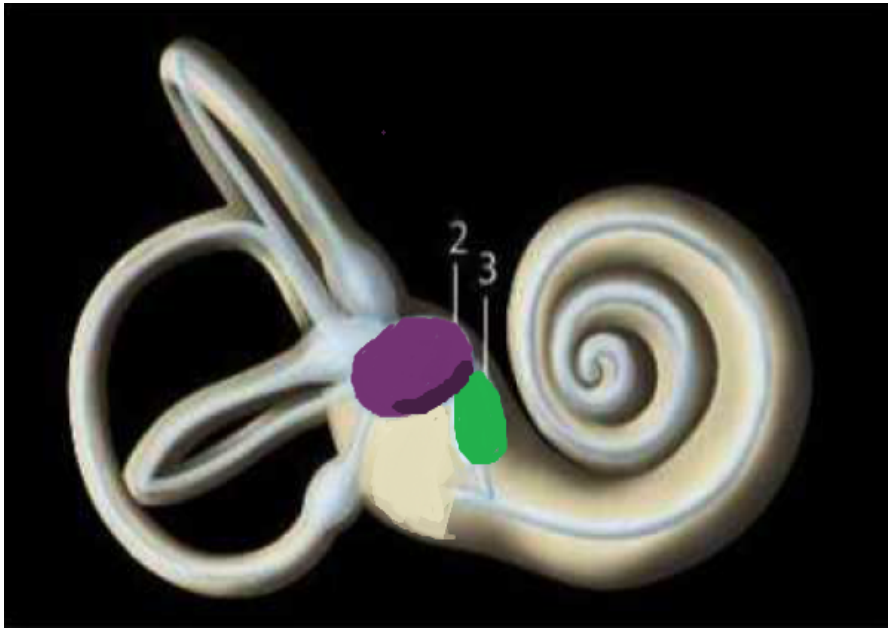

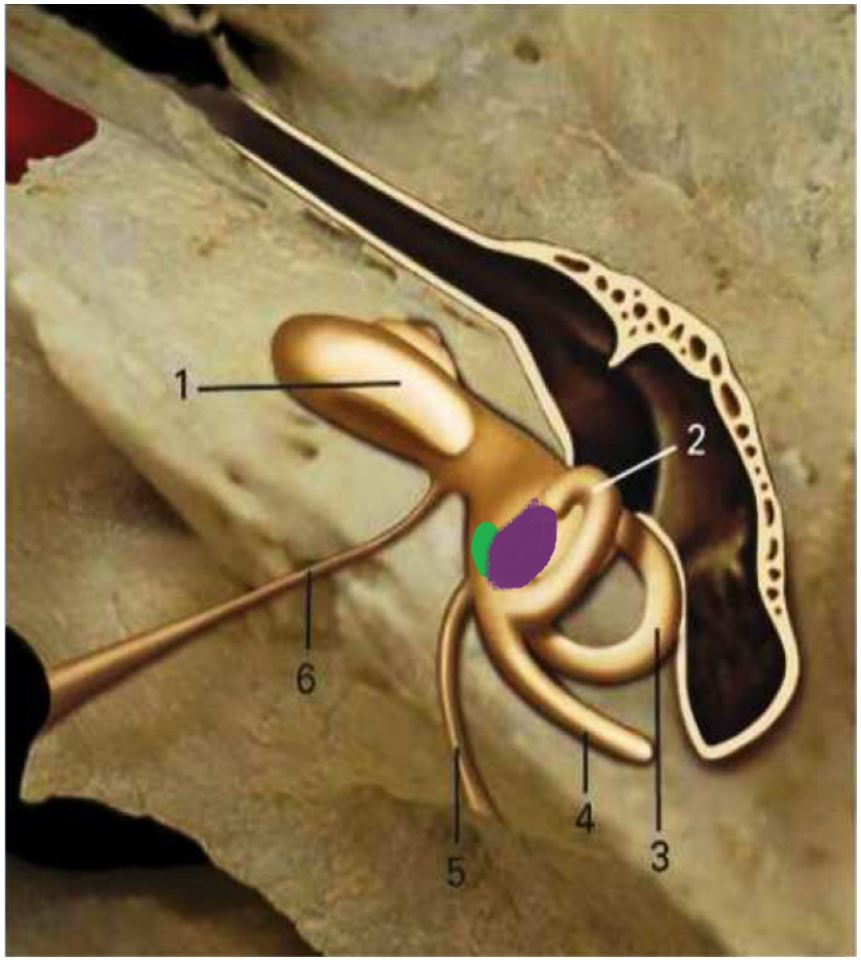

3D HR T2

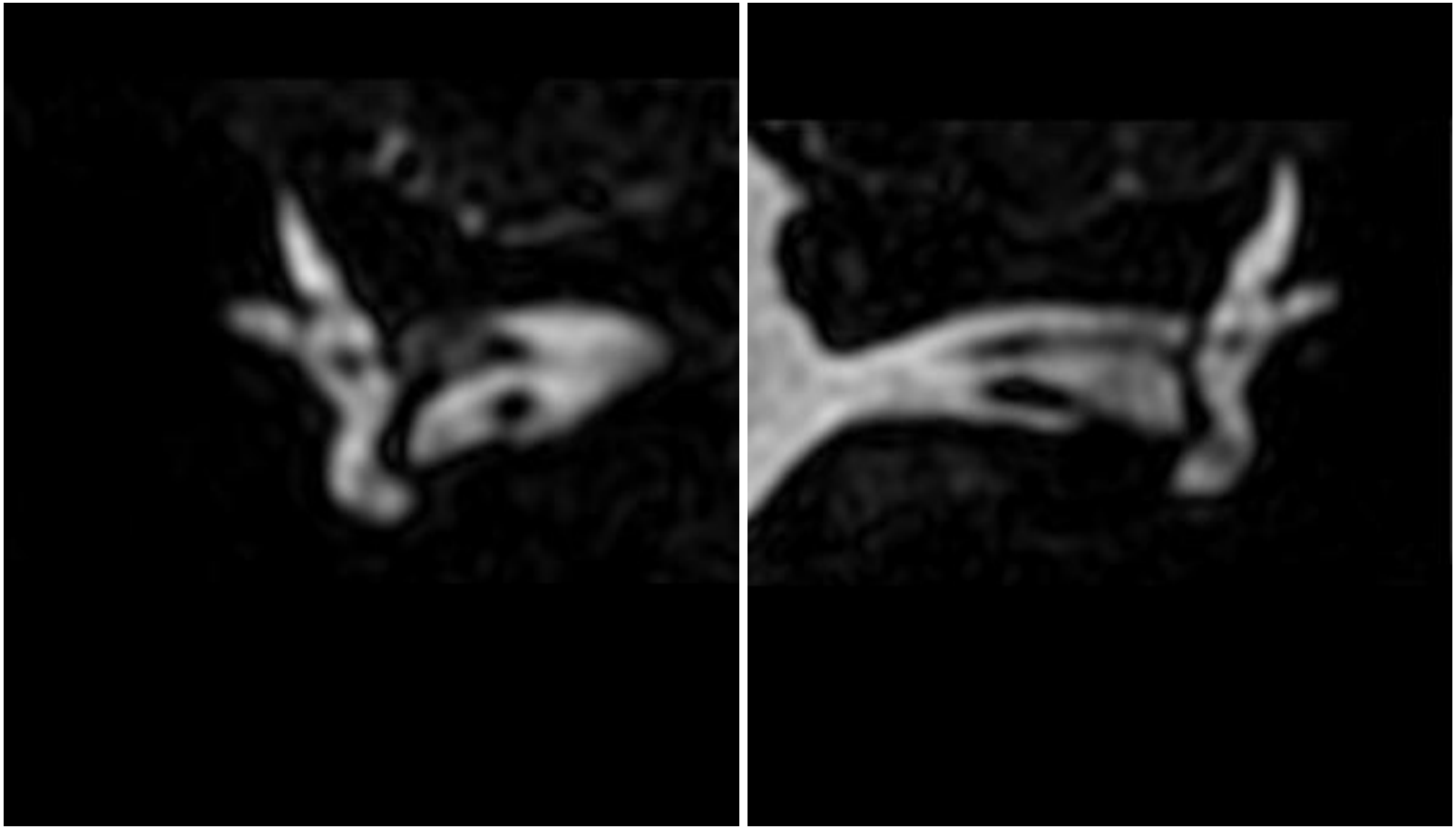

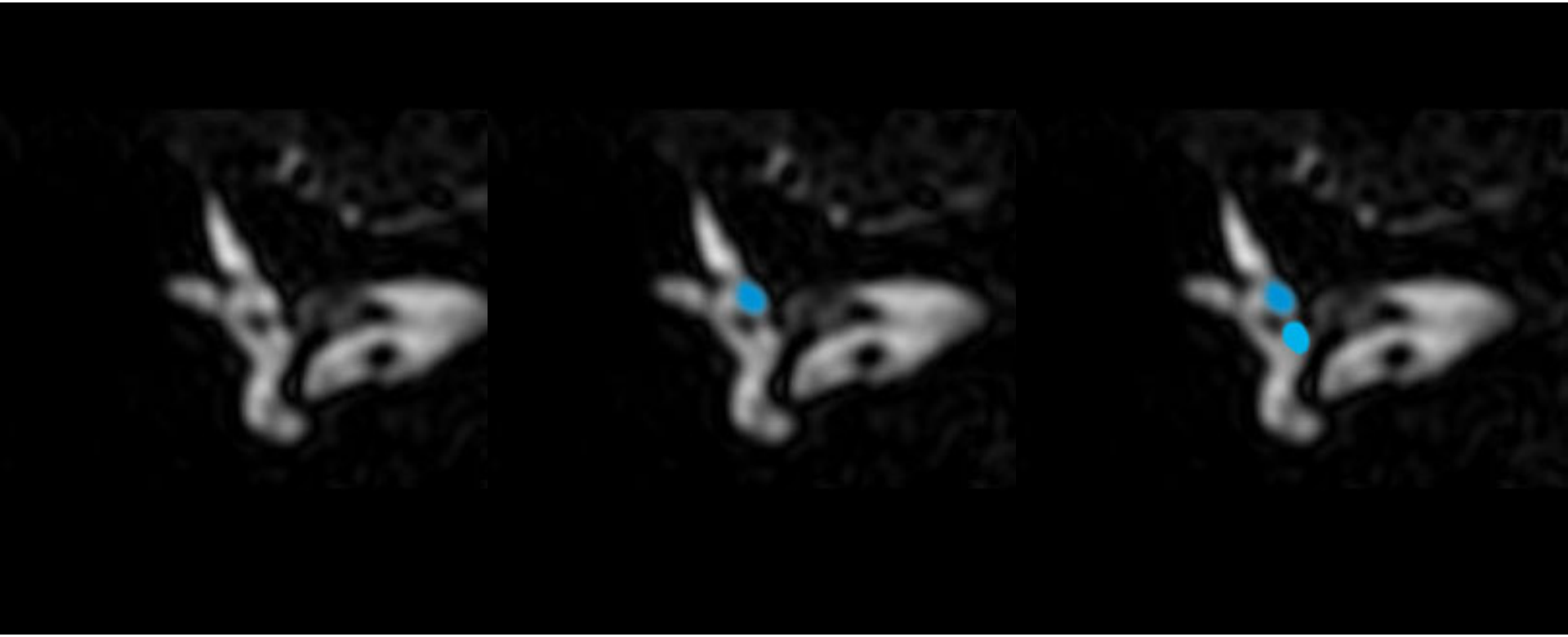

utricule

utricule + saccule

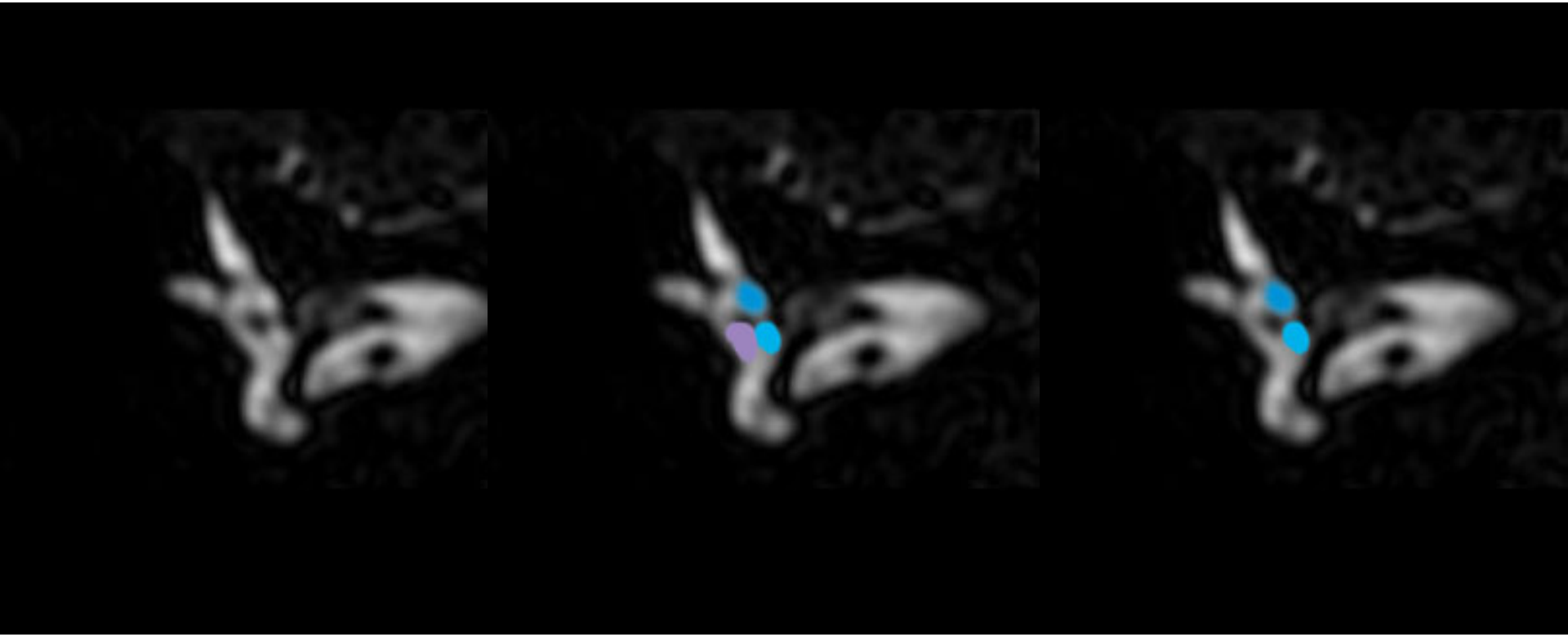

utricule + saccule

+ périlymphe

utricule + saccule

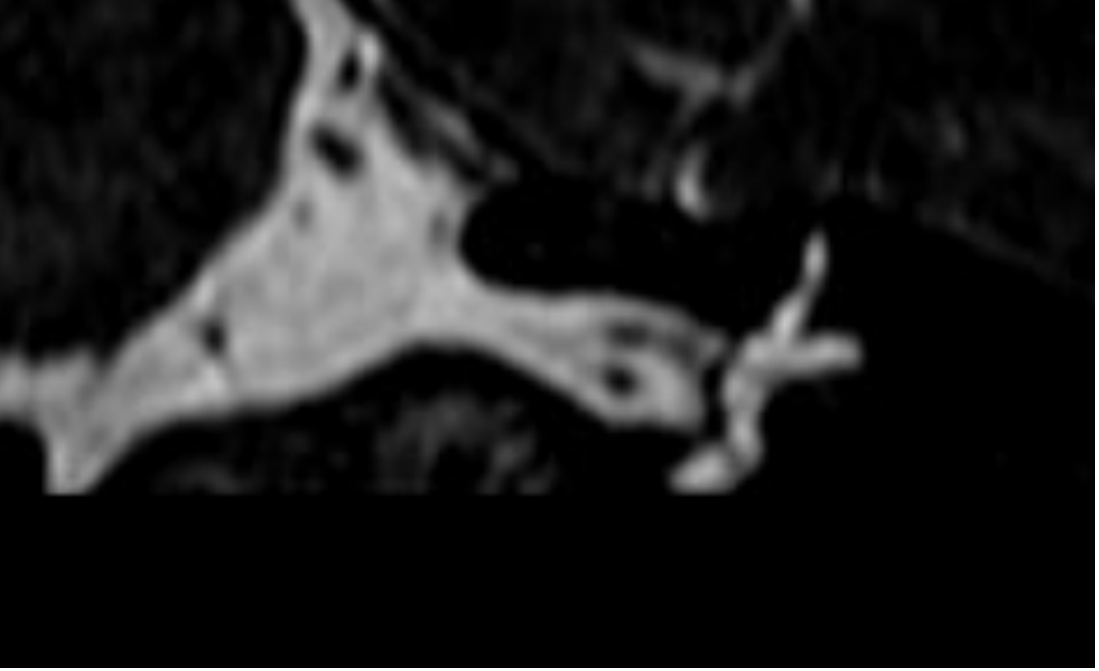

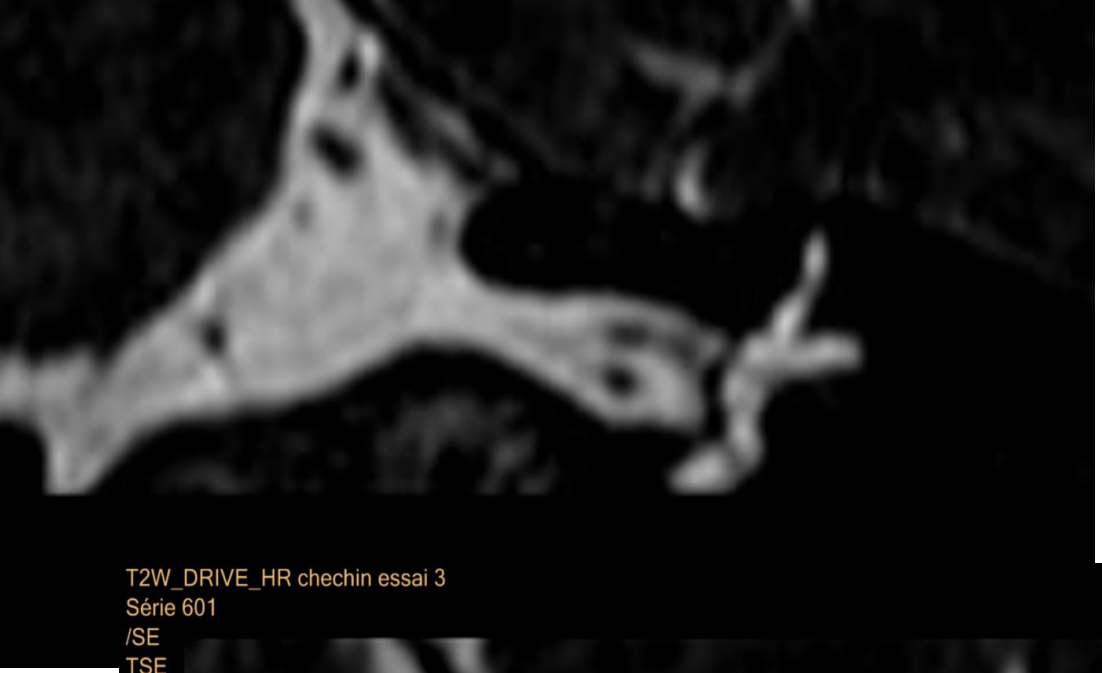

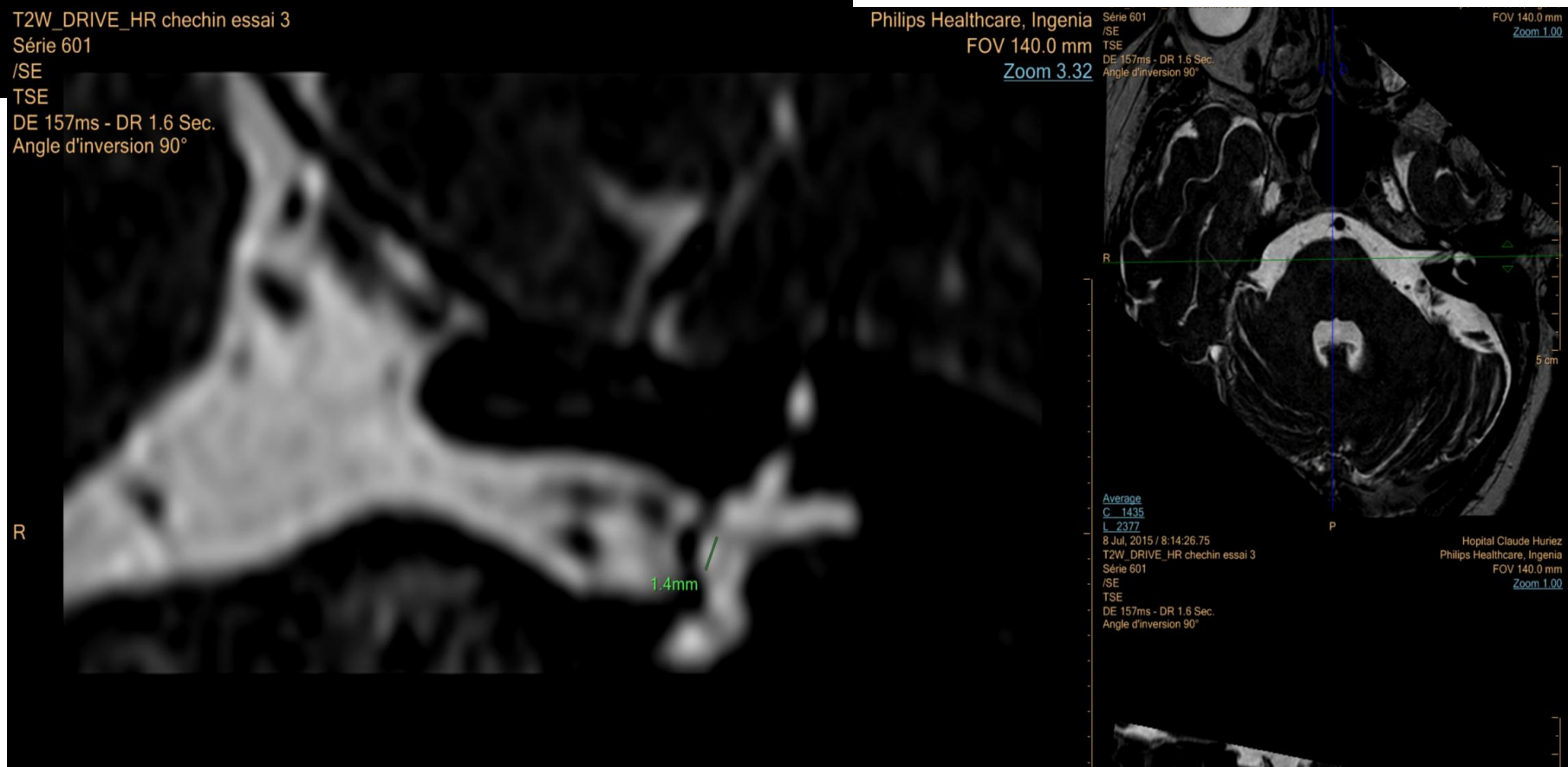
T2W_DRIVE_HR chechin essai 3
Série 601
/SE
TSE
DE 157ms - DR 1.6 Sec.
Angle d'inversion 90°
Philips Healthcare, Ingenia
FOV 140.0 mm
Zoom 3.32
R
1.4mm
Série 601
/SE
TSE
DE 157ms - DR 1.6 Sec.
Angle d'inversion 90°
FOV 140.0 mm
Zoom 1.00
R
5 cm
P
Average
C 1435
L 2377
8 Jul, 2015 / 8:14:26.75
T2W_DRIVE_HR chechin essai 3
Série 601
/SE
TSE
DE 157ms - DR 1.6 Sec.
Angle d'inversion 90°
Hopital Claude Huriez
Philips Healthcare, Ingenia
FOV 140.0 mm
Zoom 1.00

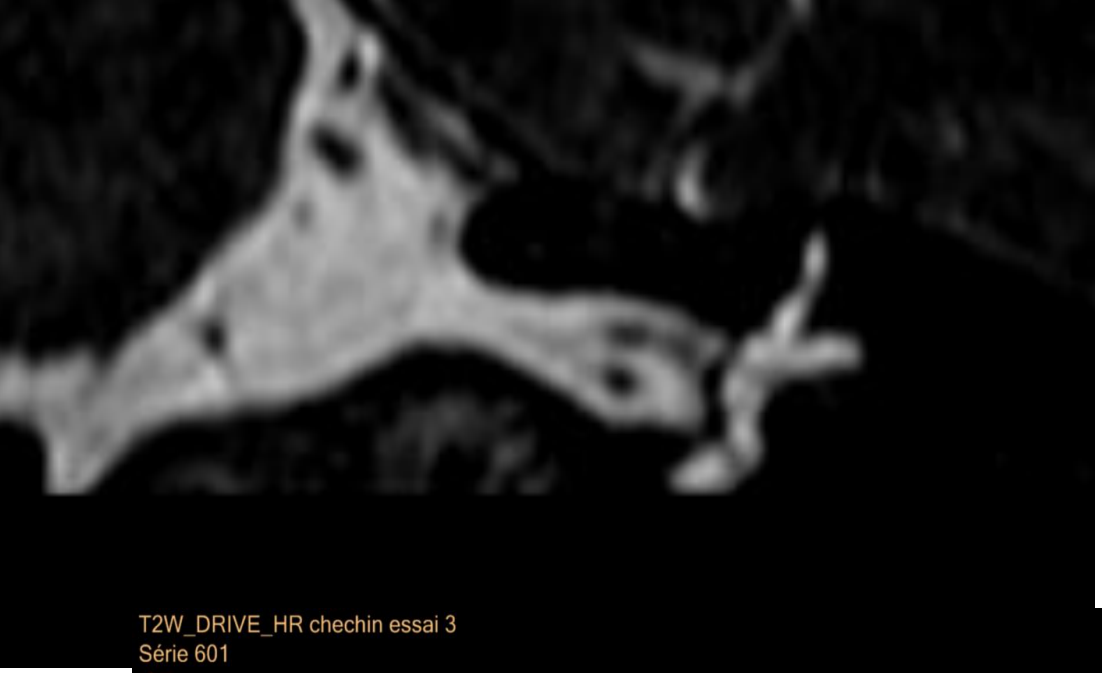

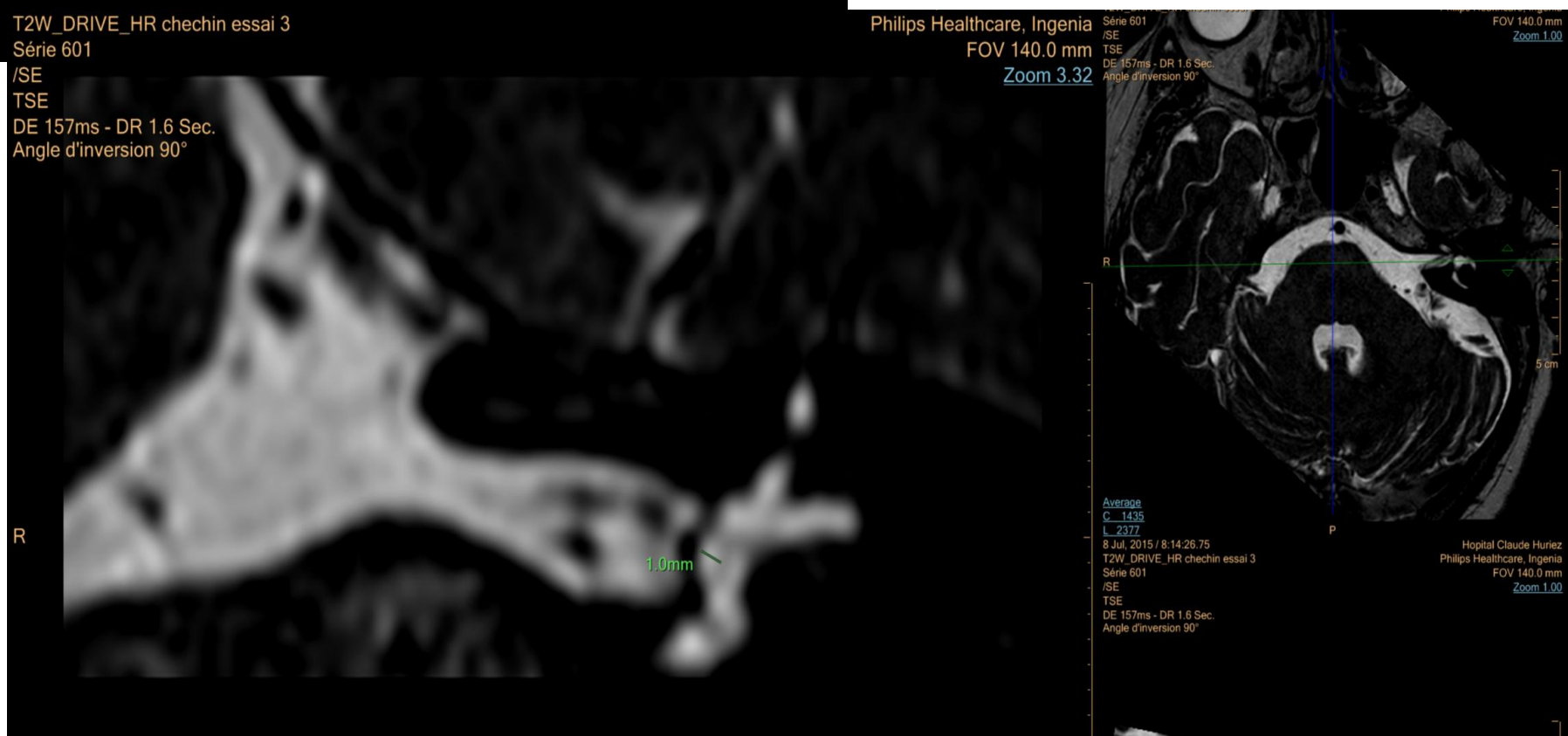
T2W_DRIVE_HR chechin essai 3
Série 601
/SE
TSE
DE 157ms - DR 1.6 Sec.
Angle d'inversion 90°
Philips Healthcare, Ingenia
FOV 140.0 mm
Zoom 3.32
R
1.0mm
Série 601
/SE
TSE
DE 157ms - DR 1.6 Sec.
Angle d'inversion 90°
FOV 140.0 mm
Zoom 1.00
R
P
5 cm
Average
C 1435
L 2377
8 Jul, 2015 / 8:14:26.75
T2W_DRIVE_HR chechin essai 3
Série 601
/SE
TSE
DE 157ms - DR 1.6 Sec.
Angle d'inversion 90°
Hopital Claude Huriez
Philips Healthcare, Ingenia
FOV 140.0 mm
Zoom 1.00

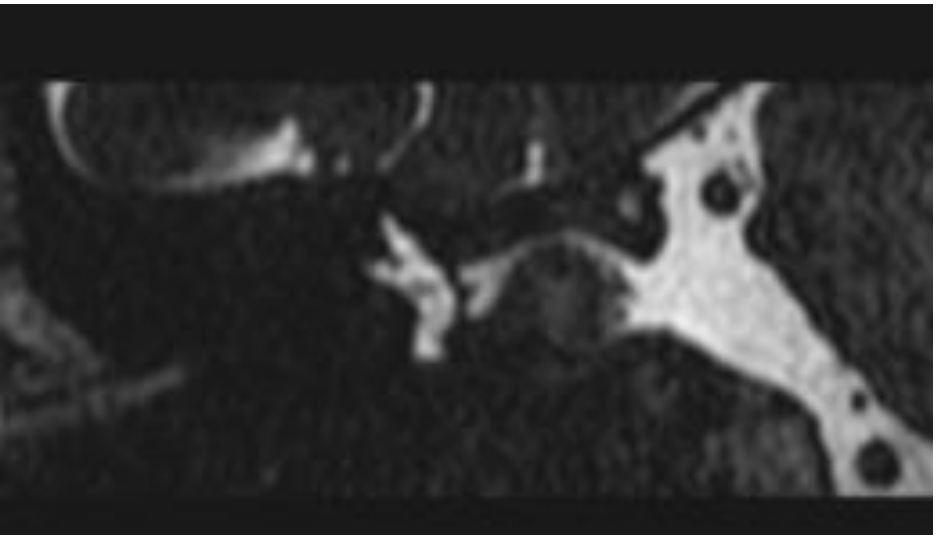

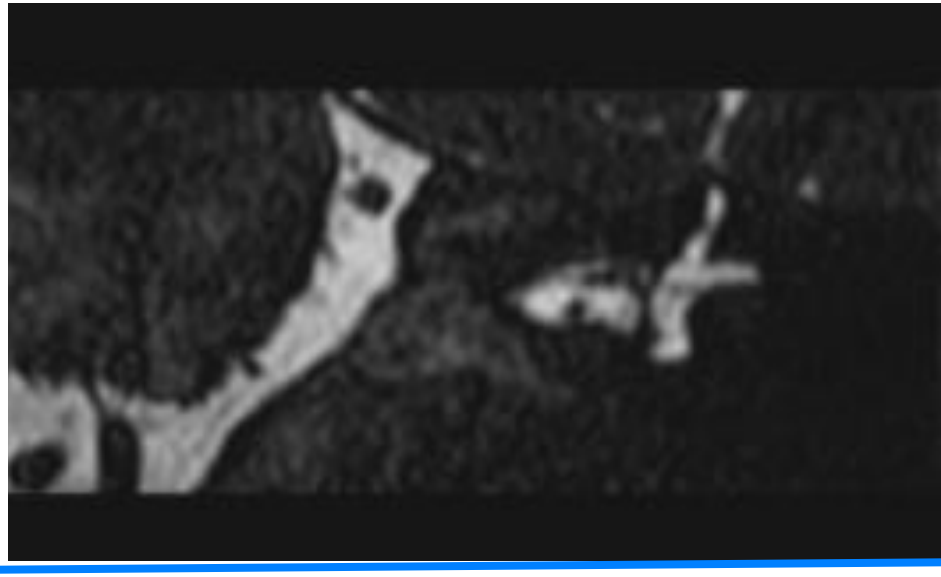

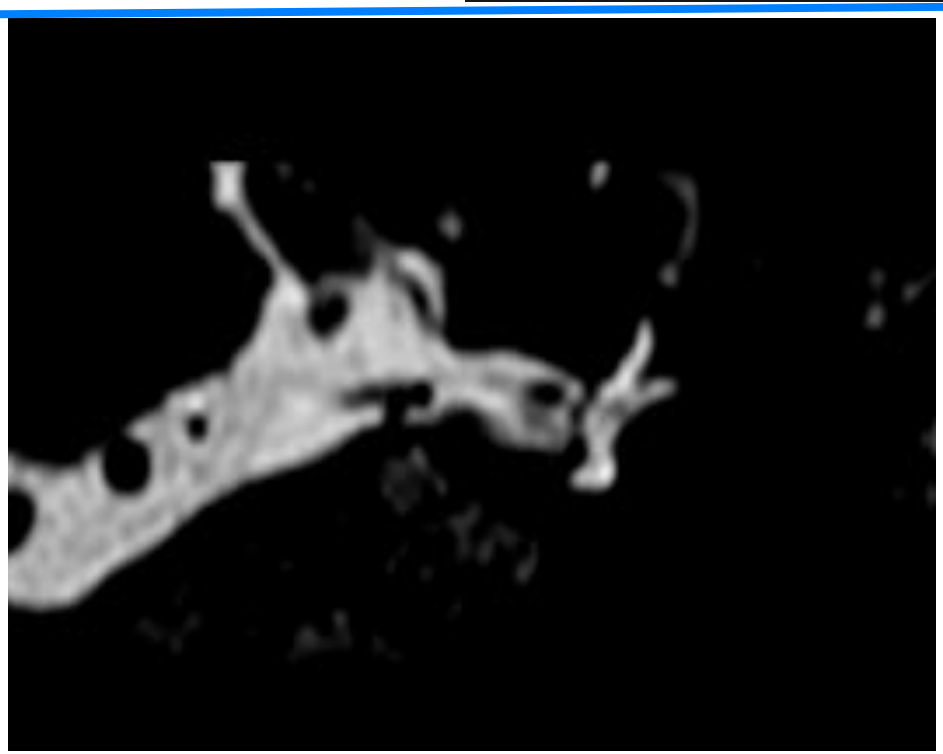

bébé de 15 mois (bilan pré implant cochléaire)

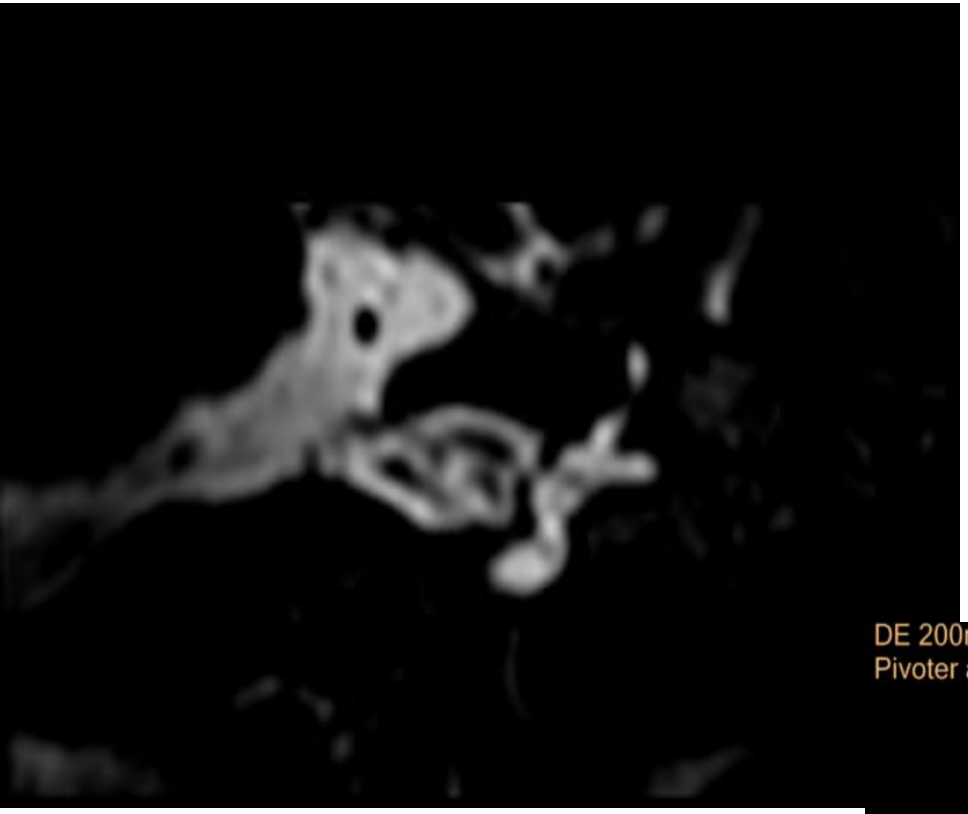

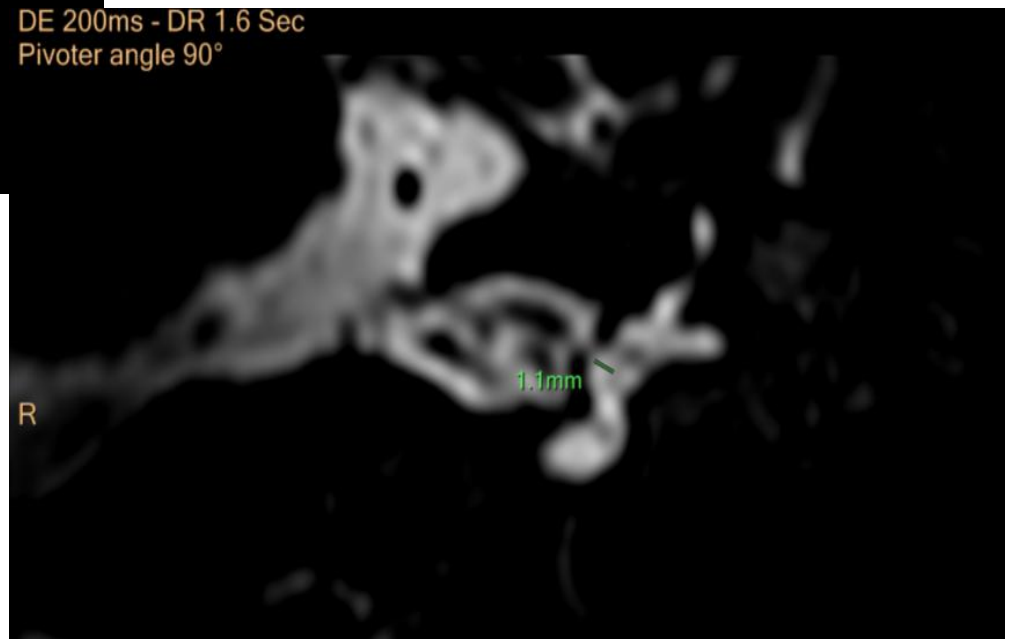

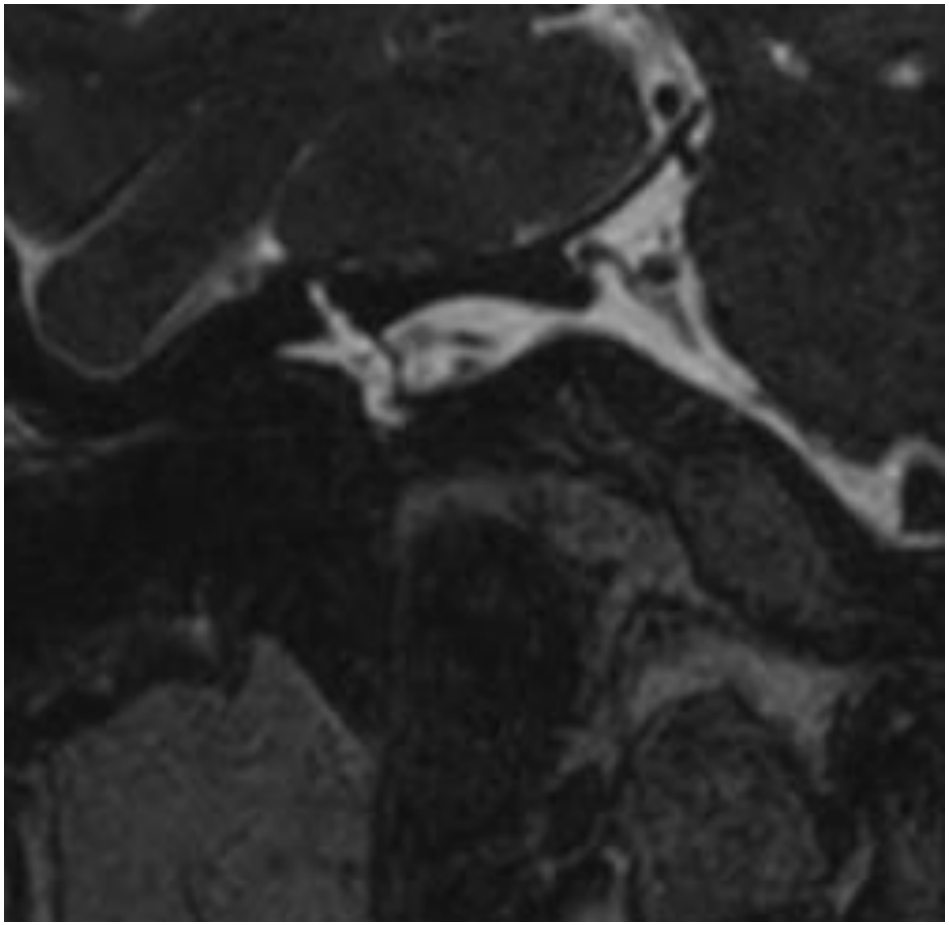

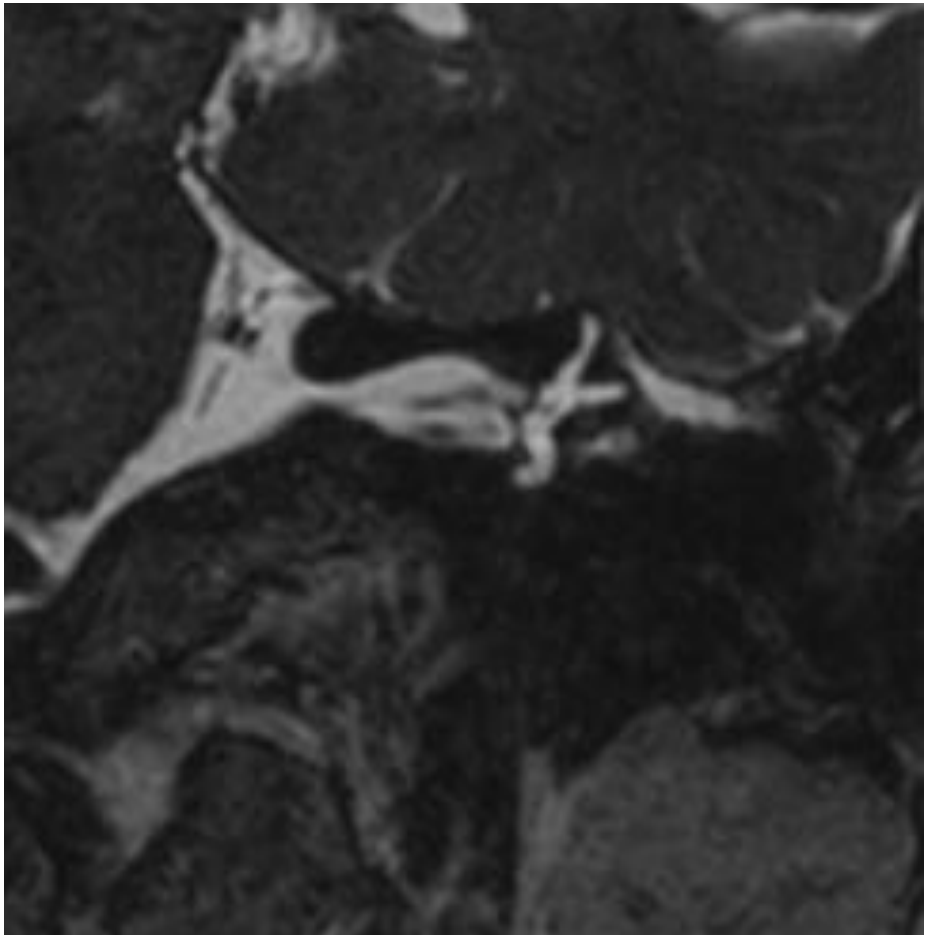

acquisition coronal direct

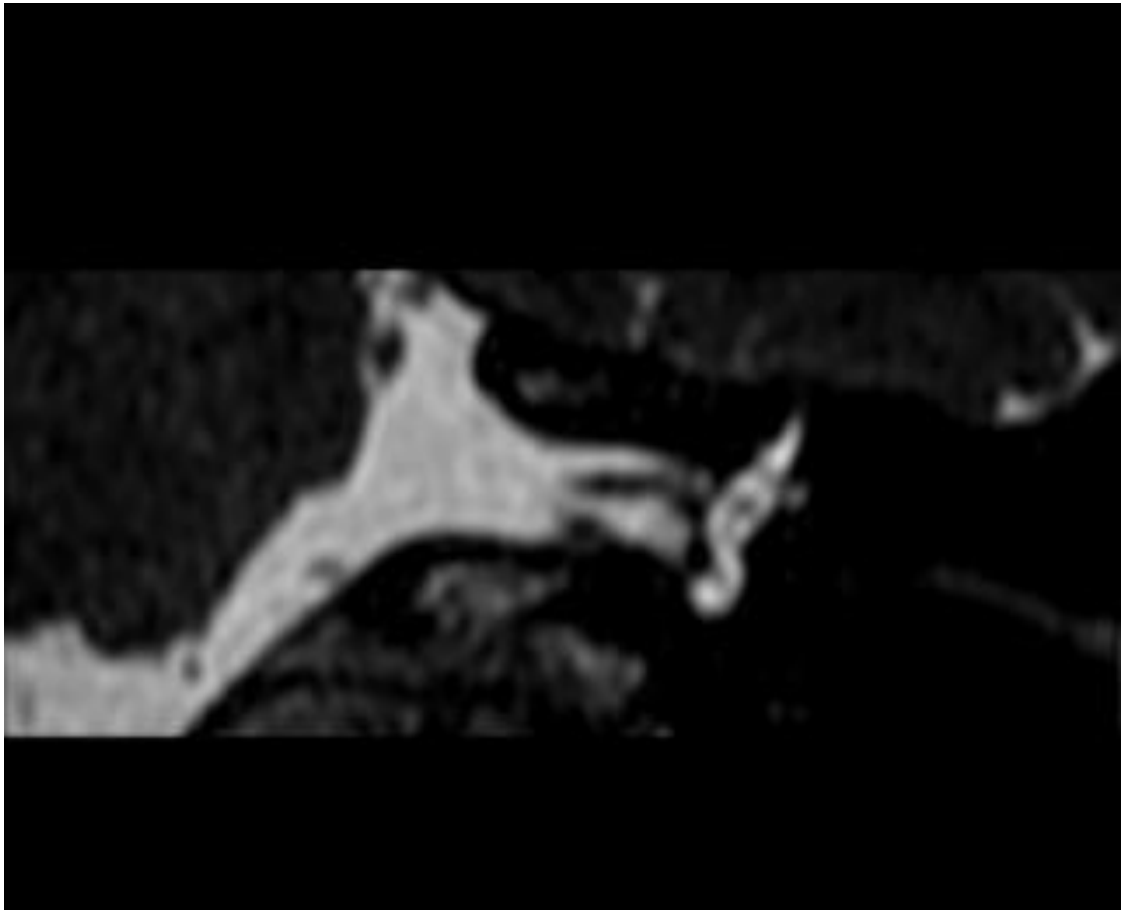

anatomie oreille interne – endolymphe à 1.5 T

- **anatomie de l'endolymphe possible à 1.5 T**

saccule normal

– transverse moy 1,2 mm **tjs < 1,5 mm**

– coronal moy 1,3 mm **tjs < 1,6 mm**

séquence 3D HR T2 oreille interne

anatomie Oreille interne – endolymphe à 1.5 T

- **anatomie de l'endolymphe possible à 1.5 T**

Drive HR sur Philips Ingenia 70 cm

6.10 mm

voxel 0.5 x 0.55 x 0.8

voxel reconstruit 0.27 x 0.27 x 0.40

60 coupes

pas de sense

antenne tête classique canaux (pas d'antenne de surface)

TSE multishot 45

TR 1550

TE 156

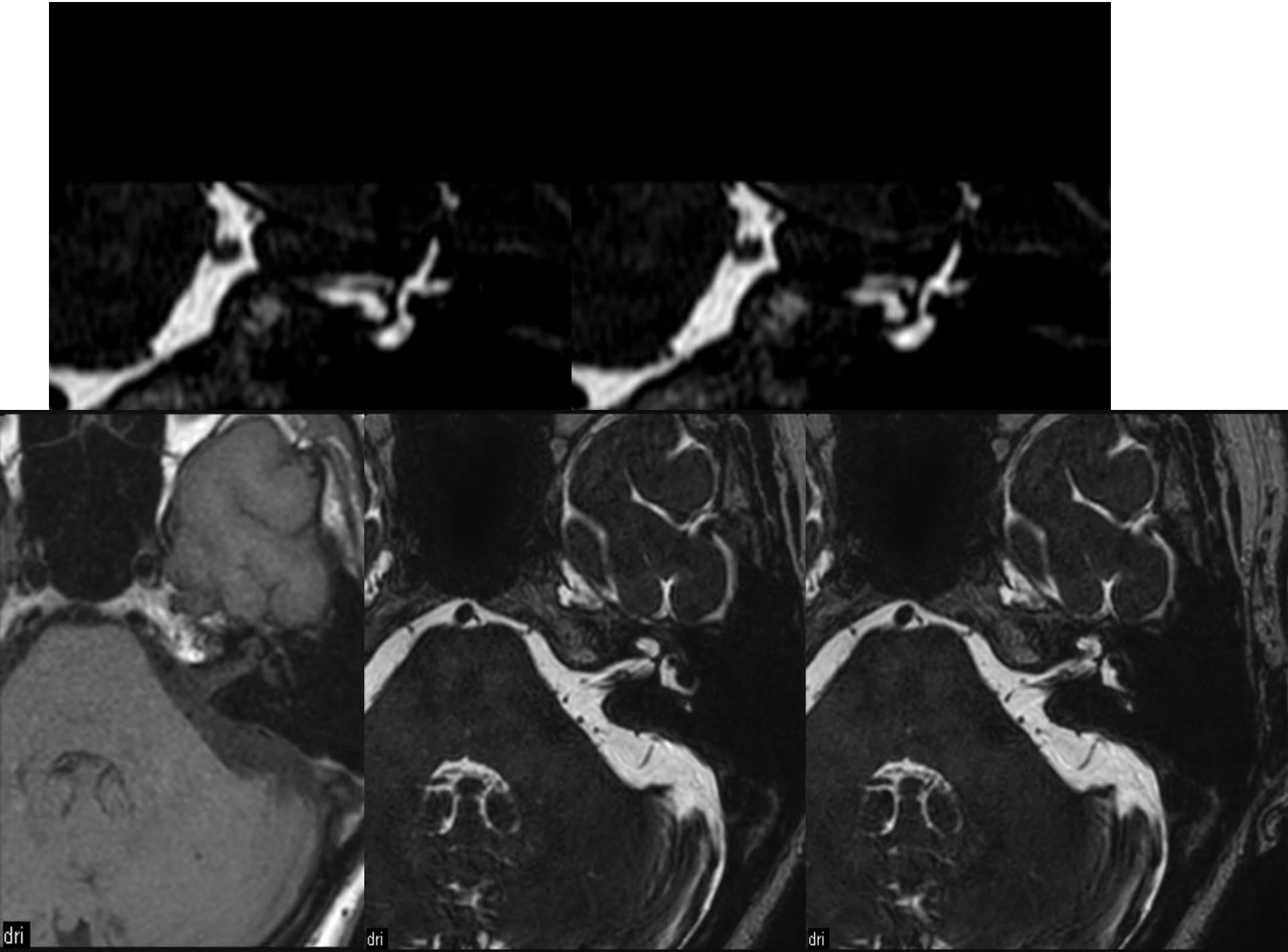
dri
dri
dri

l’hydrops à 1.5 T

– analyse anatomique du saccule et de sa taille

Patient de 48 ans
clinique typique de Maladie de Menière gauche

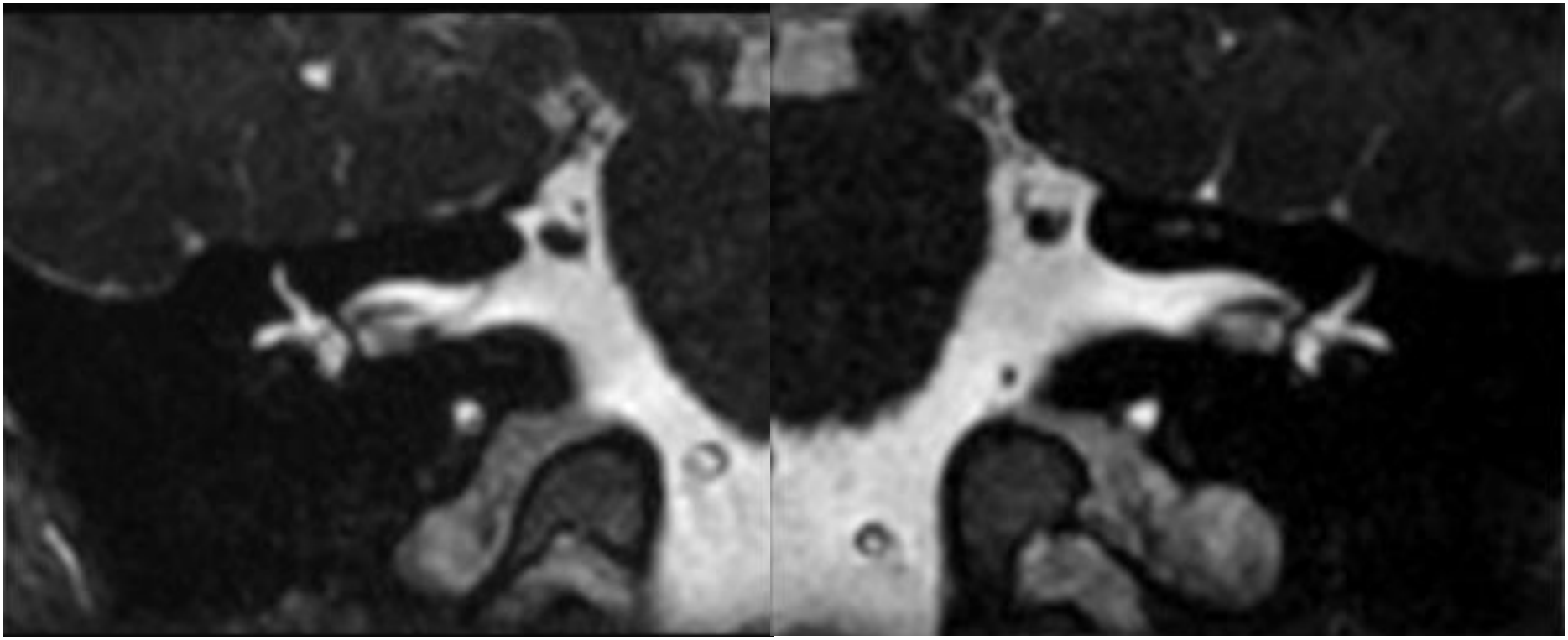

Patient de 48 ans
clinique typique de Maladie de Menière gauche

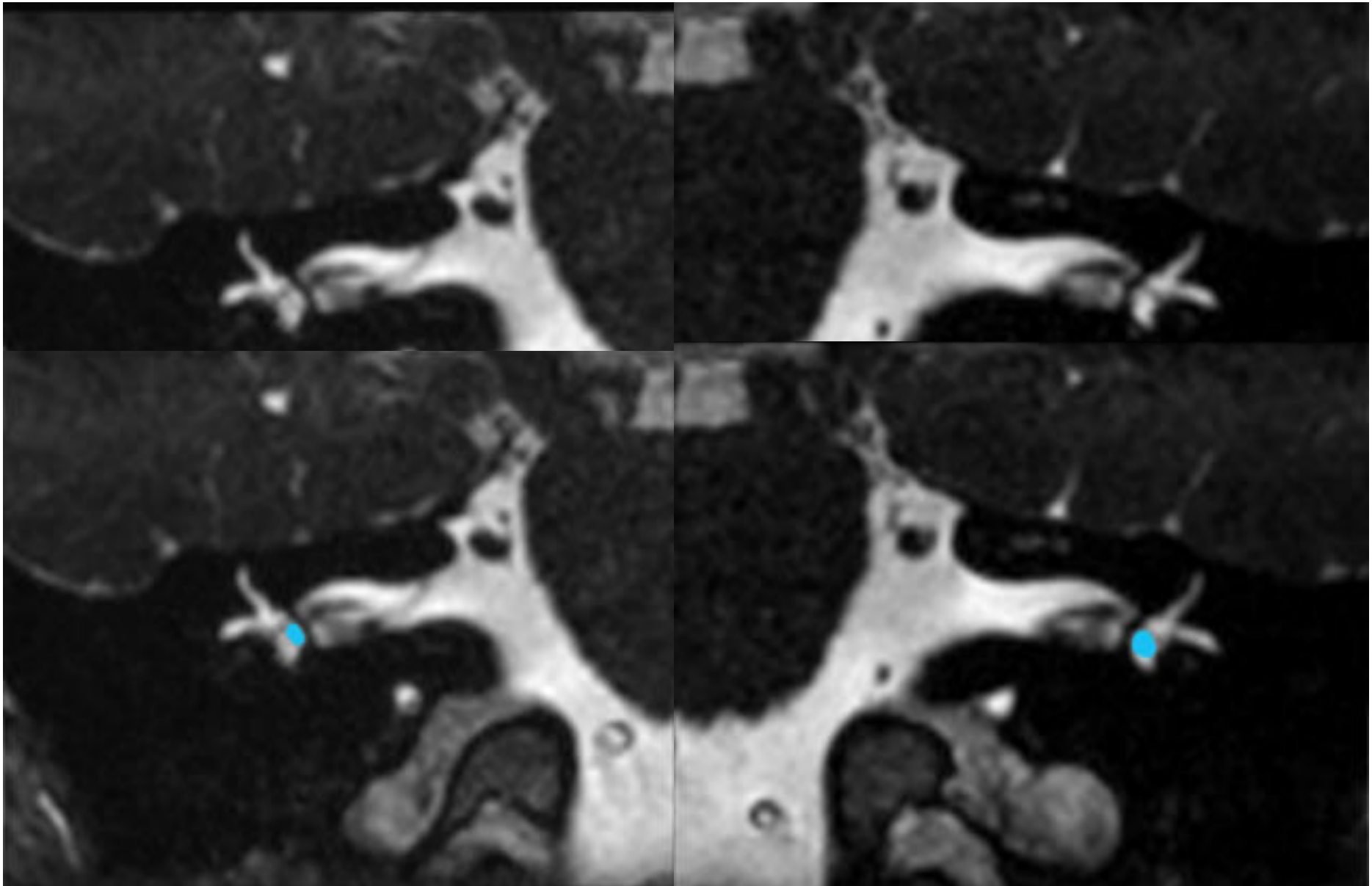

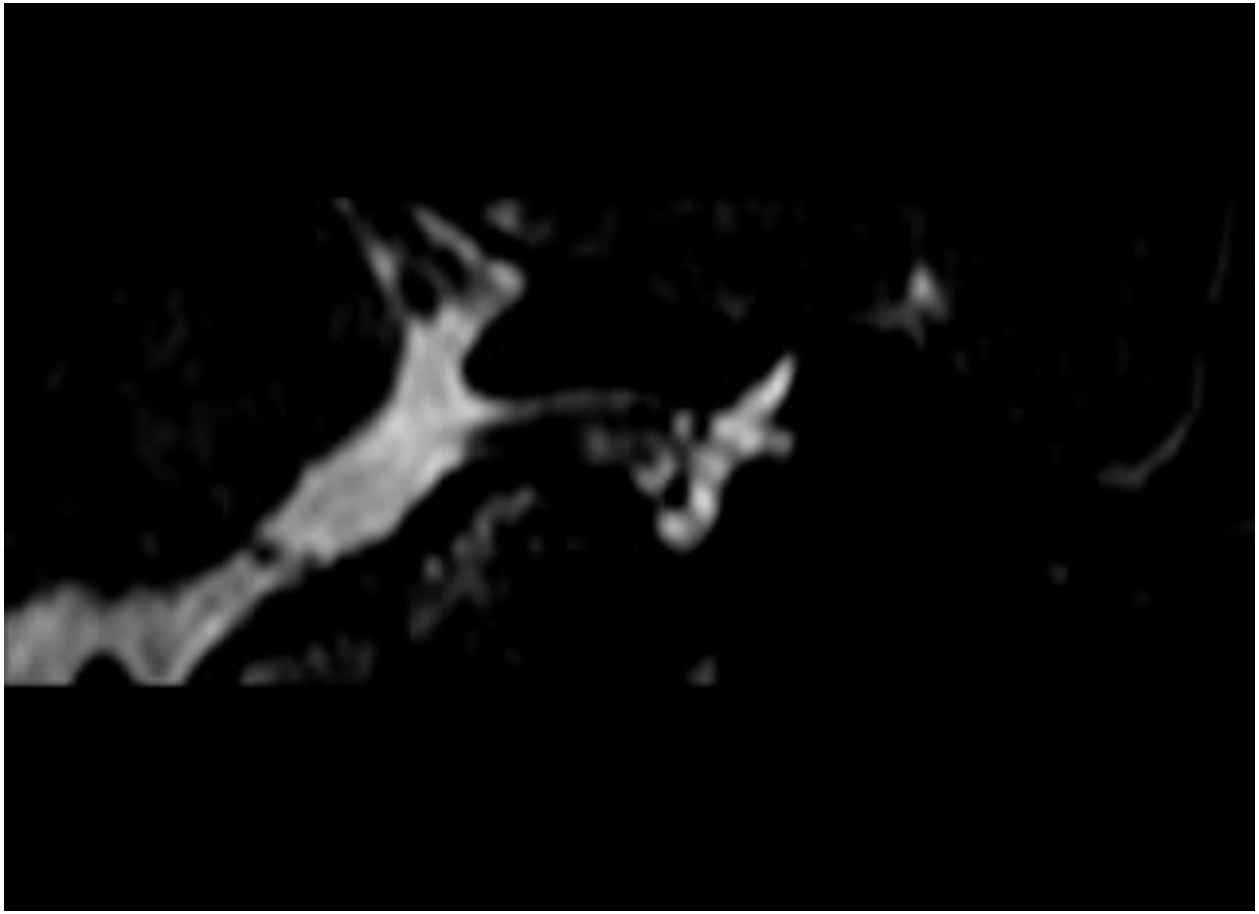

Visualisation de l'endolymphe

- **Séparation entre endolymphe et périlymphe**

Equipe de Naganawa and Nakashima

Eur Radiol
DOI 10.1007/s00330-008-0854-8

HEAD AND NECK

2007

Shinji Naganawa
Hiroko Satake
Minako Kawamura
Hiroshi Fukatsu
Michihiko Sone
Tsutomu Nakashima

Separate visualization of endolymphatic space, perilymphatic space and bone by a single pulse sequence; 3D-inversion recovery imaging utilizing real reconstruction after intratympanic Gd-DTPA administration at 3 Tesla

Visualisation de l'endolymphe

- **Séparation entre endolymphe et périlymphe**

Equipe de Naganawa and Nakashima

Eur Radiol
DOI 10.1007/s00330-008-0854-8

HEAD AND NECK

2007007

Shinji Naganawa
Hiroko Satake
Minako Kawamura
Hiroshi Fukatsu
Michihiko Sone
Tsutomu Nakashima

Separate visualization of endolymphatic space, perilymphatic space and bone by a single pulse sequence; 3D-inversion recovery imaging utilizing real reconstruction after intratympanic Gd-DTPA administration at 3 Tesla

Visualisation del'endolymphe

- **Séparation entre endolymphe et périlymphe**

Equipe de Naganawa and Nakashima

Acta Otolaryngol Suppl. 2009 Feb;(560):5-8. doi: 10.1080/00016480902729827.

Grading of endolymphatic hydrops using magnetic resonance imaging.

Nakashima T[1], Naganawa S, Pyykko I, Gibson WP, Sone M, Nakata S, Teranishi M.

Author information

Abstract

CONCLUSION: Grading of endolymphatic hydrops in the vestibule and the cochlea using magnetic resonance imaging (MRI) is proposed (2008 Nagoya scale).

OBJECTIVE: To standardize the evaluation of endolymphatic hydrops in both the vestibule and the cochlea using MRI.

PATIENTS AND METHODS: The endolymphatic space was evaluated after intratympanic gadolinium injection using three-dimensional fluid attenuated (3D-FLAIR) MRI and three-dimensional real inversion recovery (3D-real IR) MRI.

RESULTS: A simple three-stage grading system was acceptable for hydrops in both the vestibule and the cochlea: none, mild, and significant. In the vestibule, the grading was determined by the ratio of the area of endolymphatic space to the vestibular fluid space (sum of the endolymphatic and perilymphatic spaces). Patients with no hydrops have a ratio of one-third or less, those with mild hydrops have between one-third and a half, and those with significant hydrops have a ratio of more than 50%. In the cochlea, patients classified as having no hydrops show no displacement of Reissner's membrane; those with mild hydrops show displacement of Reissner's membrane but the area of the endolymphatic space does not exceed the area of the scala vestibuli; and in those with significant hydrops the area of the endolymphatic space exceeds the area of the scala vestibuli.

Visualisation de l'endolymphe

- **Séparation entre endolymphe et périlymphe**

  Equipe de Naganawa and Nakashima

séquence 3D HR FLAIR
IRM 3T

4 heures après injection d'une simple dose de gadolinium

But: séparer et visualiser séparément
liquides endolymphatiques -
liquides péri lyphatiques

Visualisation de l'endolymphe

- **Séparation entre endolymphe et périlymphe**

Equipe de Naganawa and I

séquence 3D HR FLAIR
IRM 3T

4 heures après injection d'une simple dose de gadolinium

But: séparer et visualiser séparément
liquides endolymphatiques -
liquides péri lyphatiques

1. Naganawa S, Kawai H, Sone M, Nakashima T. Increased sensitivity to low concentration gadolinium contrast by optimized heavily T_2-weighted 3D-FLAIR to visualize endolymphatic space. Magn Reson Med Sci 2010; 9:73–80.
2. Naganawa S, Yamazaki M, Kawai H, Bokura K, Sone M, Nakashima T. Visualization of endolymphatic hydrops in Ménière's disease with single-dose intravenous gadolinium-based contrast media using heavily T_2-weighted 3D-FLAIR. Magn Reson Med Sci 2010; 9:237–242.
3. Naganawa S, Yamazaki M, Kawai H, Sone M, Nakashima T. Contrast enhancement of the anterior eye segment and subarachnoid space: detection in the normal state by heavily T_2-weighted 3D FLAIR. Magn Reson Med Sci 2011; 10:193–199.
4. Nakashima T, Naganawa S, Sugiura M, et al. Visualization of endolymphatic hydrops in patients with Ménière's disease. Laryngoscope 2007; 117:415–420.
5. Nakashima T, Naganawa S, Teranishi M, et al. Endolymphatic hydrops revealed by intravenous gadolinium injection in patients with Ménière's disease.

Visualisation de l'endolymphe

- **Séparation entre endolymphe et périlymphe**

Equipe de Naganawa and Nakashima

séquence 3D HR FLAIR
IRM 3T

4 heures après injection d'une simple dose de gadolinium

But: séparer et visualiser séparément
liquides endolymphatiques -
liquides péri lyphatiques

Développé par Arnaud Attyé
En Europe

l'hydrops

Flair HR avec injection (4h avant) IRM 3T (Philips)

Principe

le gadolinium pénètre dans les **liquides périlymphatiques**

qui apparaitront **en hypersignal** en FLAIR HR

le gadolinium ne pénètre pas dans **les liquides endolymphatiques**

qui apparaitront **en hyposignal** (noir) en FLAIR HR

Visualisation de l'endolymphe

- **Séparation entre endolymphe et périlymphe**

Using
3D HR FLAIR sequence
3T MRI
Système de gradation de l' hydrops

3T Philips Achieva MRI 32 channel SENSE Head coil
3d FLAIR Vista
TR 1600
TE 345
TI 2300
Isotropic voxel 0.8 mm acquisition
(0.4 mm reconstruction)
SENSE technique factor 4
2 excitations
Scan time 9mn

Dans le vestibule

pas d' hydrops	**endolymphe < 33% du vestibule**
modéré	33% < endolymphe < 50%
significatif	**endolymphe > 50%**

Patient sans hydrops FLAIR HR 4h après gado

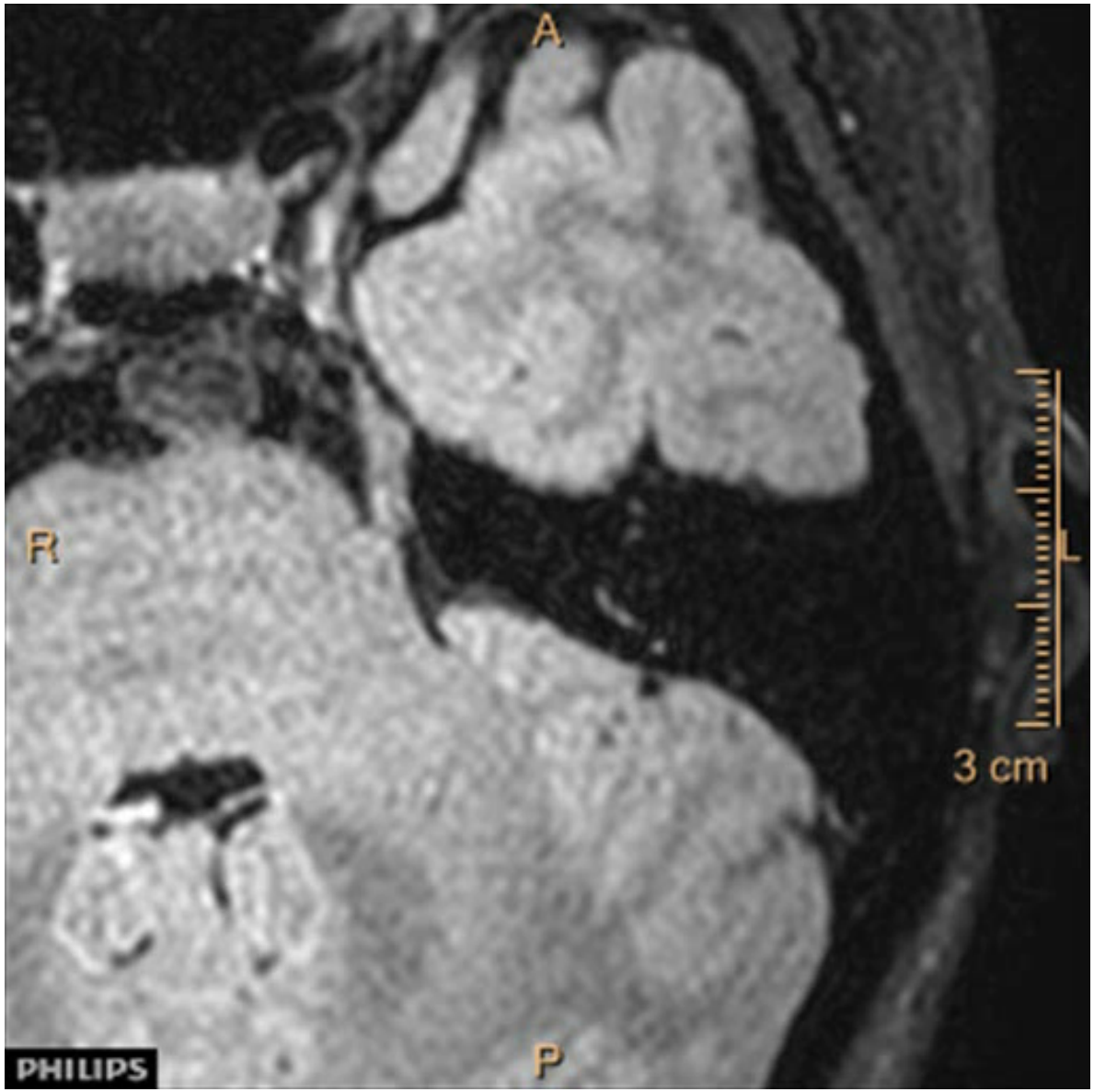

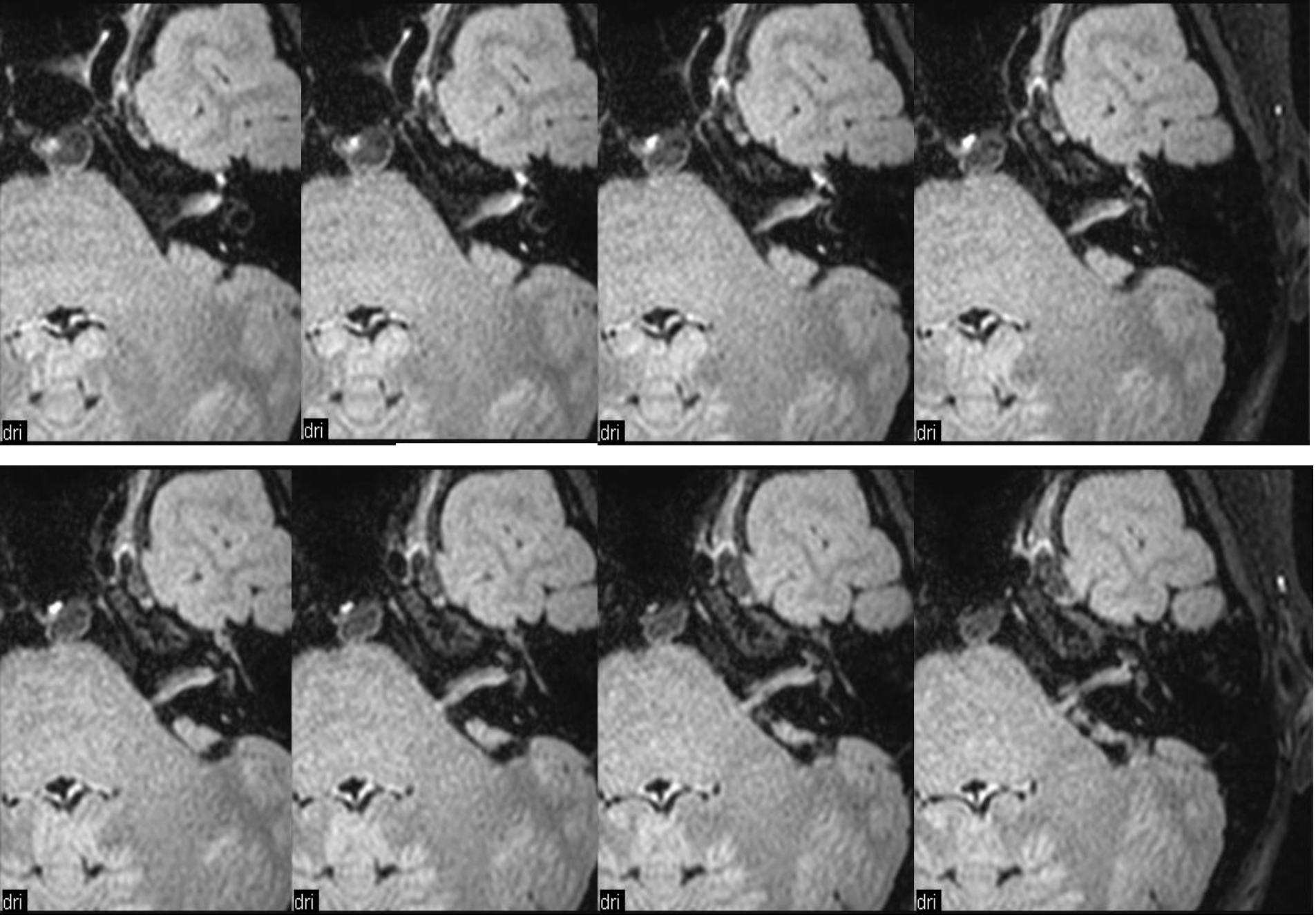
dri
dri
dri
dri
dri
dri
dri
dri

Axiale

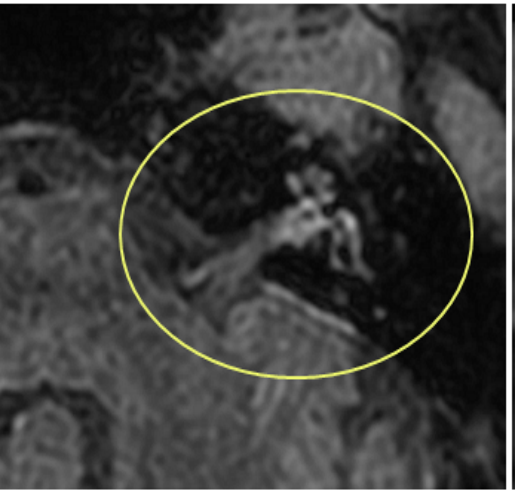

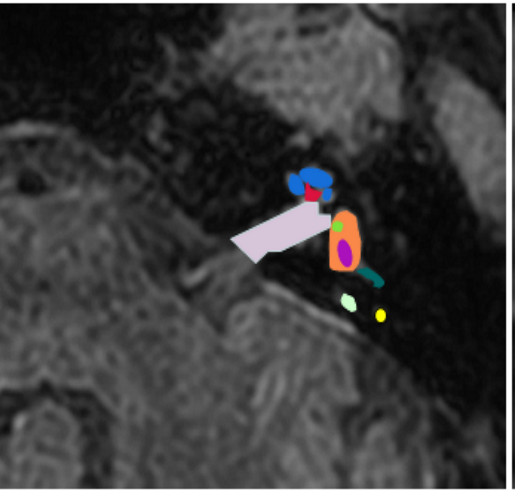

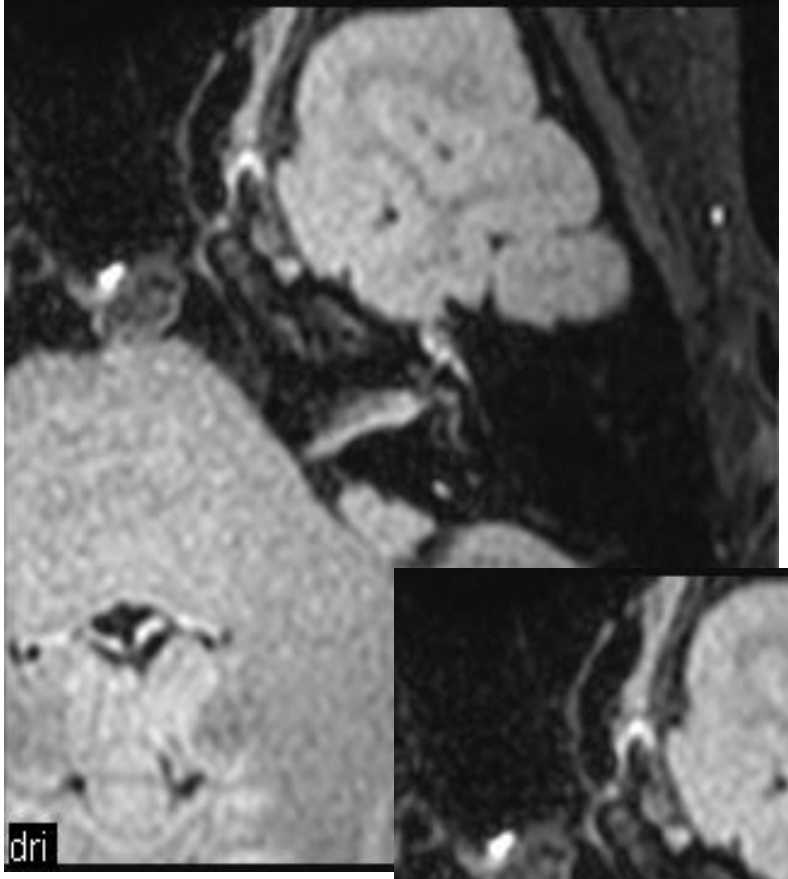

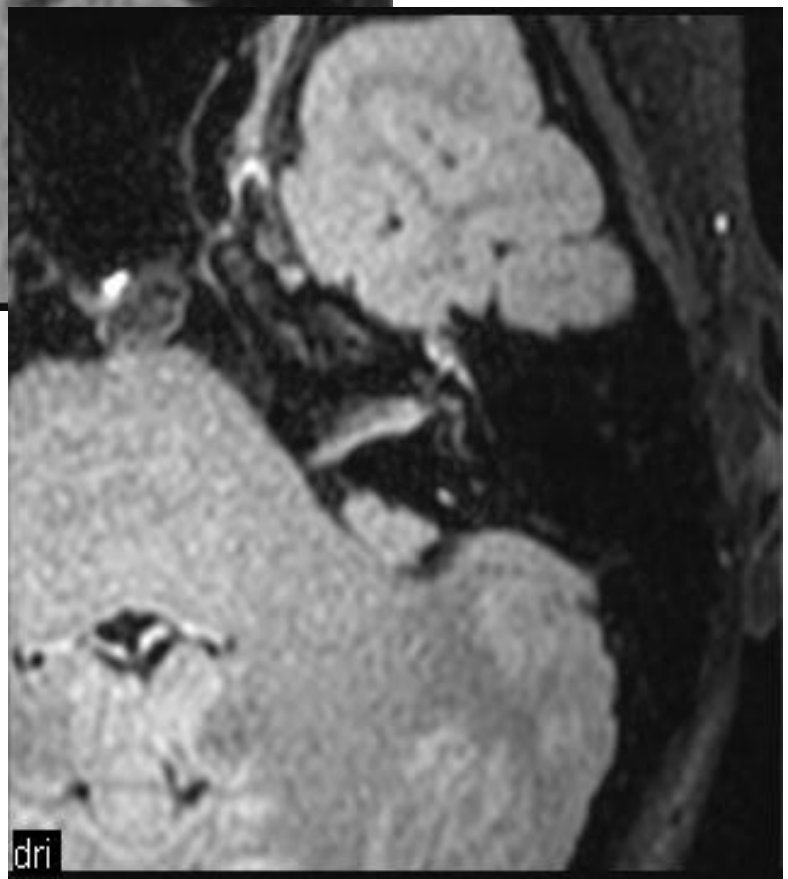

Axiale

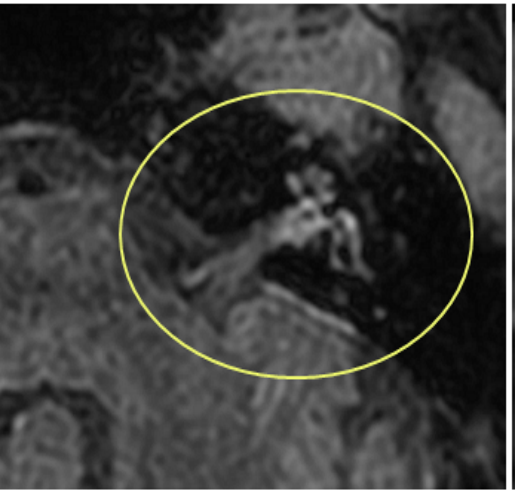

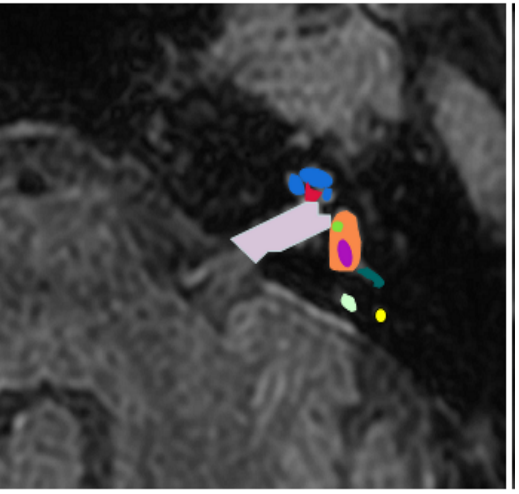

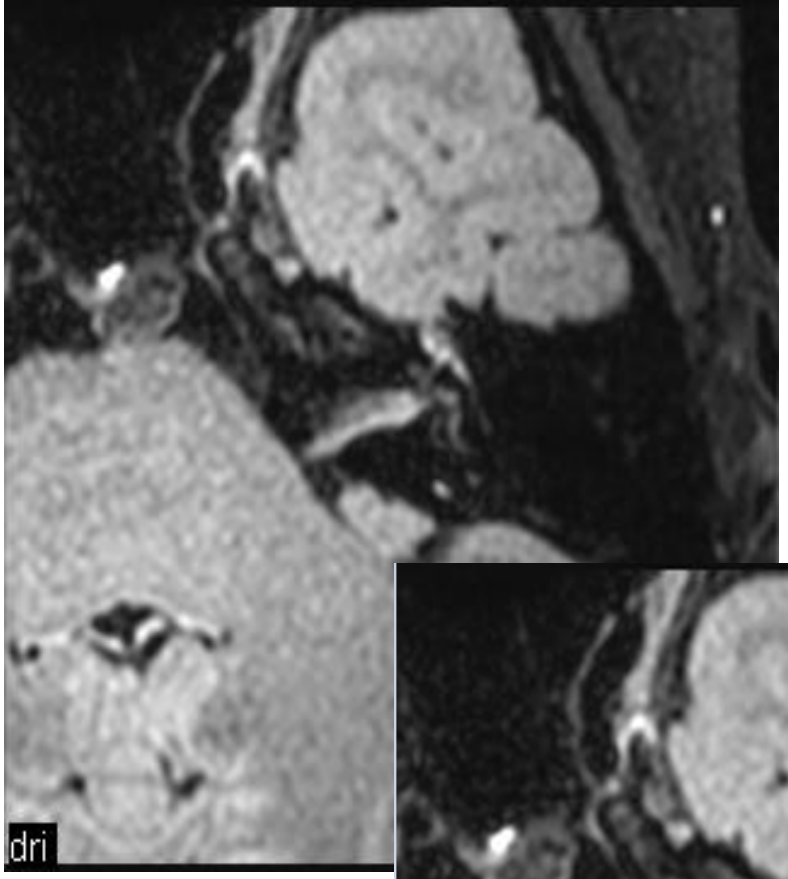

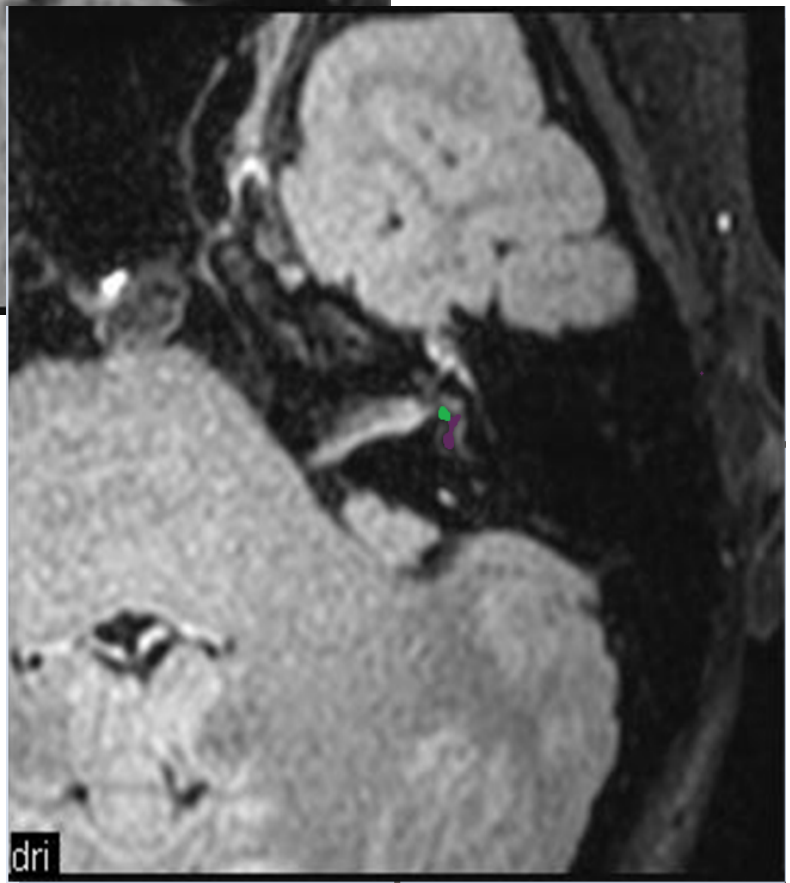

Saccule
Utricule

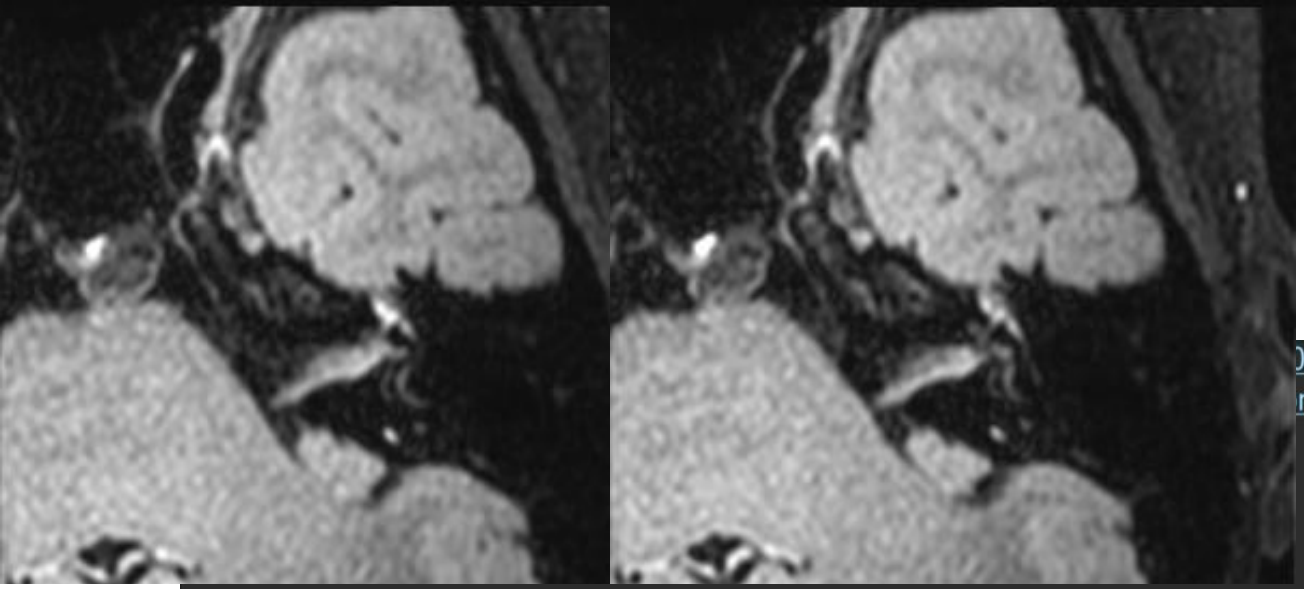

Reconstruction
Sagittale oblique

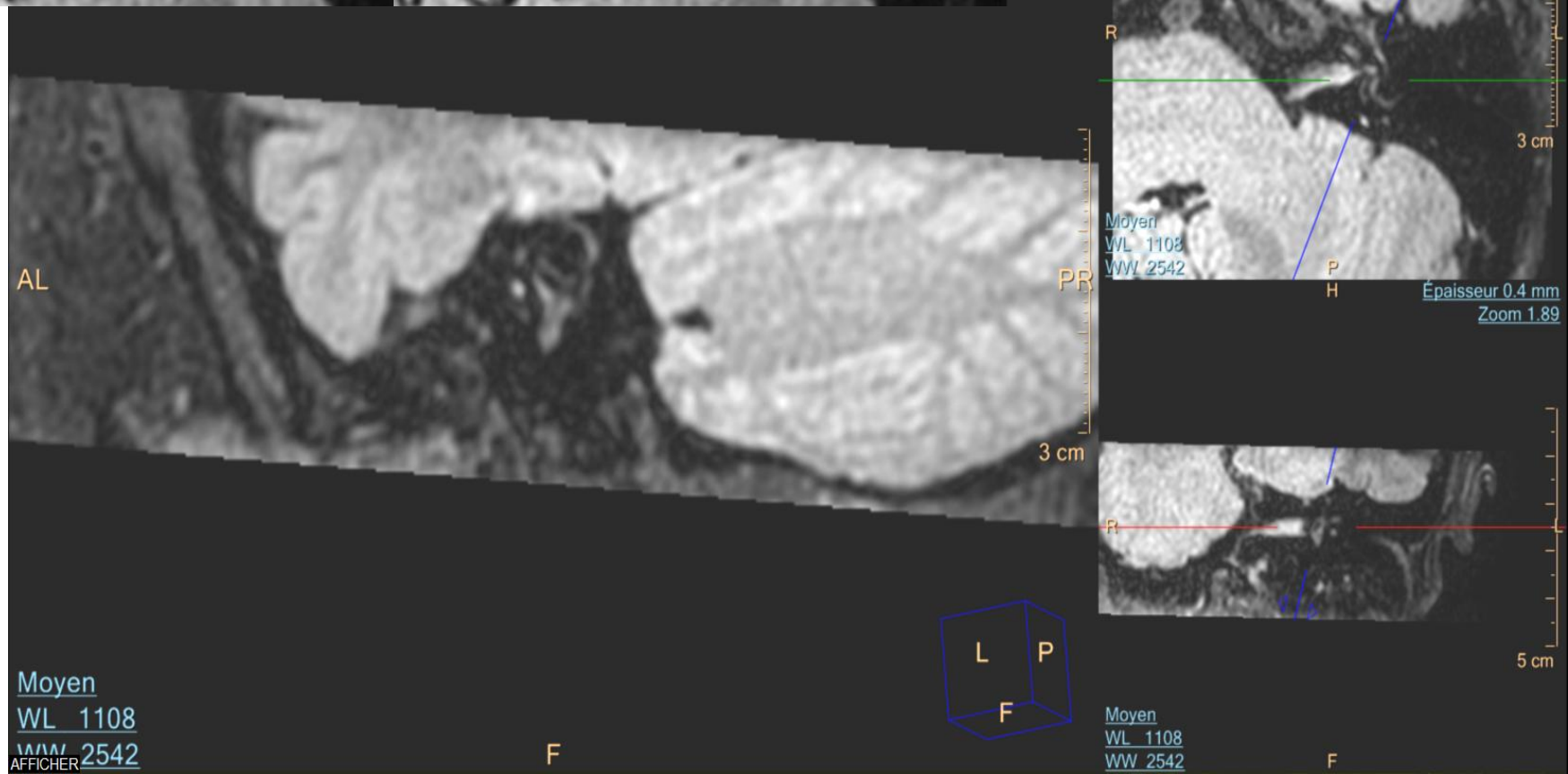

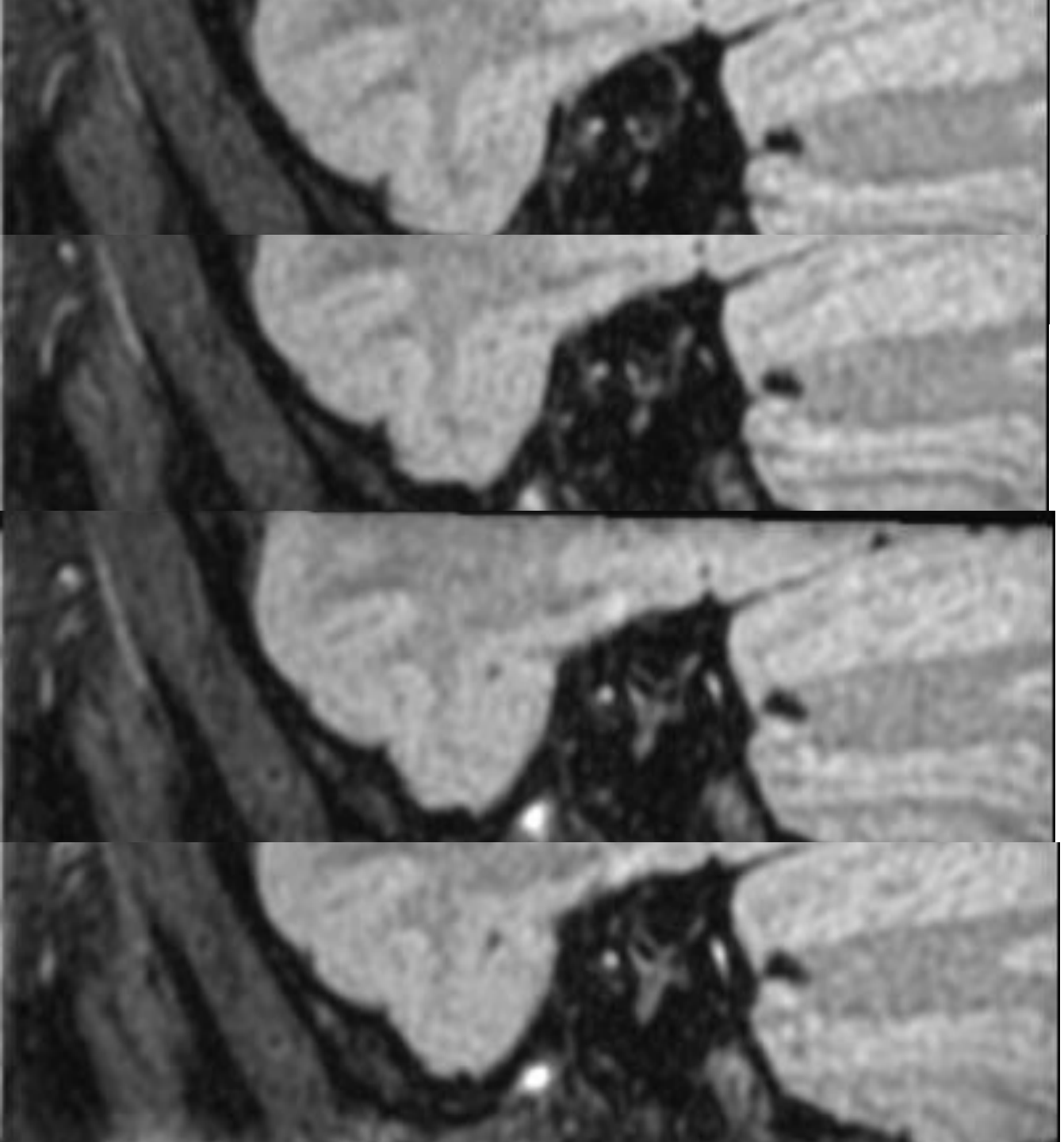

Sagittale

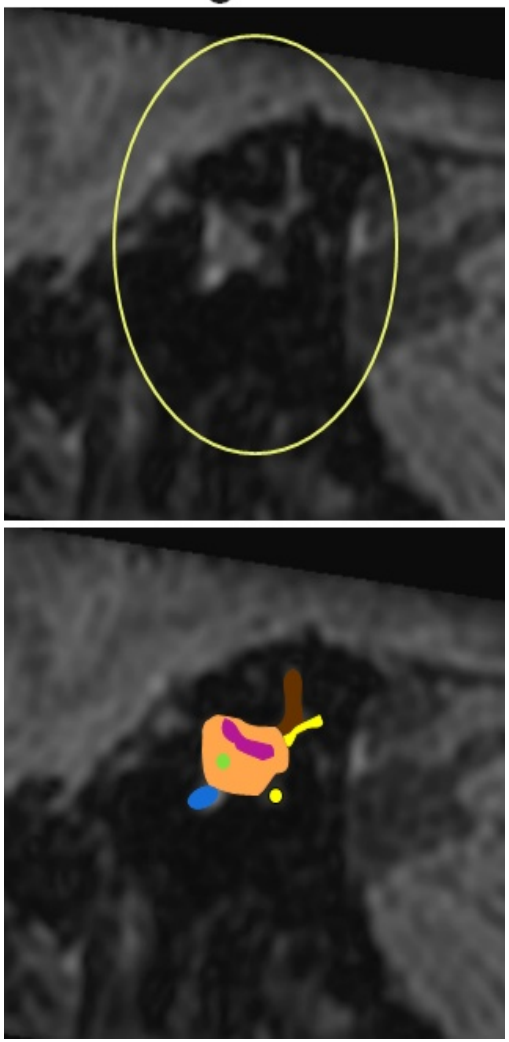

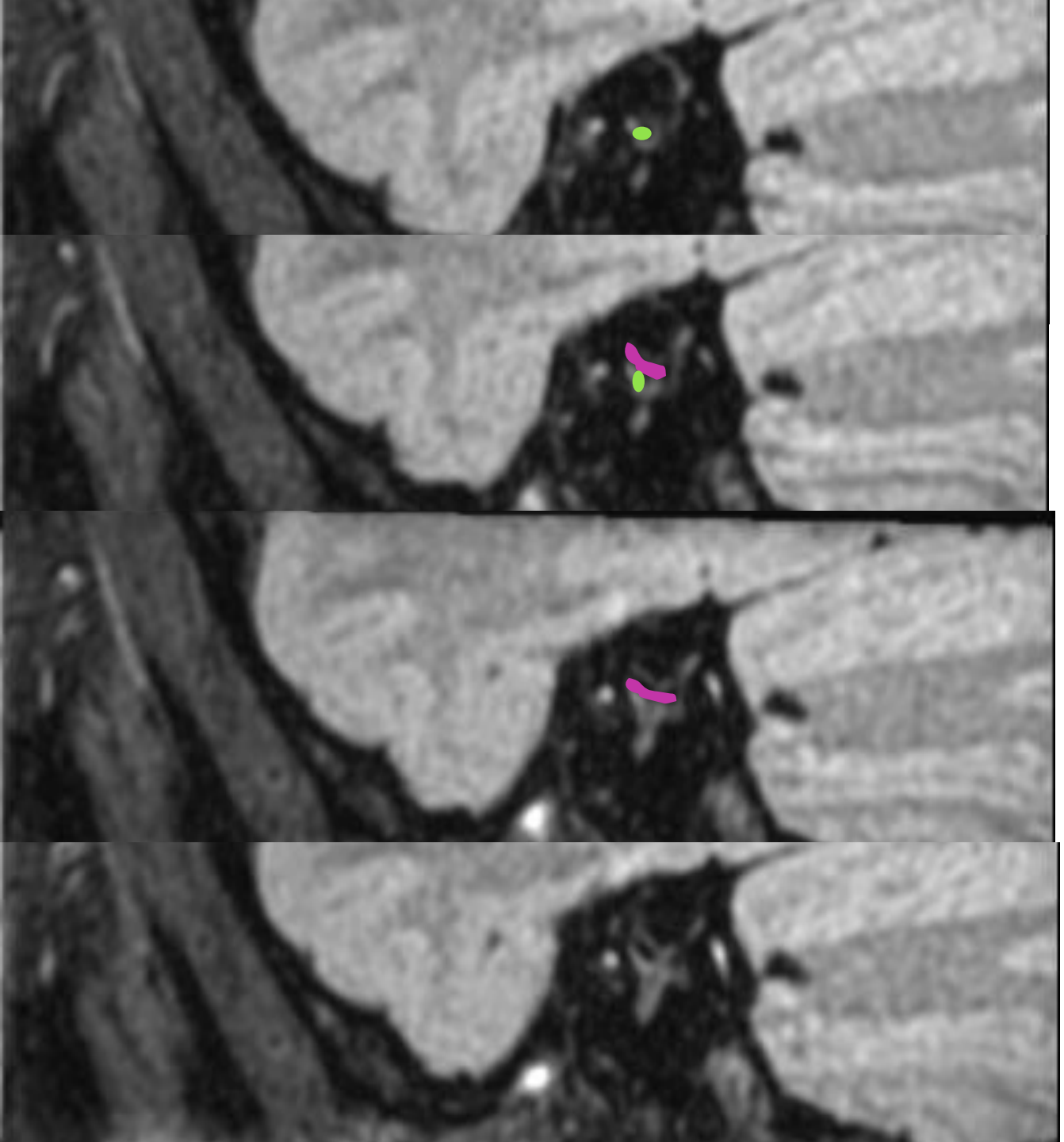

Sagittale

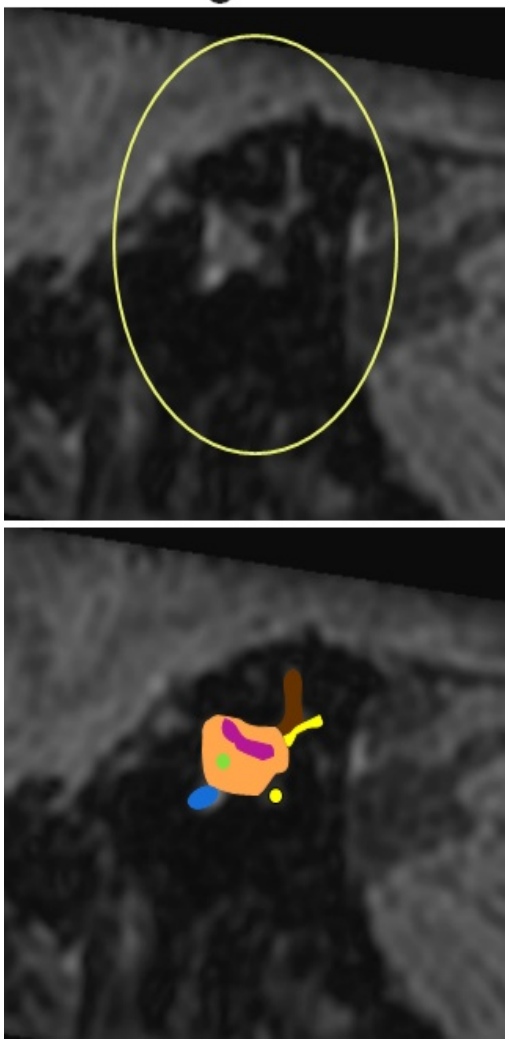

Utricule
Saccule

Coronale

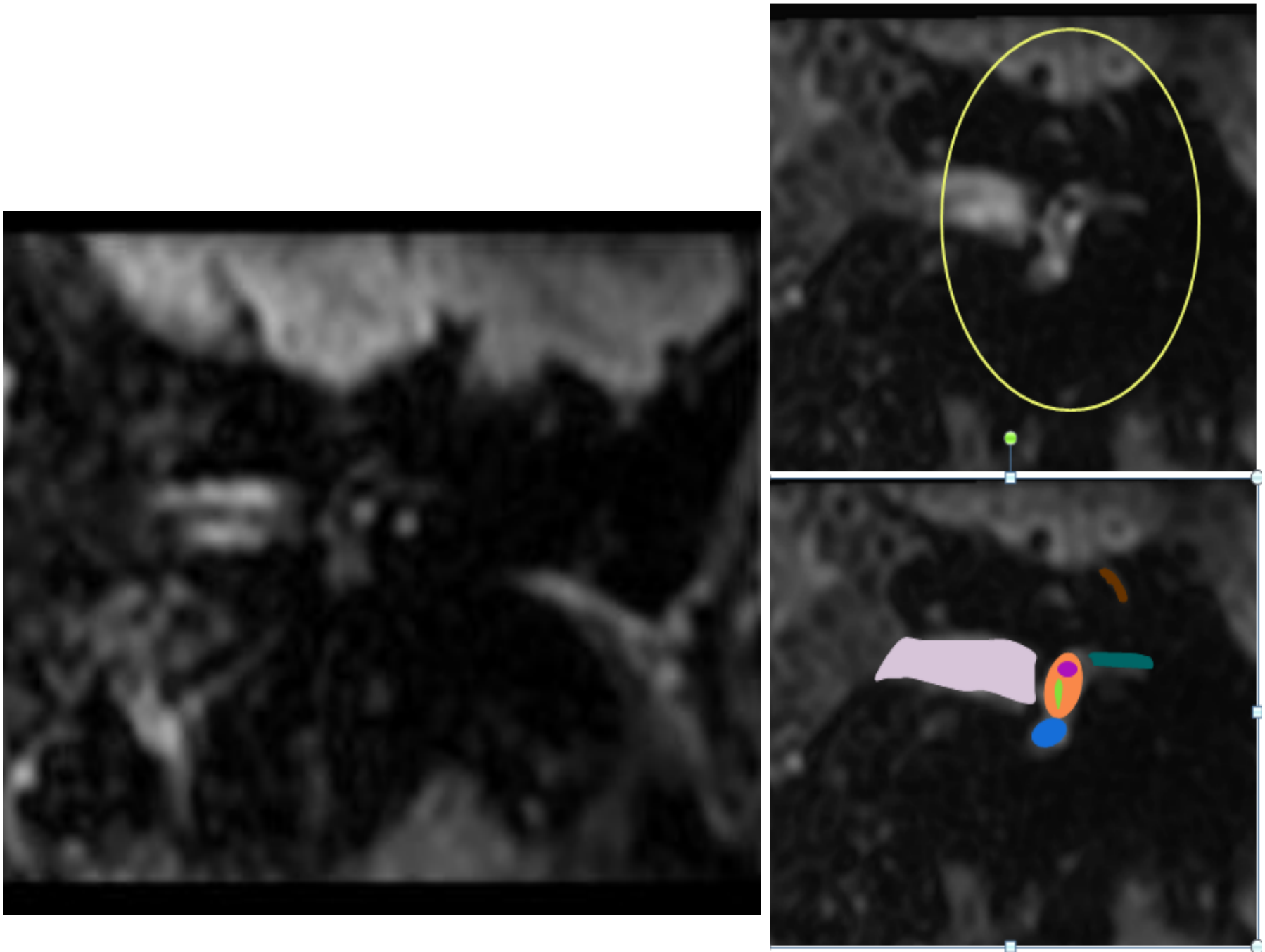

Utricule
Saccule

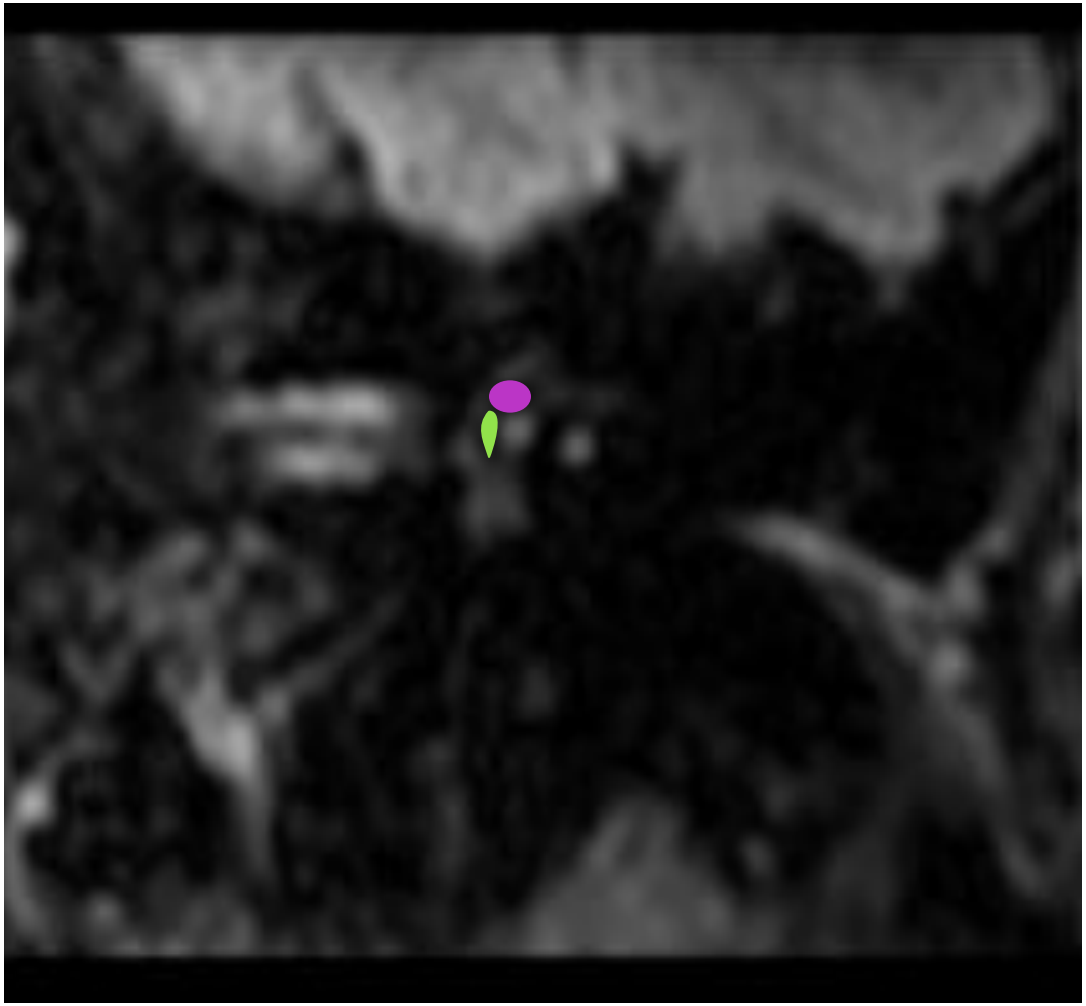

Coronale

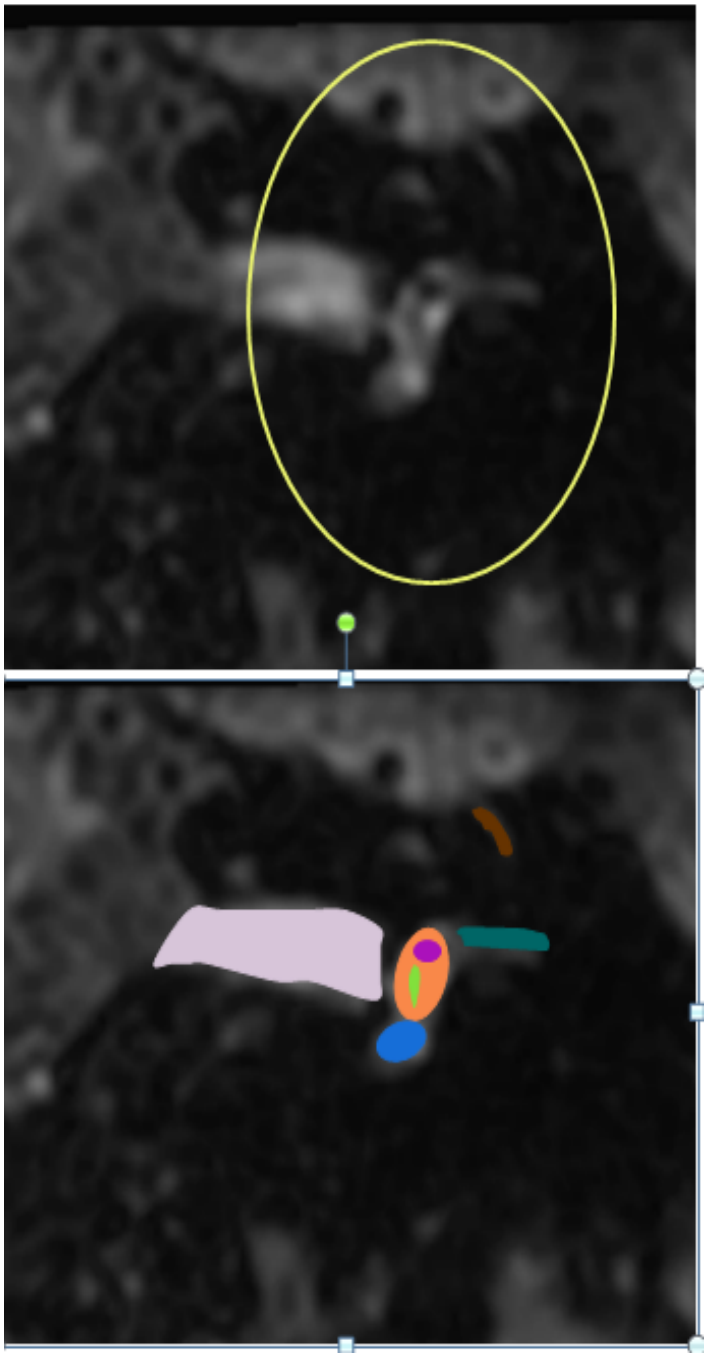

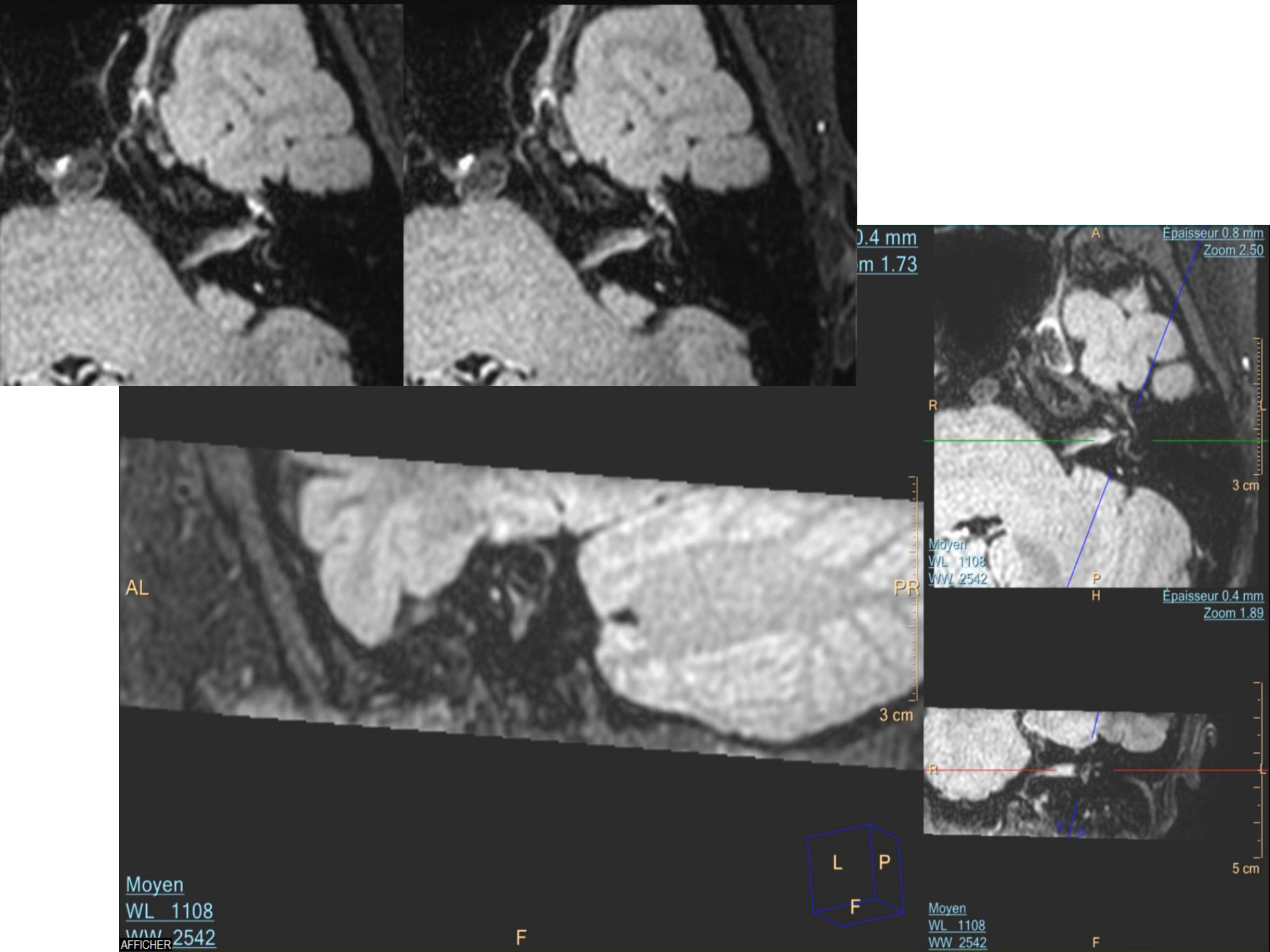
0.4 mm
m 1.73
A
Epaisseur 0.8 mm
Zoom 2.50
R
L
3 cm
Moyen
WL 1108
WW 2542
P
H
Épaisseur 0.4 mm
Zoom 1.89
AL
PR
3 cm
R
L
5 cm
L
P
F
Moyen
WL 1108
WW 2542
F
Moyen
WL 1108
WW 2542
F
AFFICHER

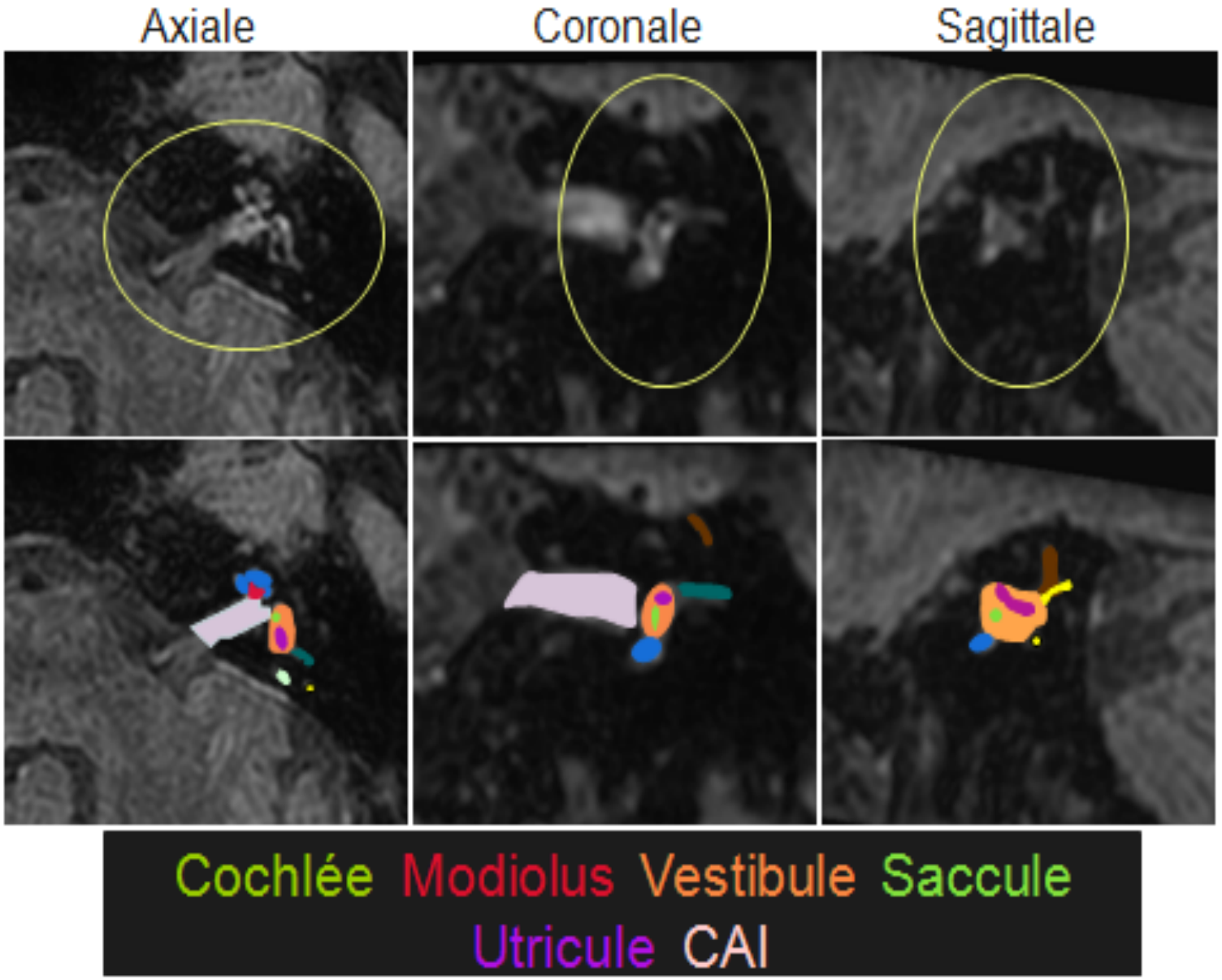

Schémas d'Anne Sophie Delemasure

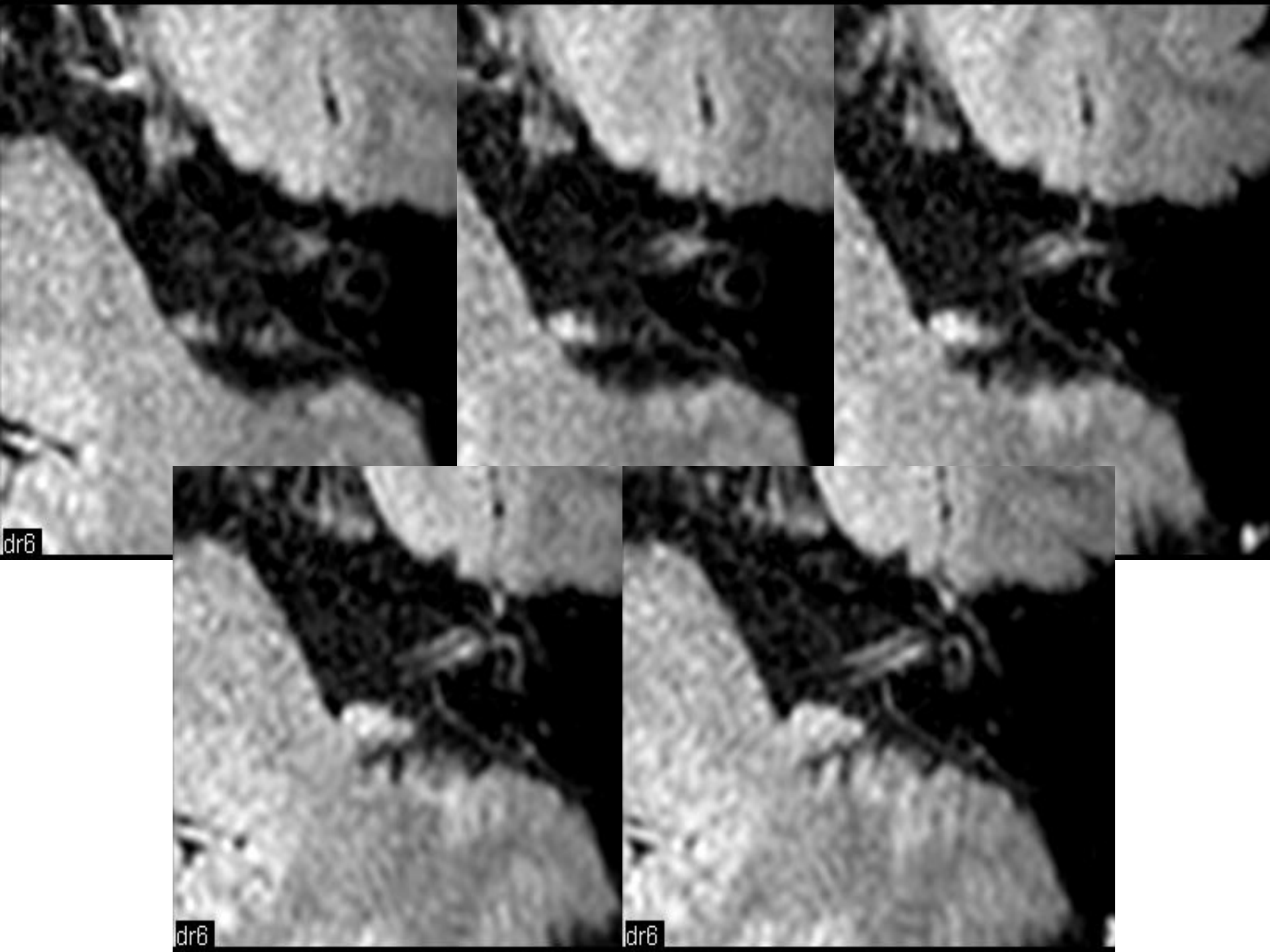
dr6
dr6
dr6

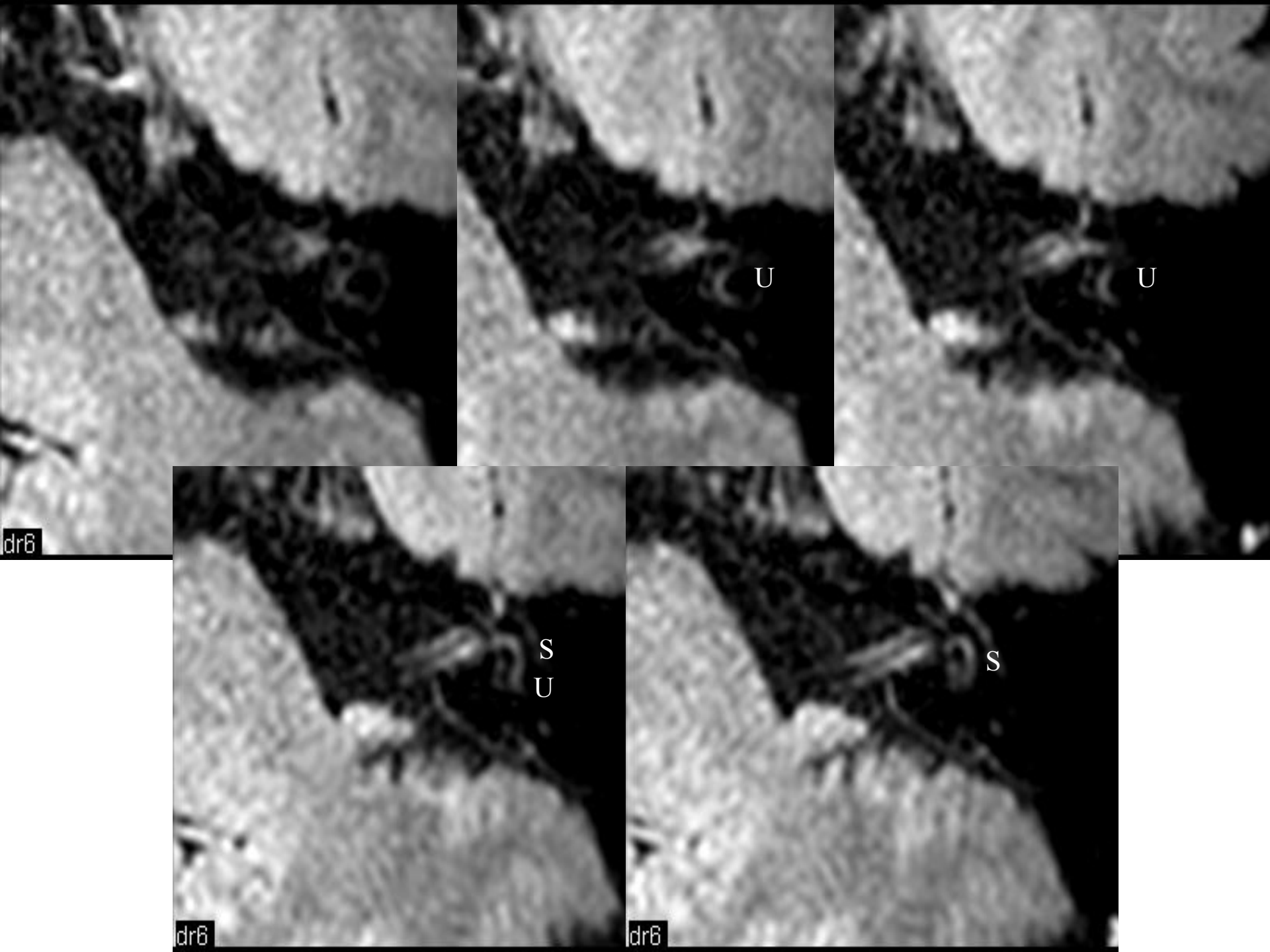
U
U
S
U
S
dr6
dr6
dr6

Bill. Seg. 27 ans
Sd vertigineux atypique gauche

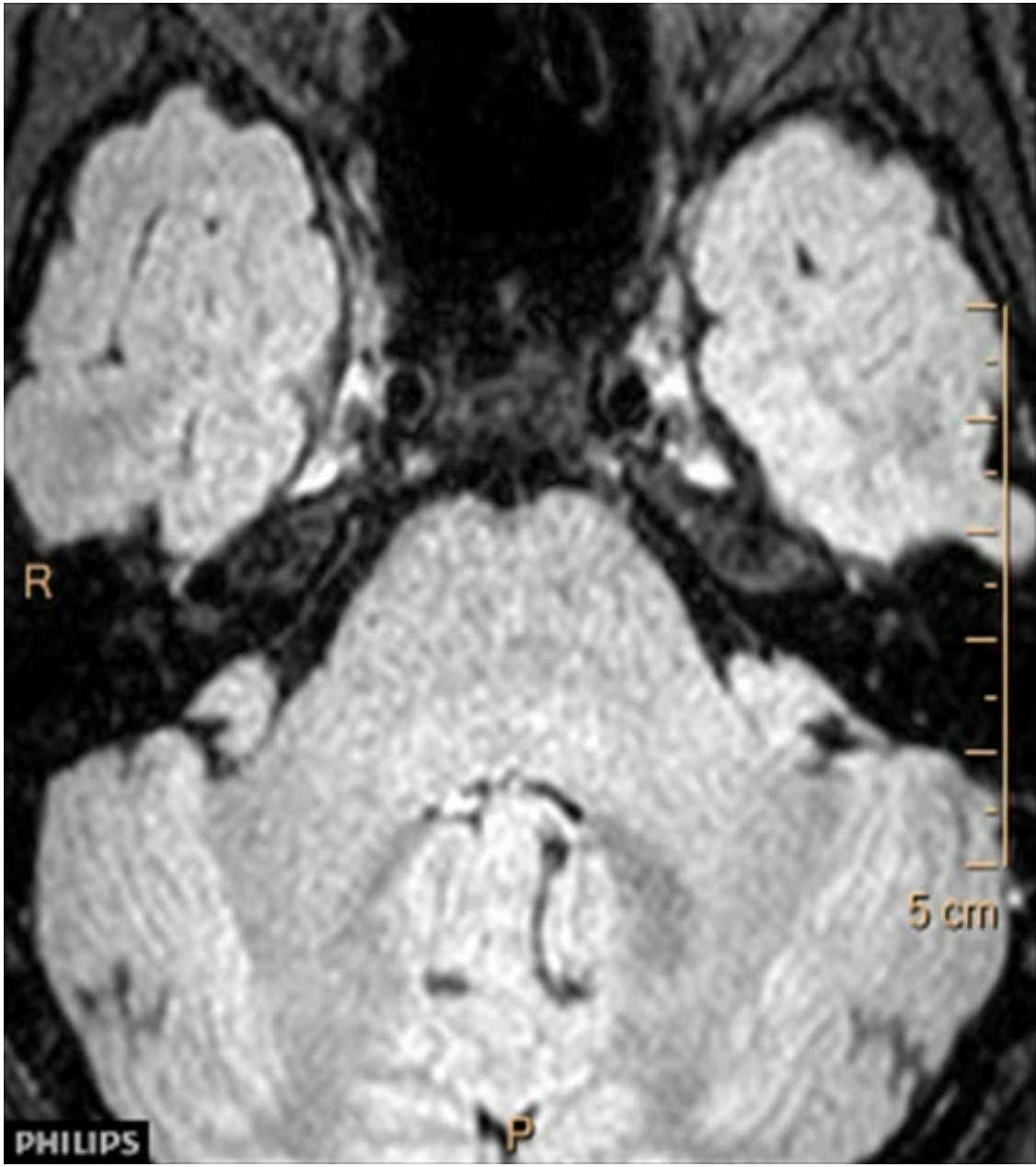

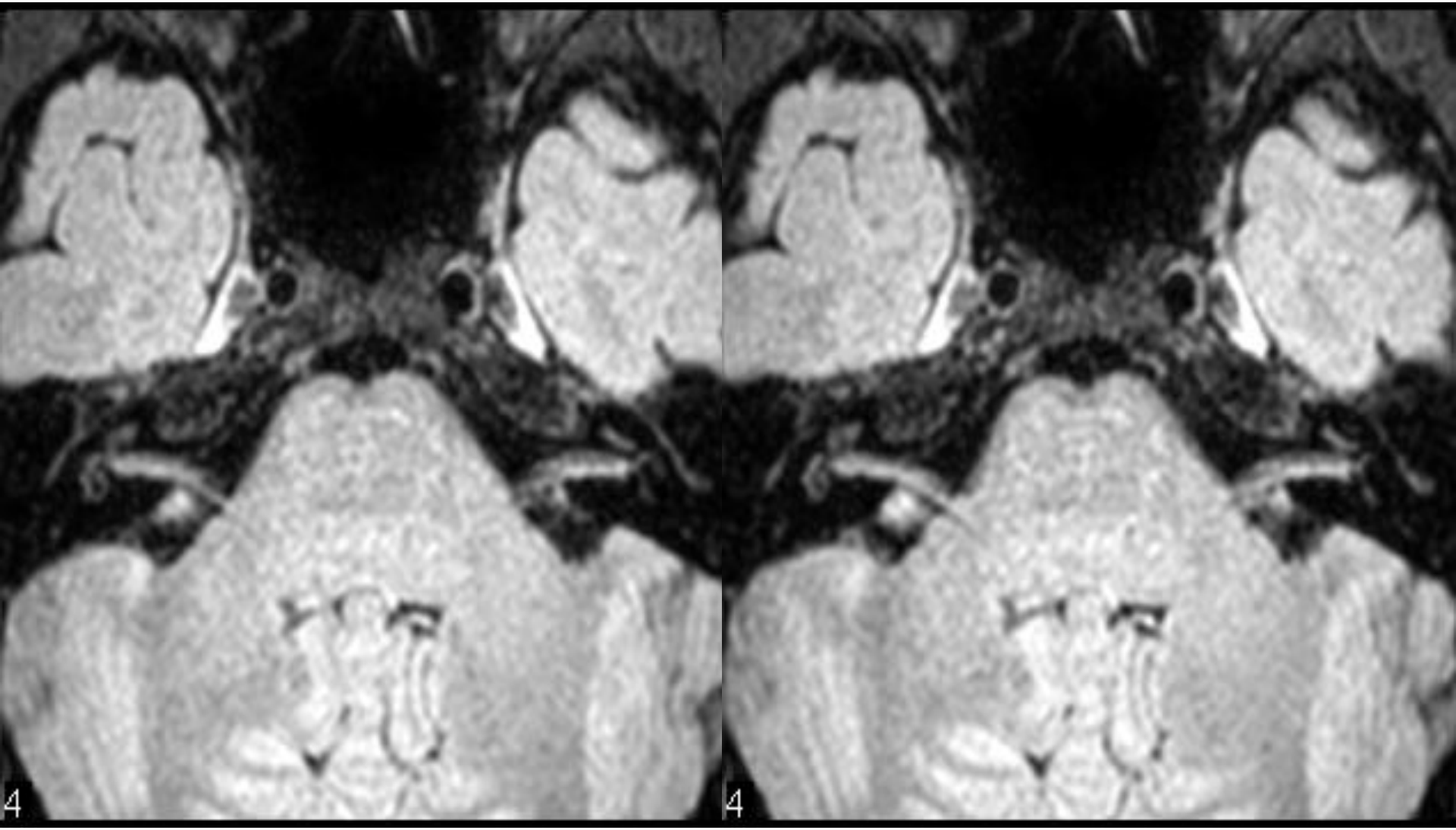
4
4

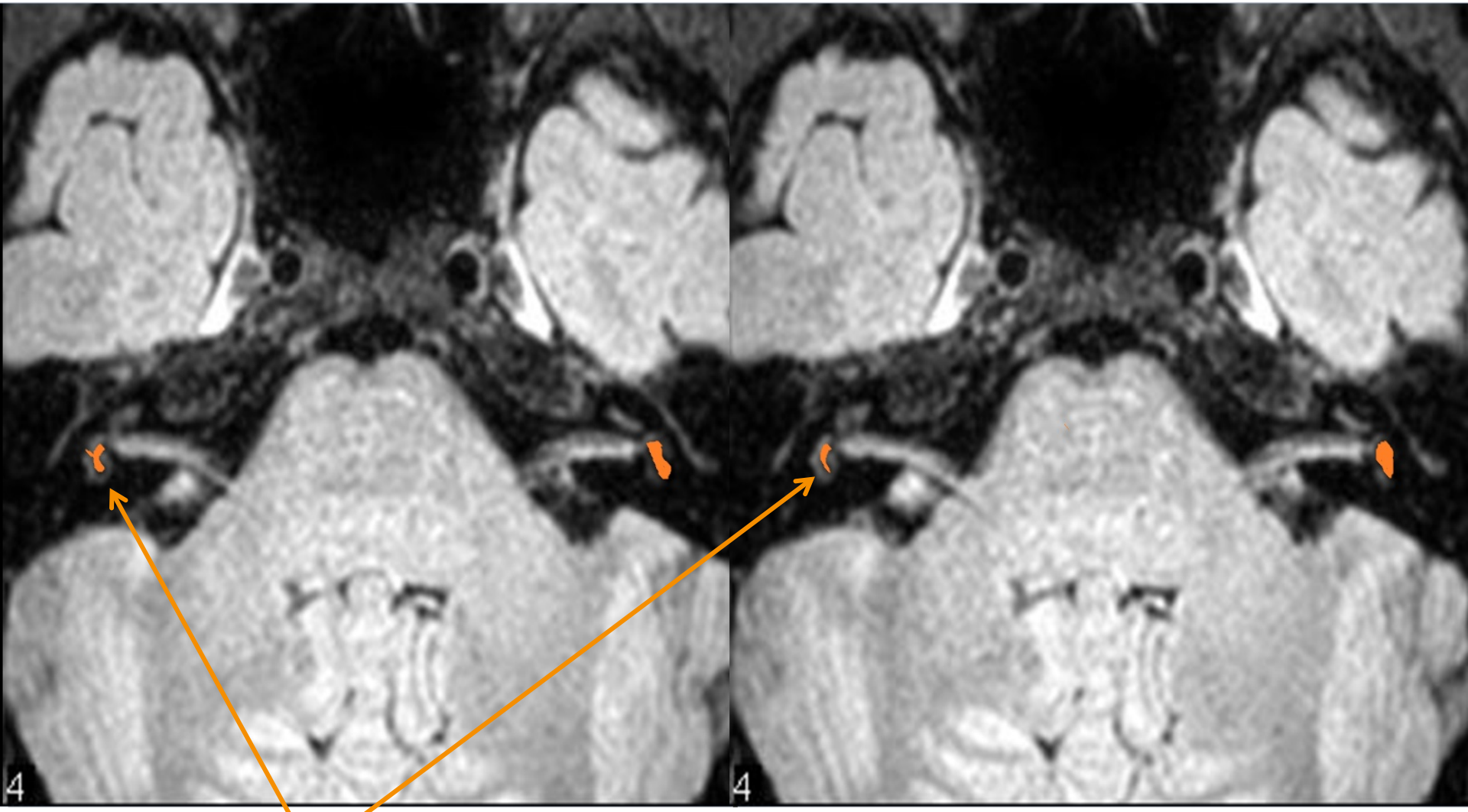

À droite

pas hydrops

endolymphe < 30%

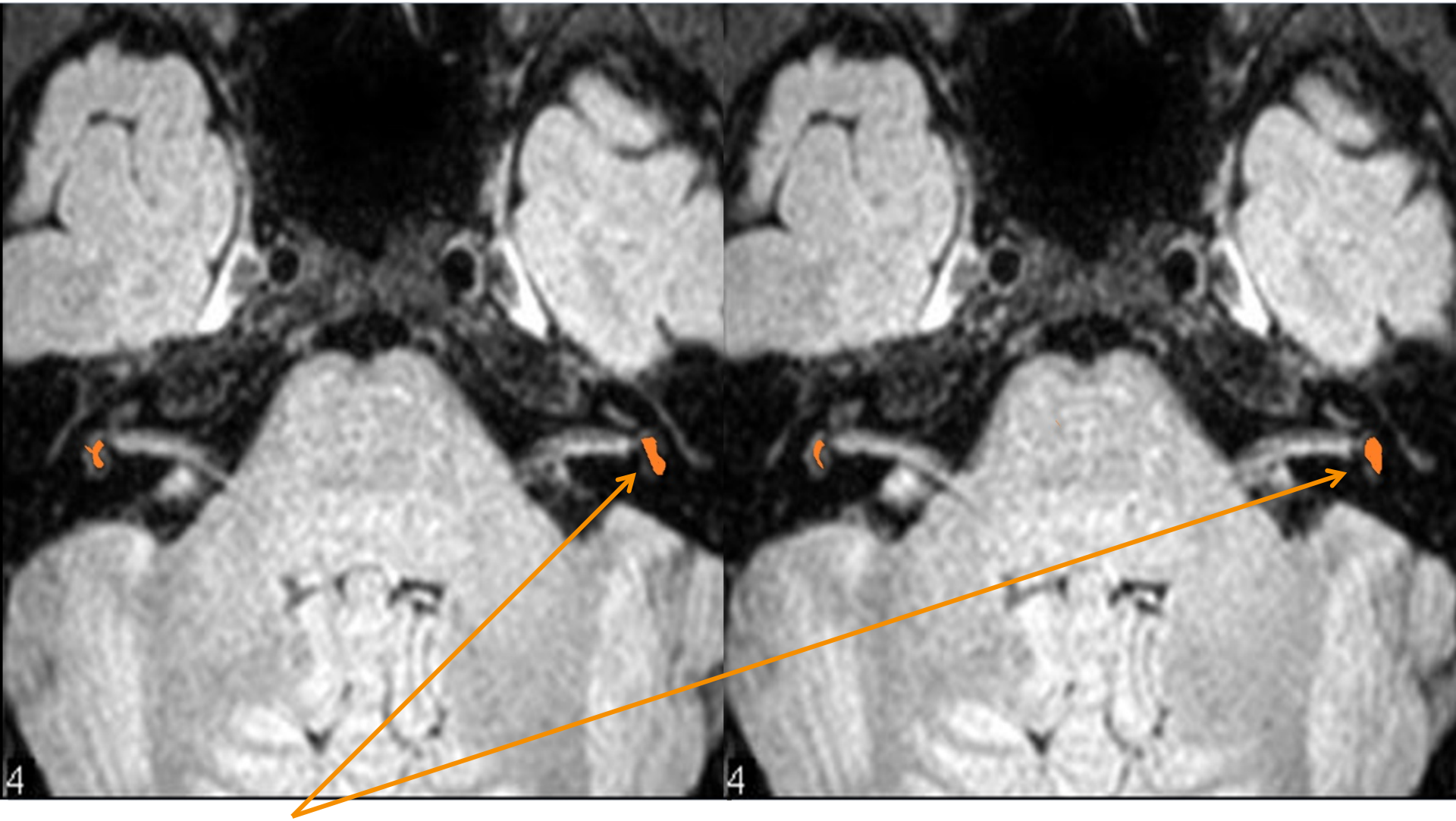

A gauche

hydrops significatif
endolymphe > 50%

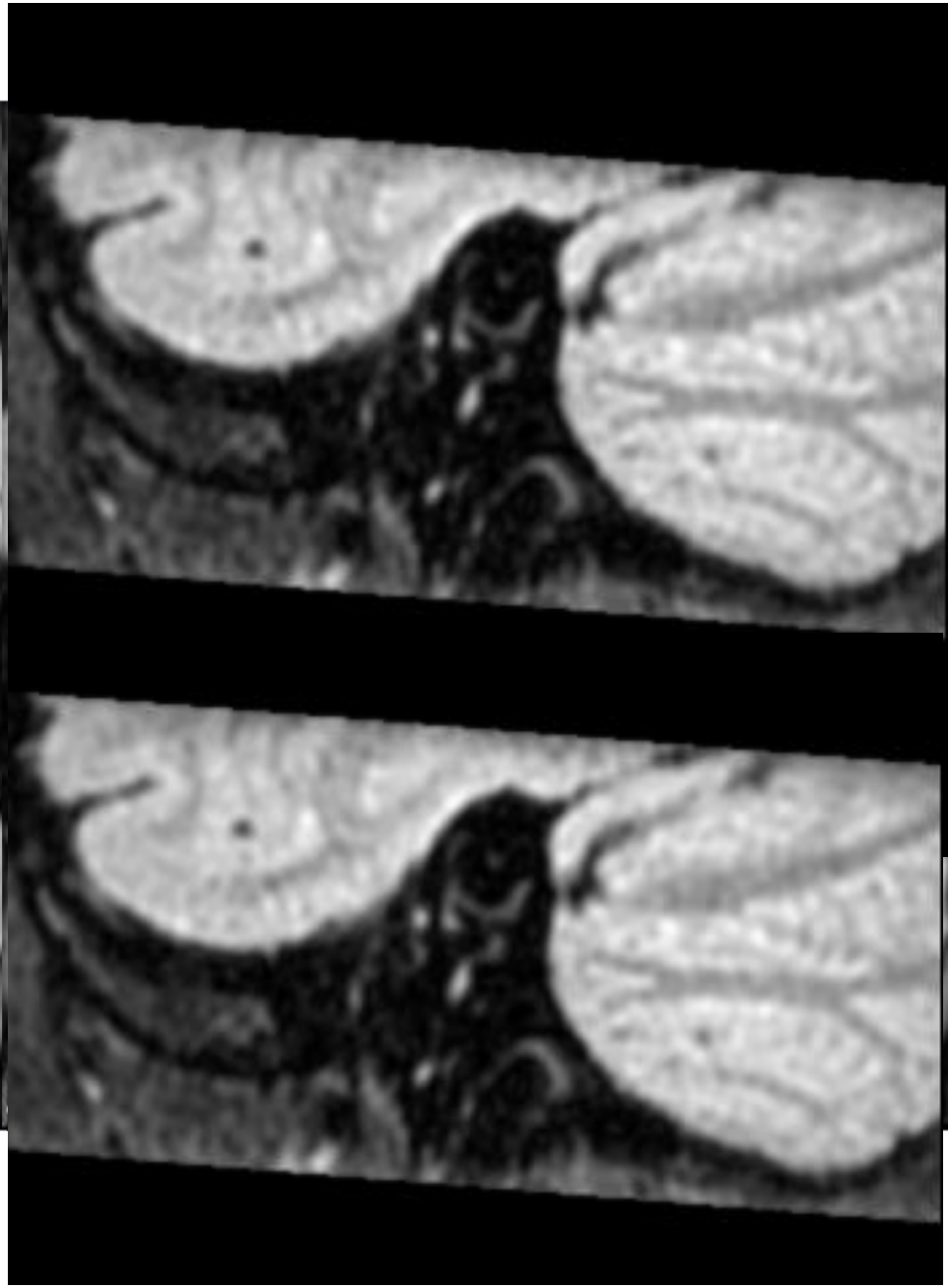

Reconstruction sagittale

Coté gauche avec hydrops significatif

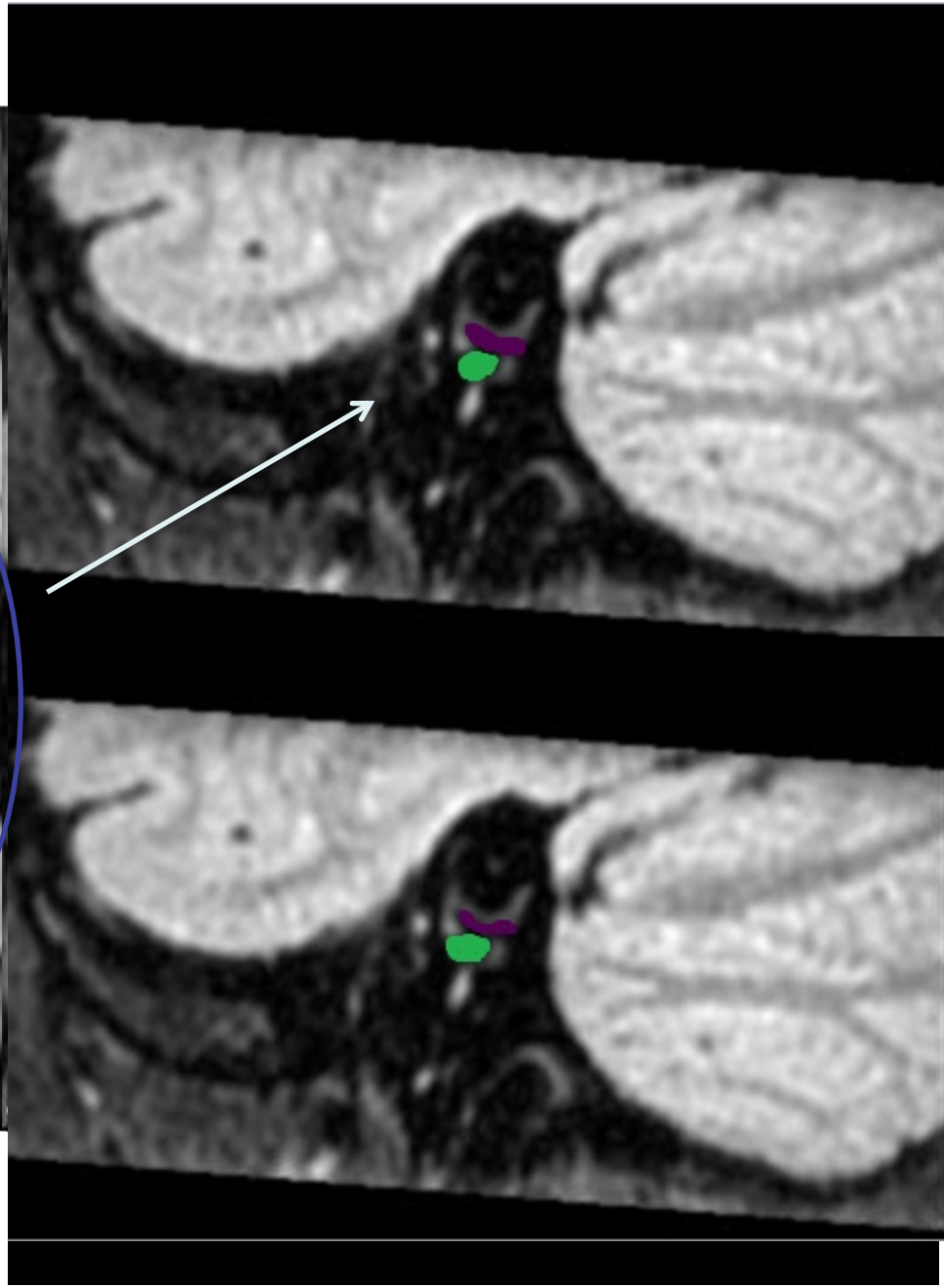

saccule > utricule

Saccule to Utricule Ratio Inversion

SURI

Reconstruction sagittale

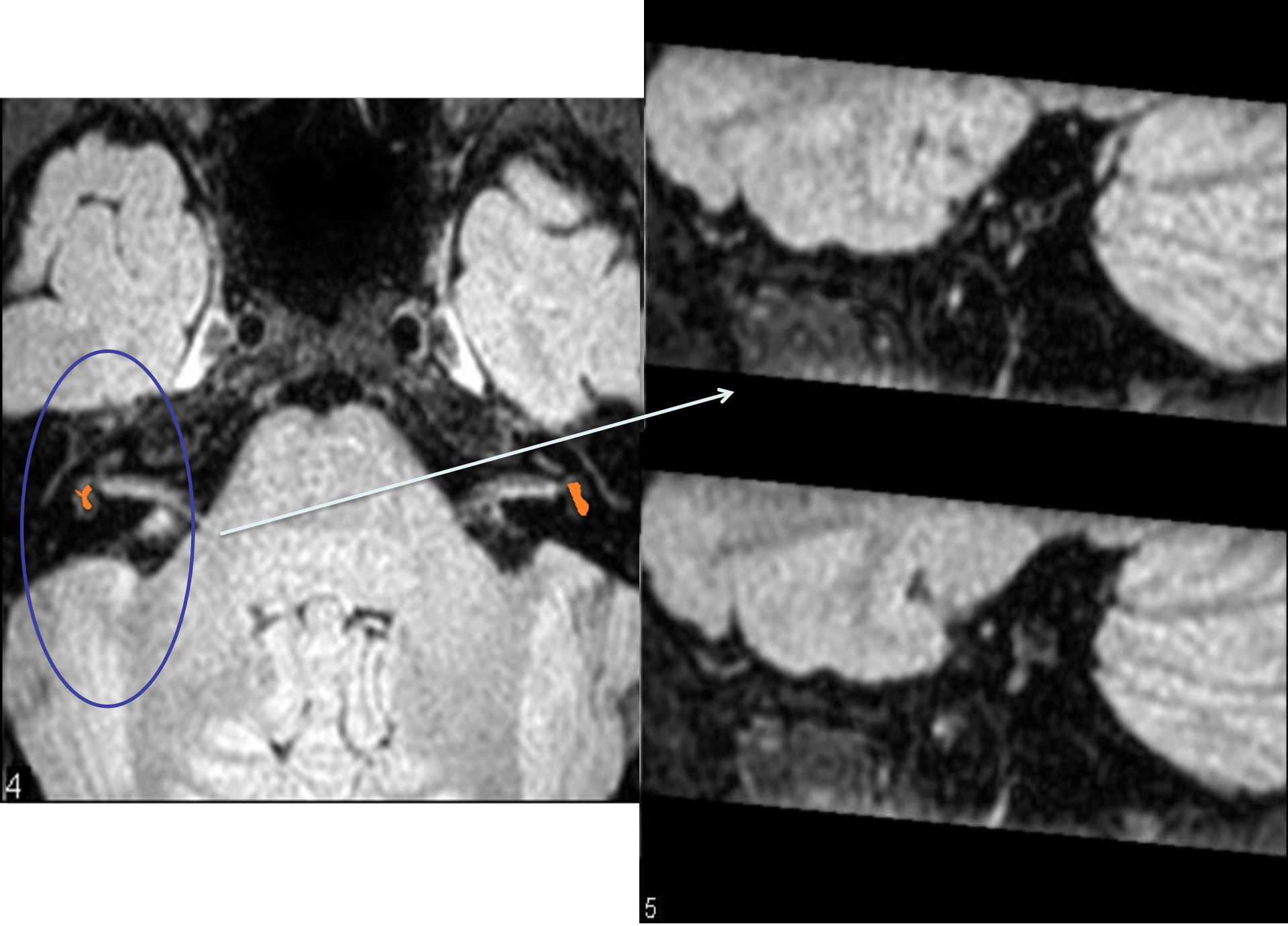

Reconstruction sagittale

Coté droit normal

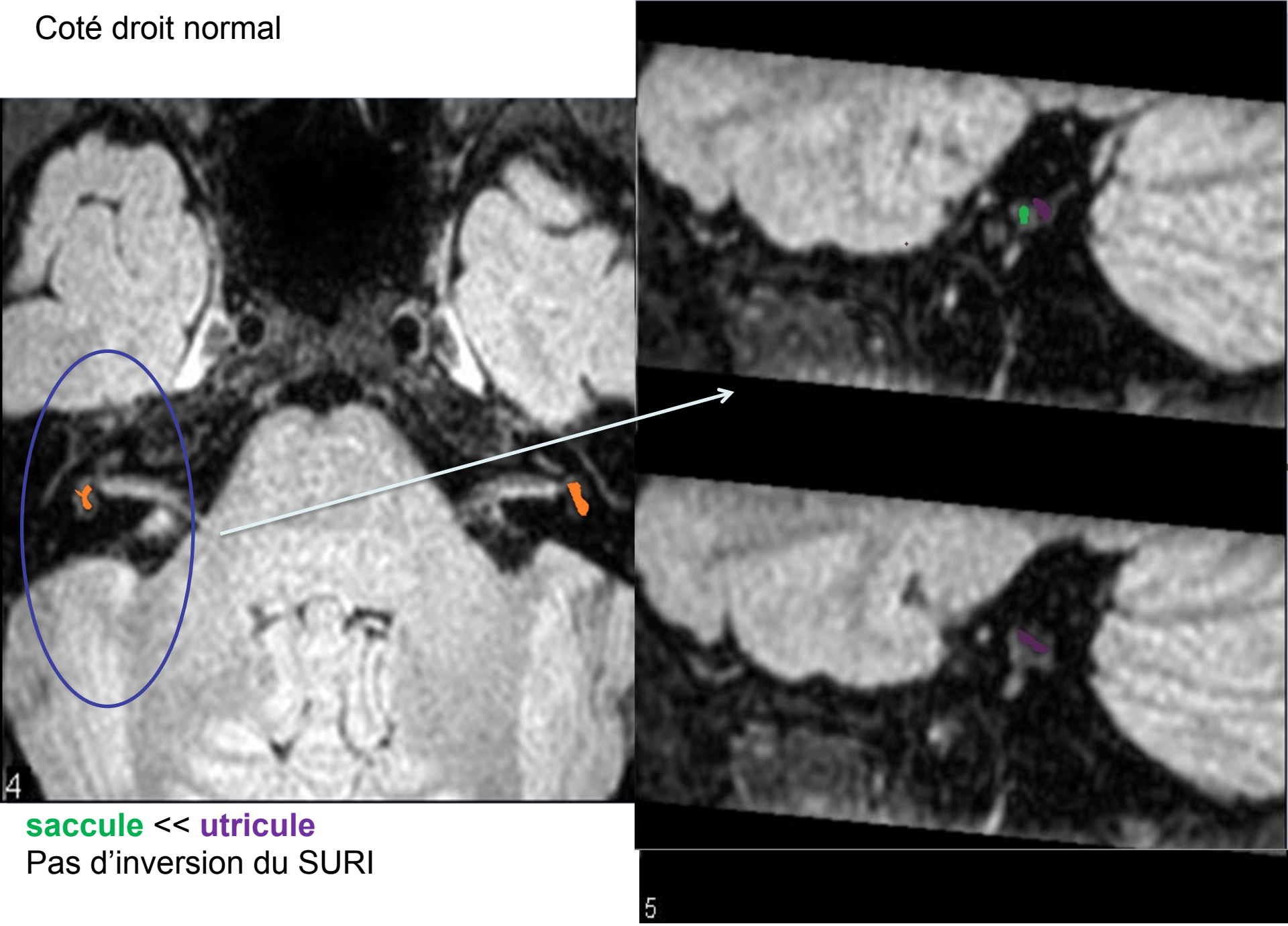

saccule << **utricule**

Pas d'inversion du SURI

Reconstruction sagittale

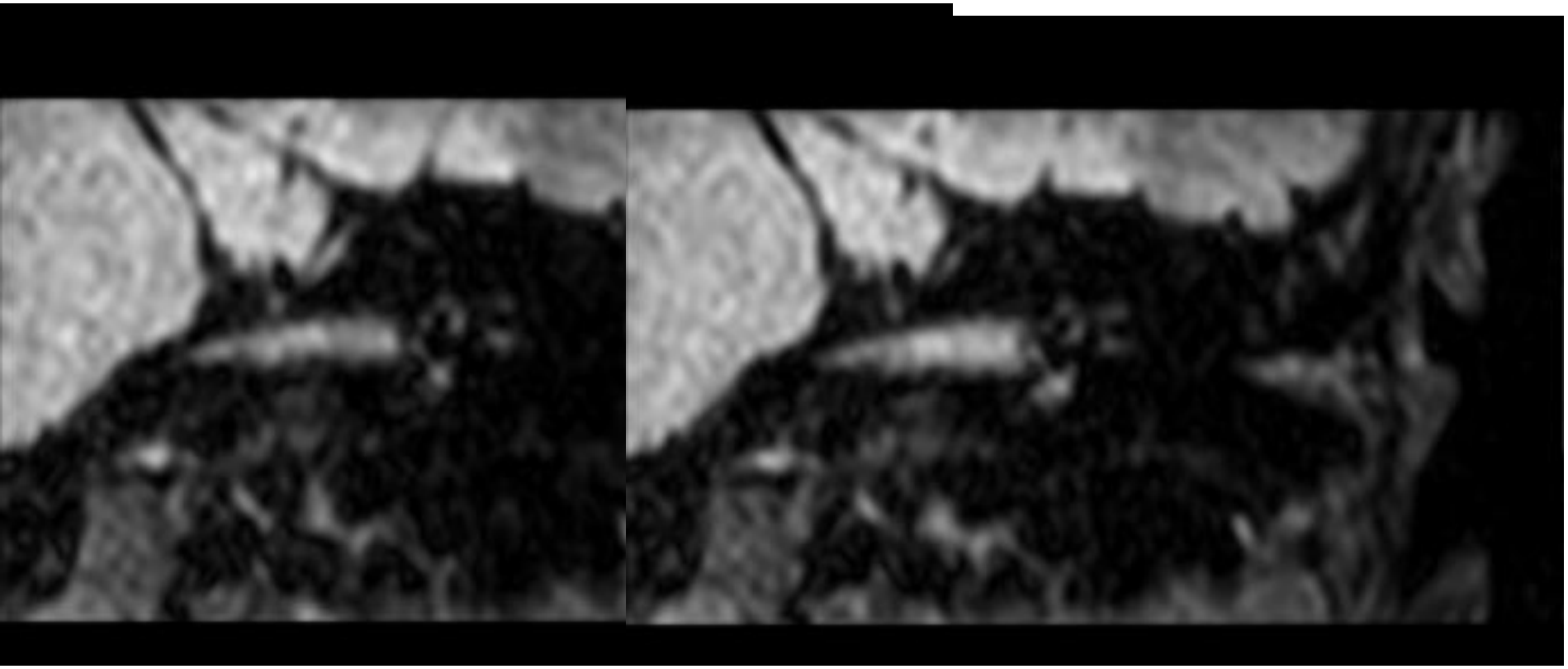

Reconstruction coronale
saccule G > **utricule**

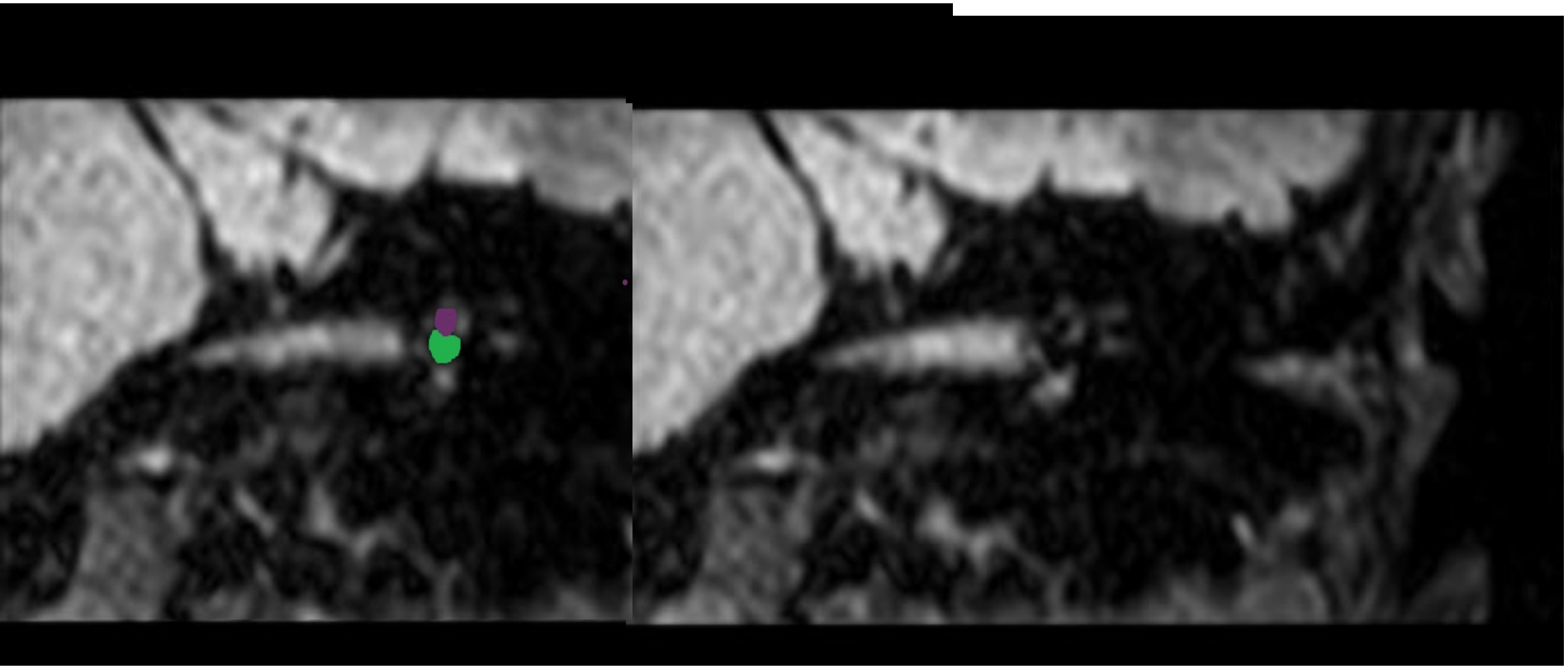

Reconstruction coronale
saccule G > **utricule**

Patiente 48 ans maladie Menière invalidante droite RAS à gauche
Indication éventuelle de neurectomie vestibulaire droite

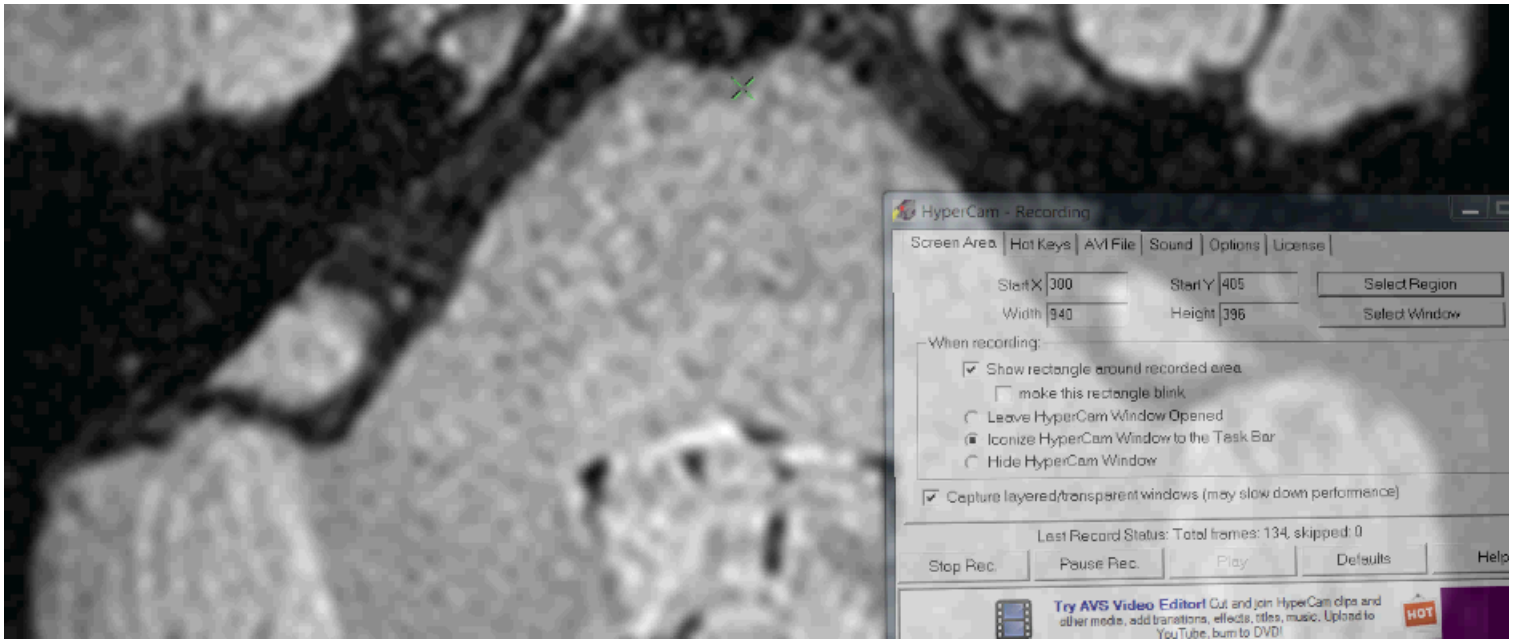

Patiente 48 ans maladie Menière invalidante droite RAS à gauche
Indication éventuelle de neurectomie vestibulaire droite

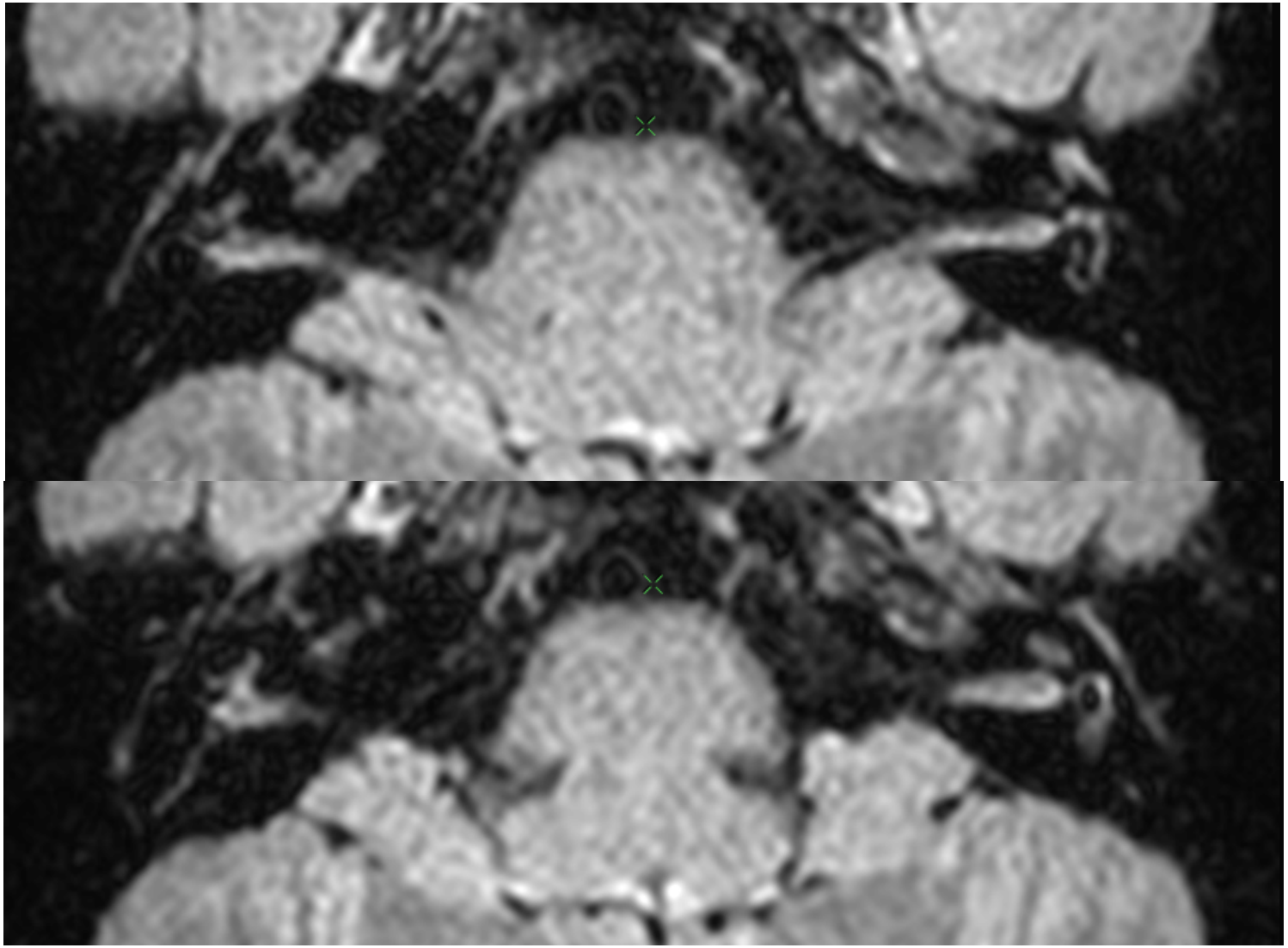

Patiente 48 ans maladie Menière invalidante droite RAS à gauche
Indication éventuelle de neurectomie vestibulaire droite

D

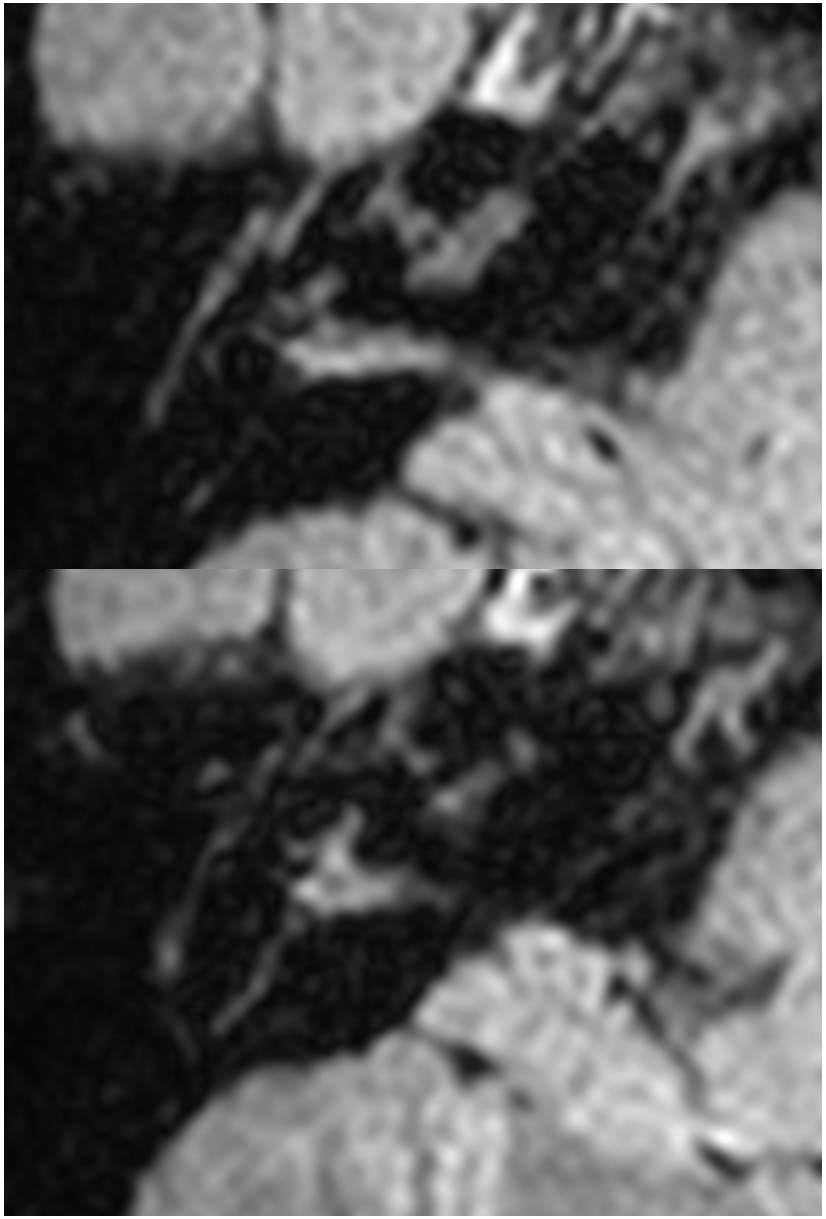

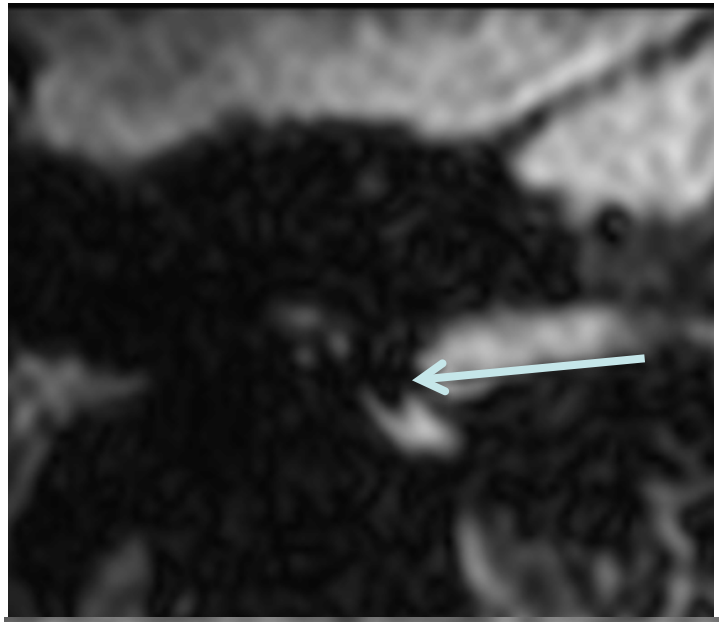

coronal

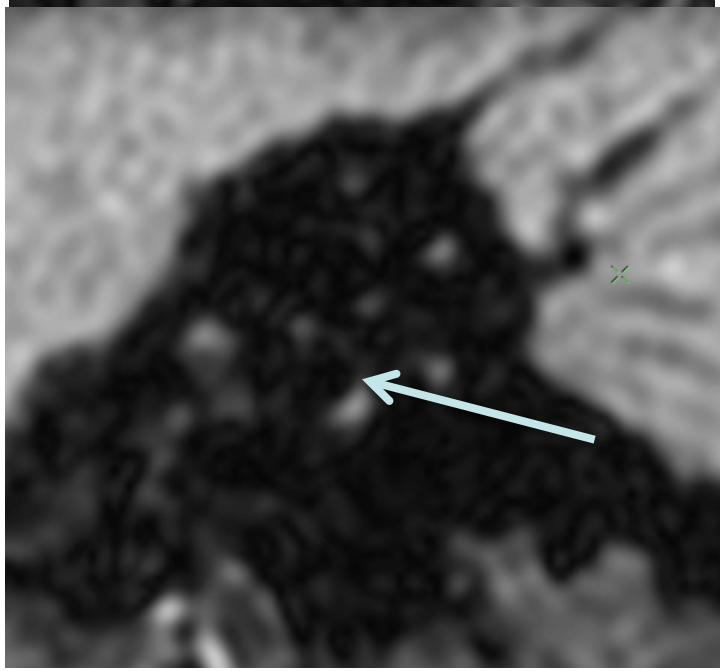

sagittal

Patiente 48 ans maladie Menière invalidante droite RAS à gauche
Indication éventuelle de neurectomie vestibulaire droite

D

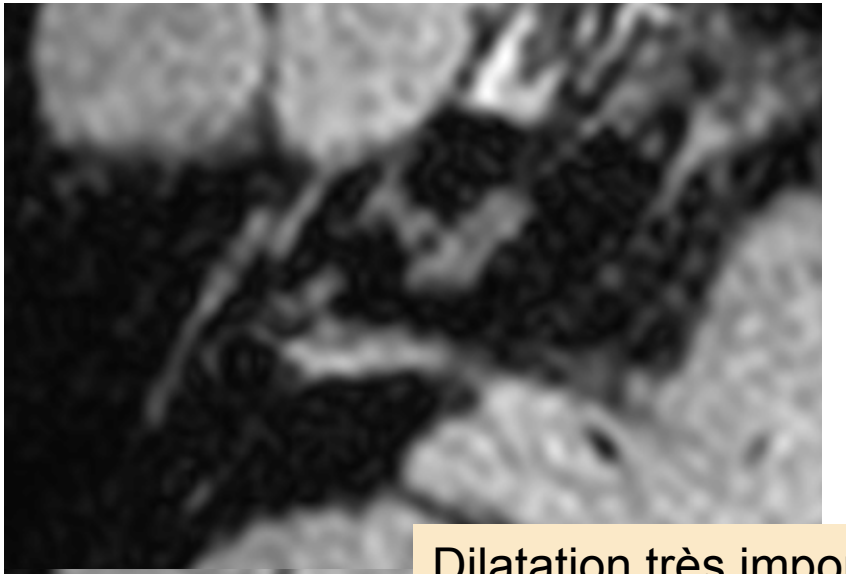

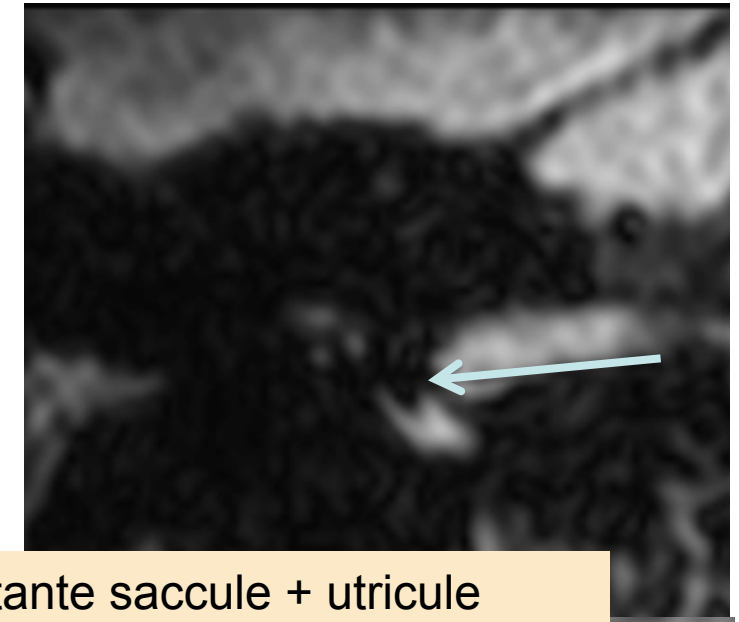

coronal

Dilatation très importante saccule + utricule
SURI +++

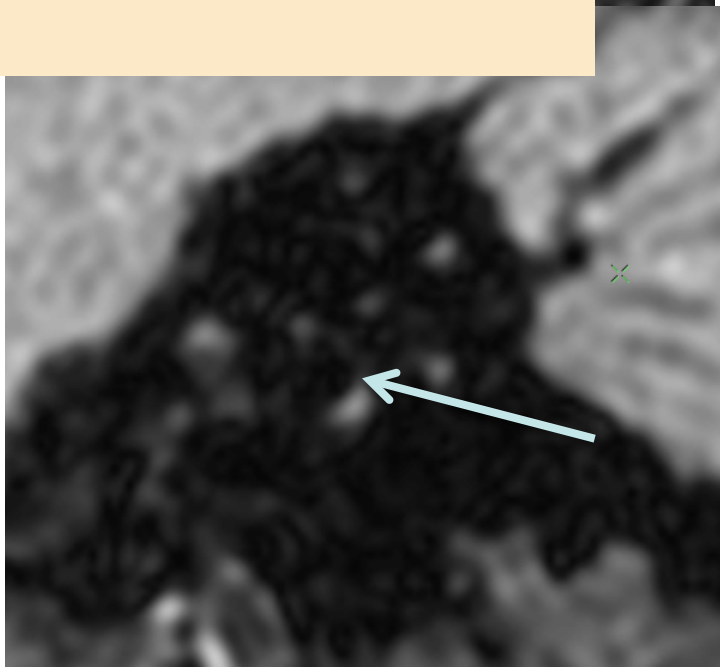

sagittal

Patiente 48 ans maladie Menière invalidante droite RAS à gauche
Indication éventuelle de neurectomie vestibulaire droite

D

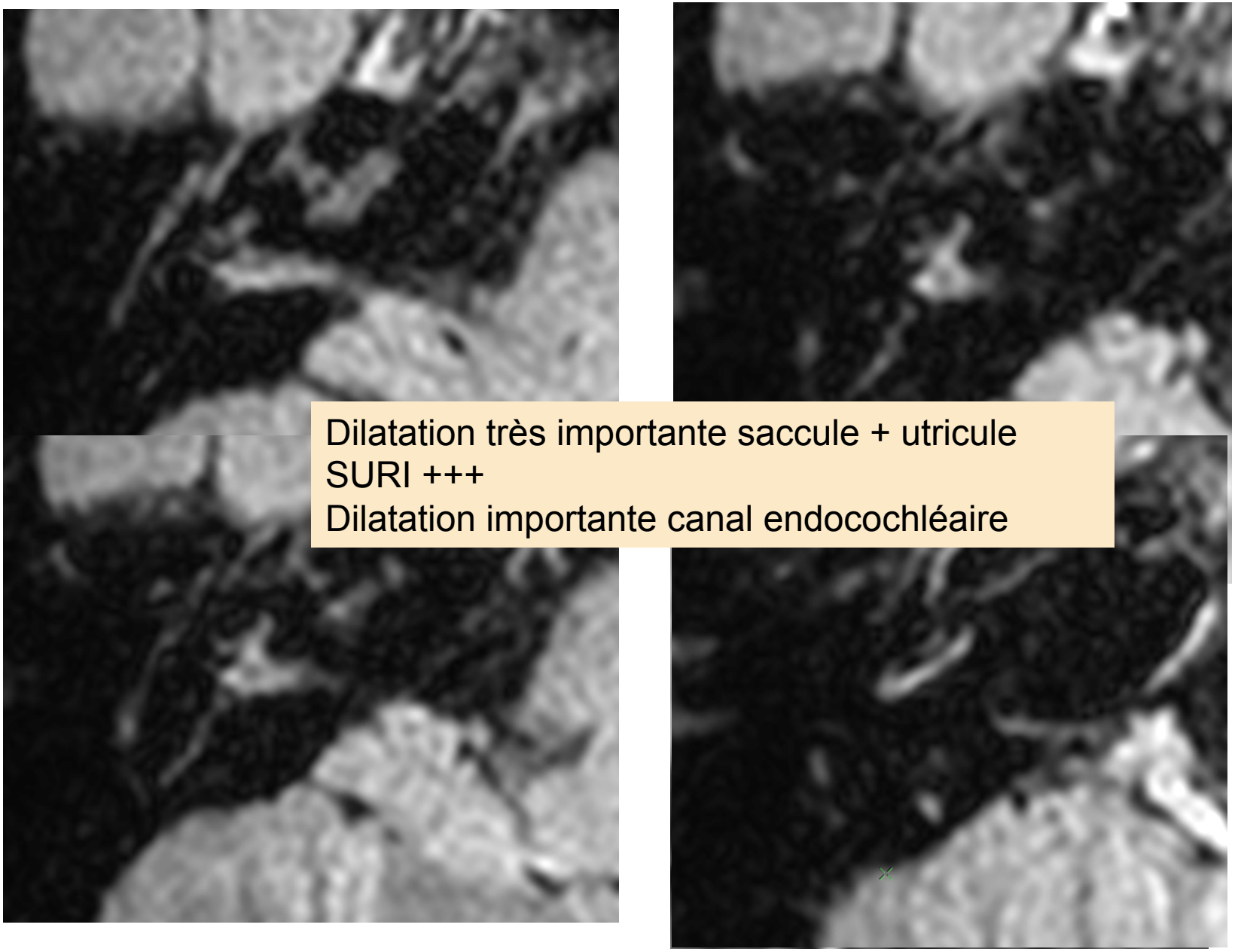

Dilatation très importante saccule + utricule
SURI +++
Dilatation importante canal endocochléaire

Patiente 48 ans maladie Menière invalidante droite RAS à gauche
Indication éventuelle de neurectomie vestibulaire droite

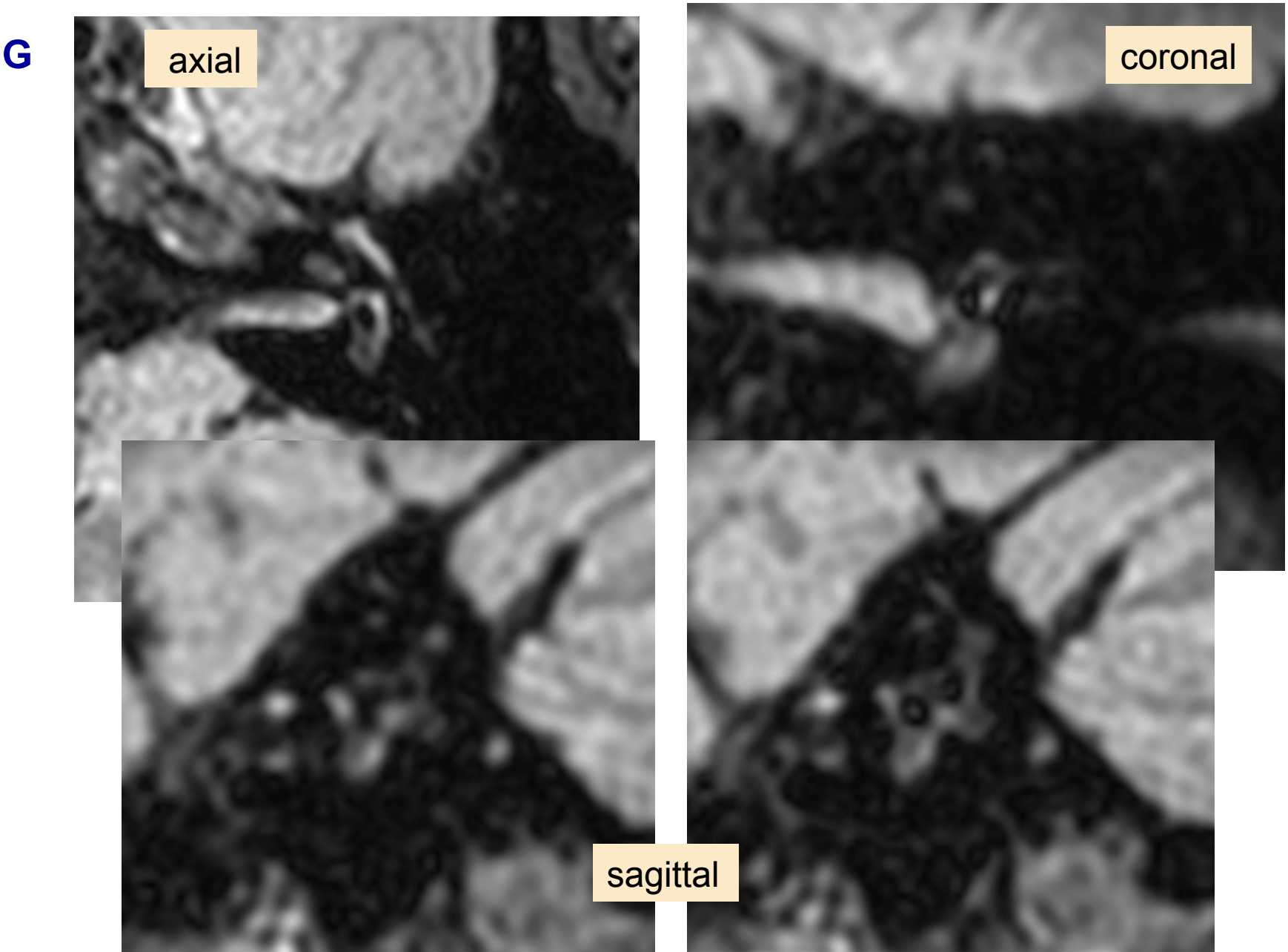

Patiente 48 ans maladie Menière invalidante droite RAS à gauche
Indication éventuelle de neurectomie vestibulaire droite

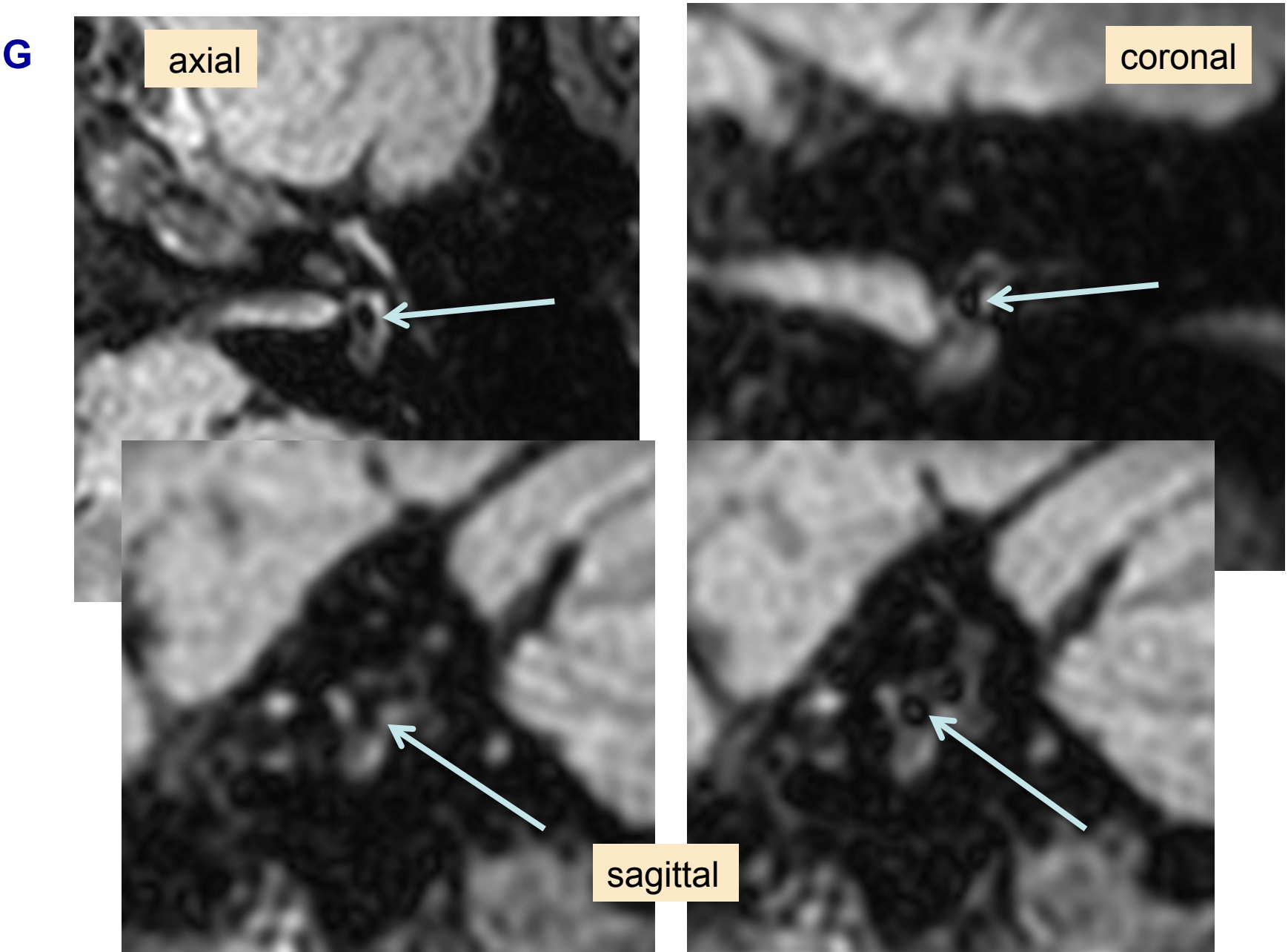

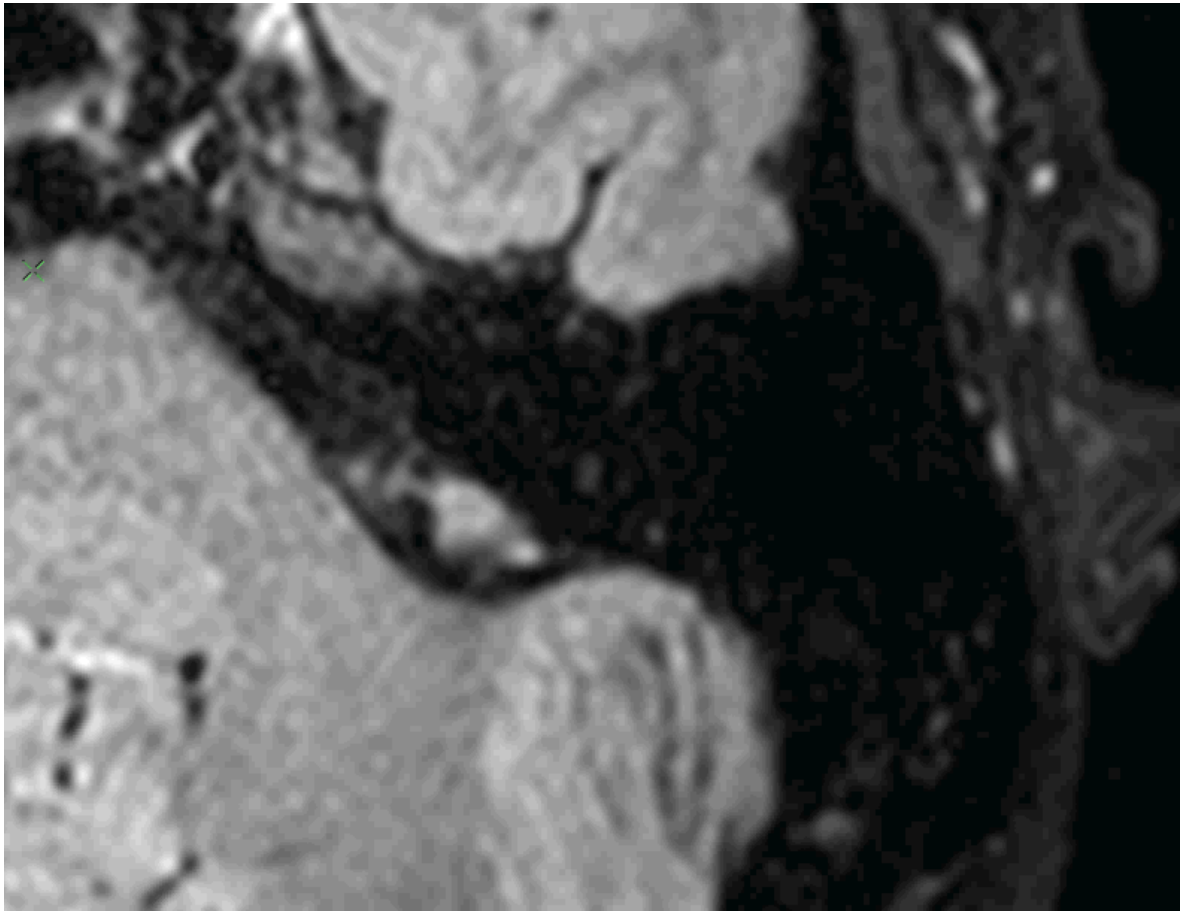

Dilatation importante
de l’ensemble des
structures
endolymphatiques à droite

À gauche,
dilatation du saccule
avec SURI

Patient avec suspicion hydrops droit

Patient avec suspicion hydrops droit

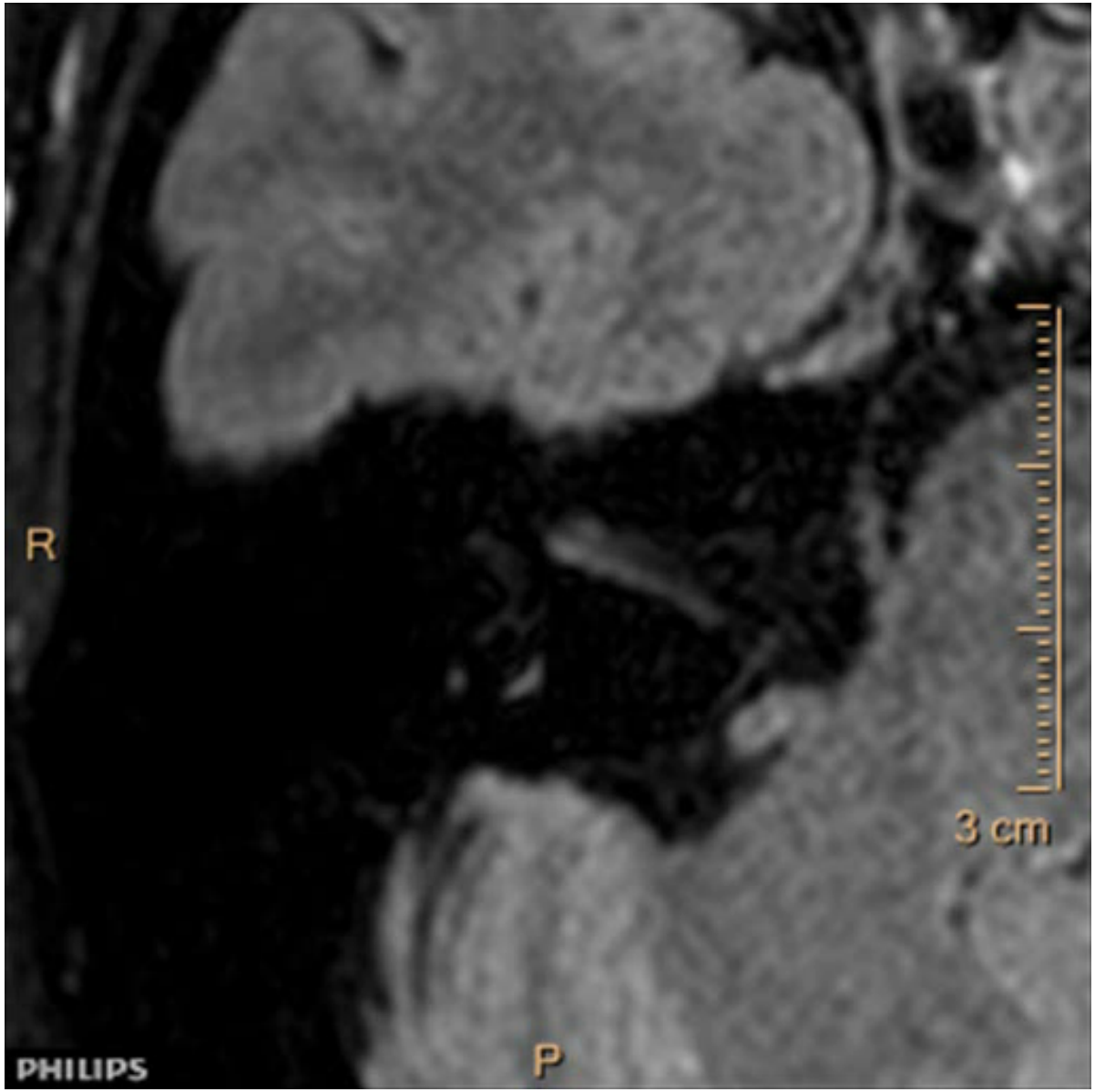

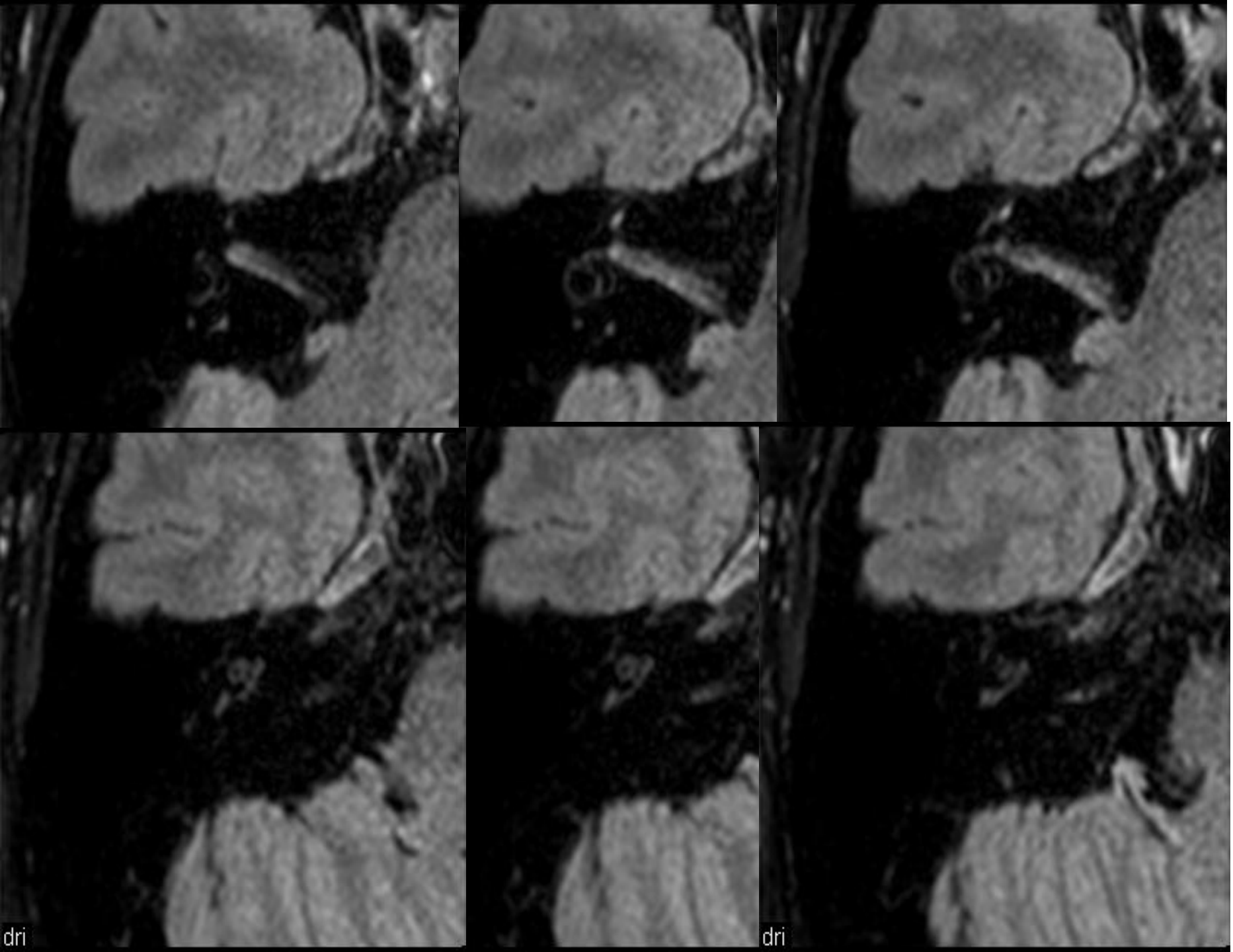
dri
dri

Utricule
Saccule

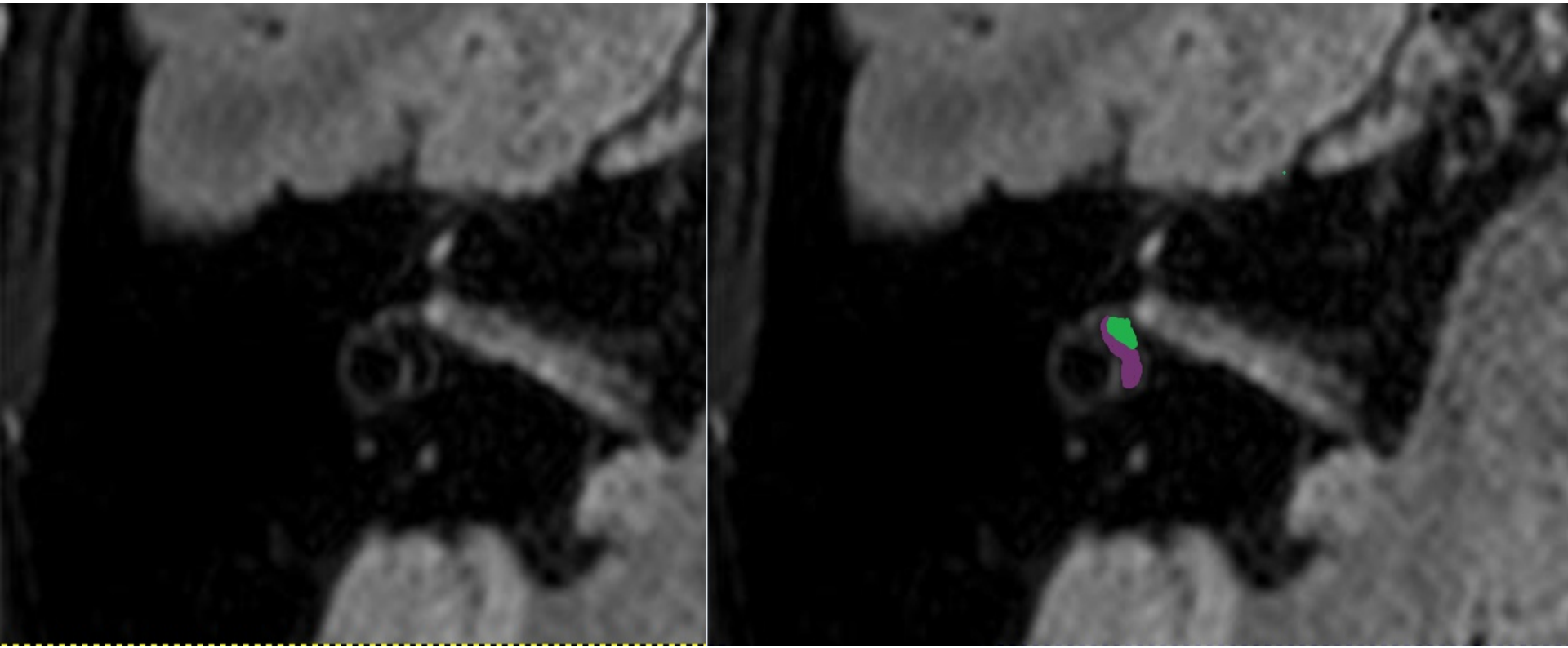

Hydrops significatif endolymphe > 50% of vestibule

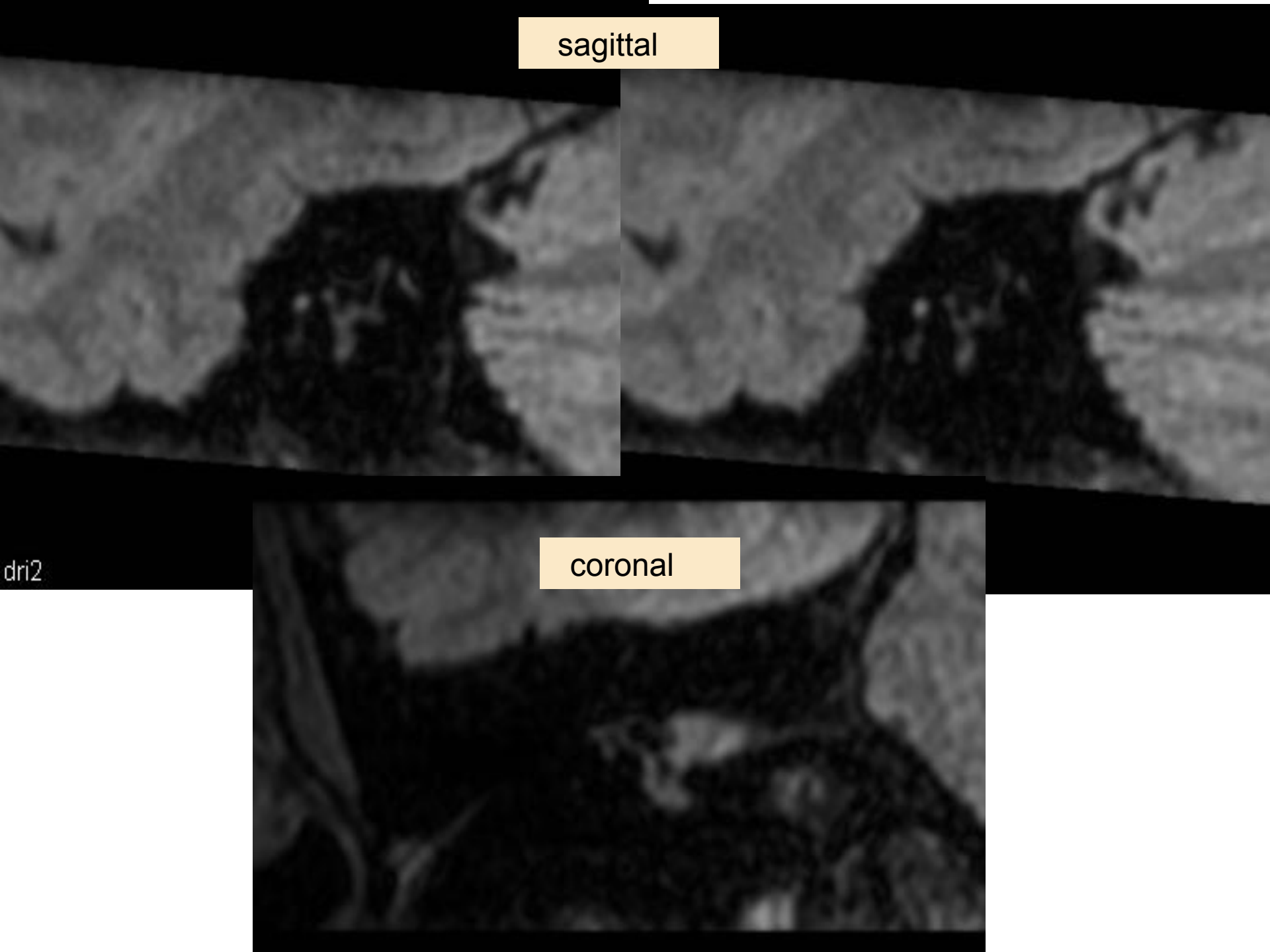
sagittal
coronal
dri2

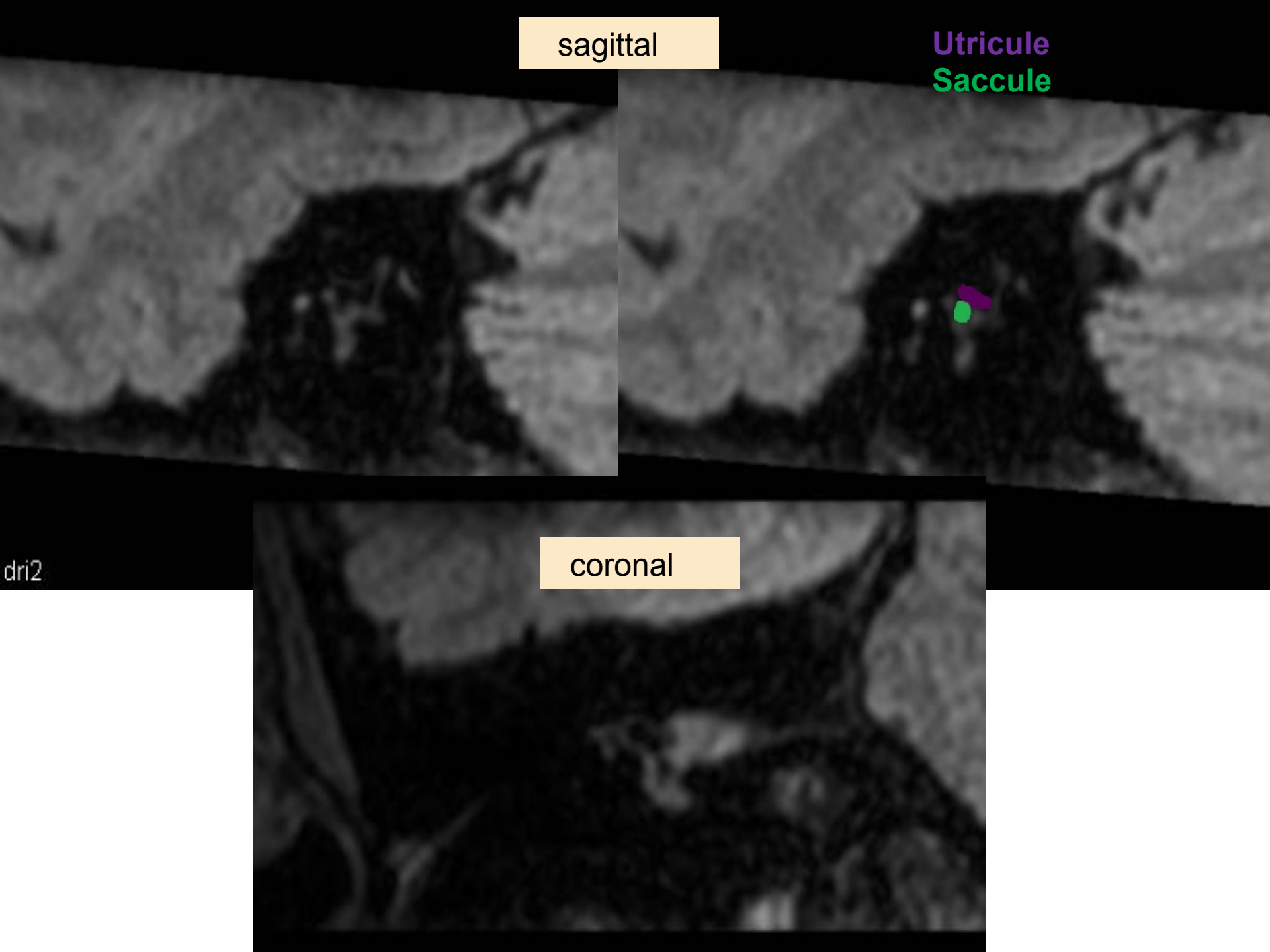
sagittal
Utricule
Saccule
dri2
coronal

Patient avec hydrops gauche significatif

Hydrops du canal endolymphatique
Cochléaire gauche

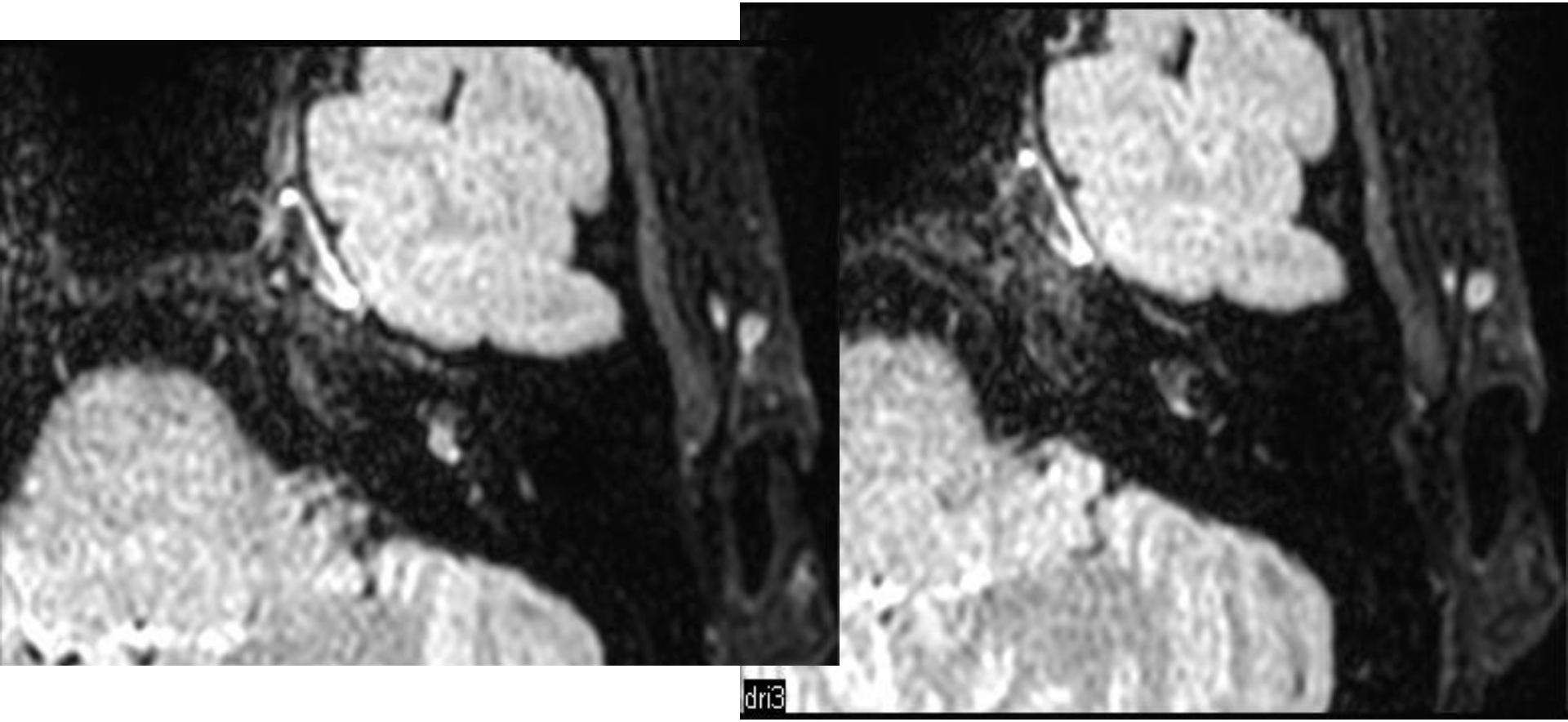
dri3

Mr Lamb. Claude Sd menieriforme atypique gauche

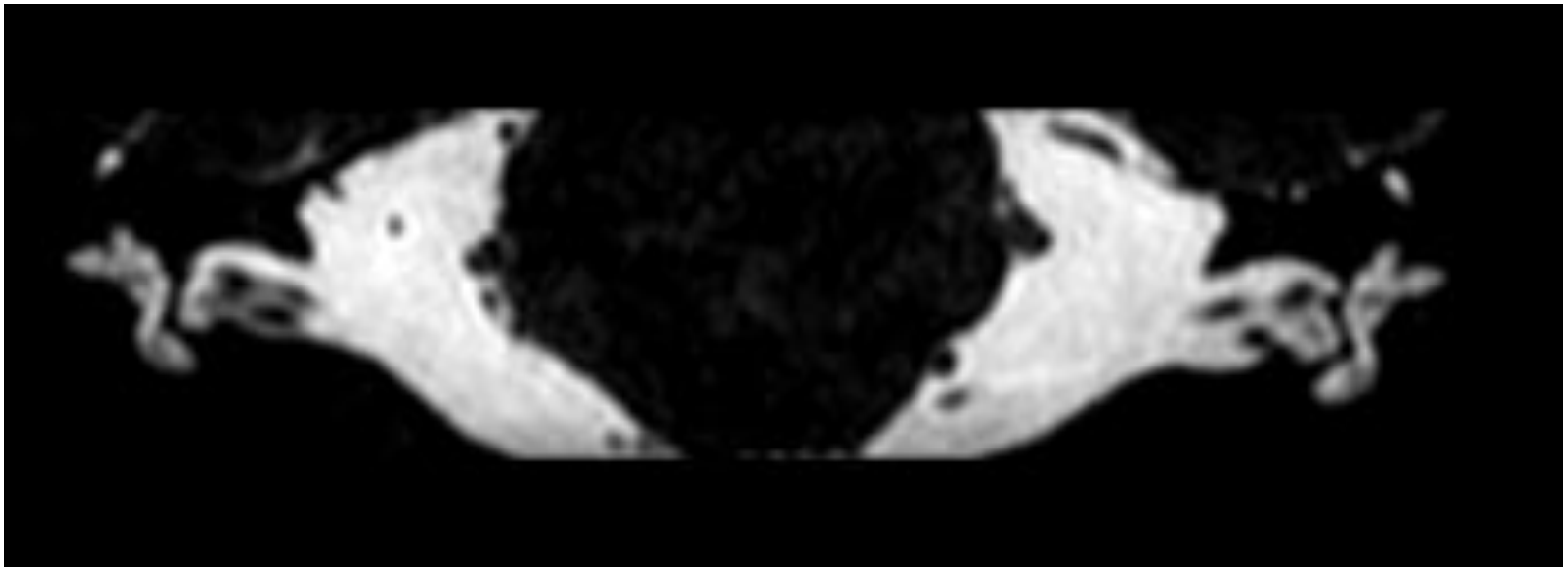

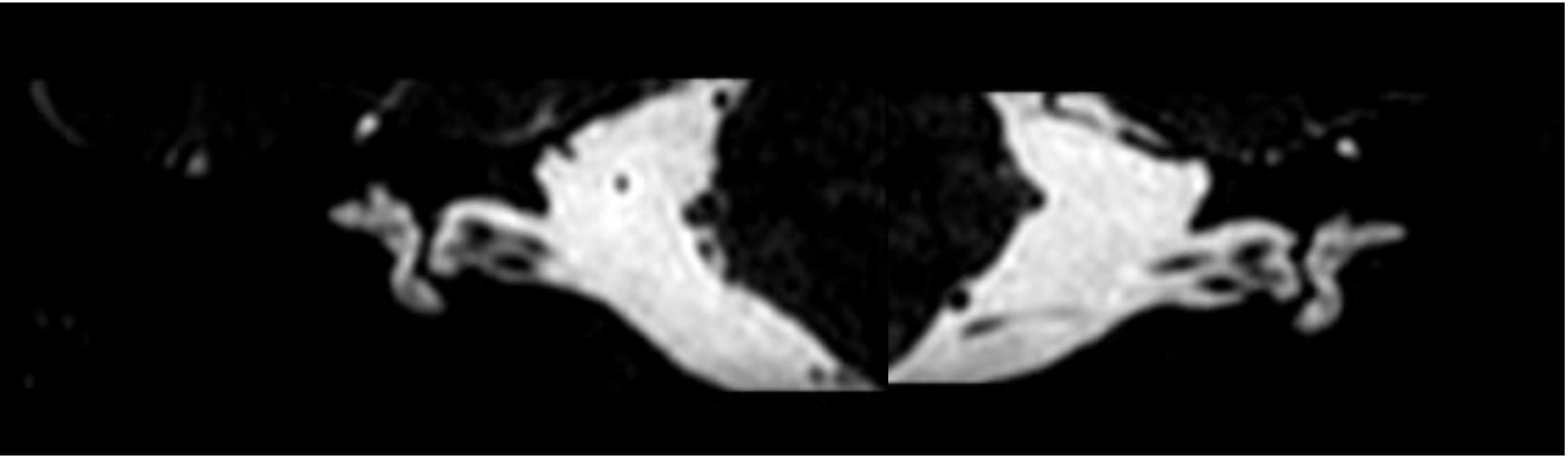

Saccule taille et morphologie normale en DRIVE

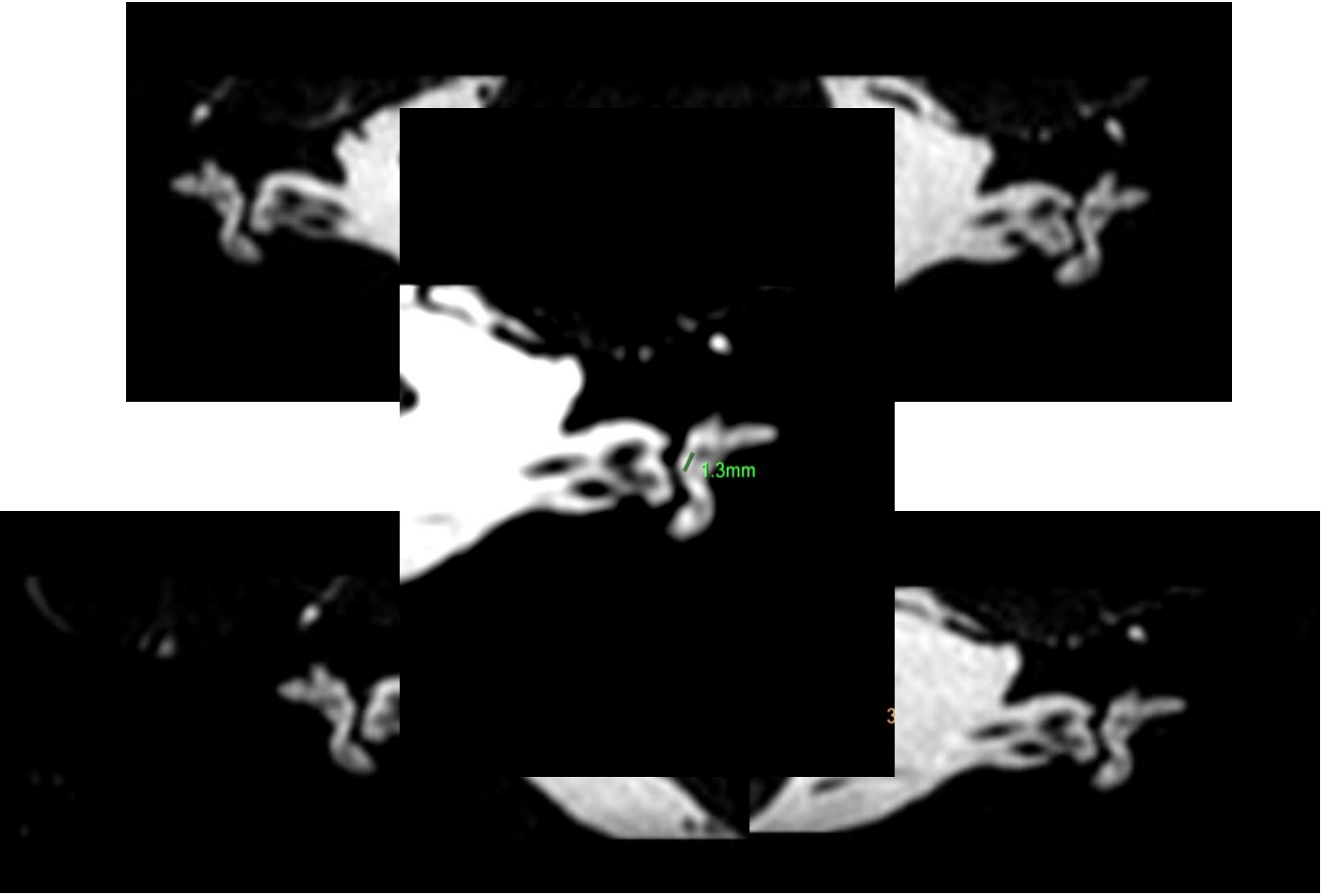

Saccule taille et morphologie normale en DRIVE !

Mr Lamb. Claude Sd menieriforme atypique gauche

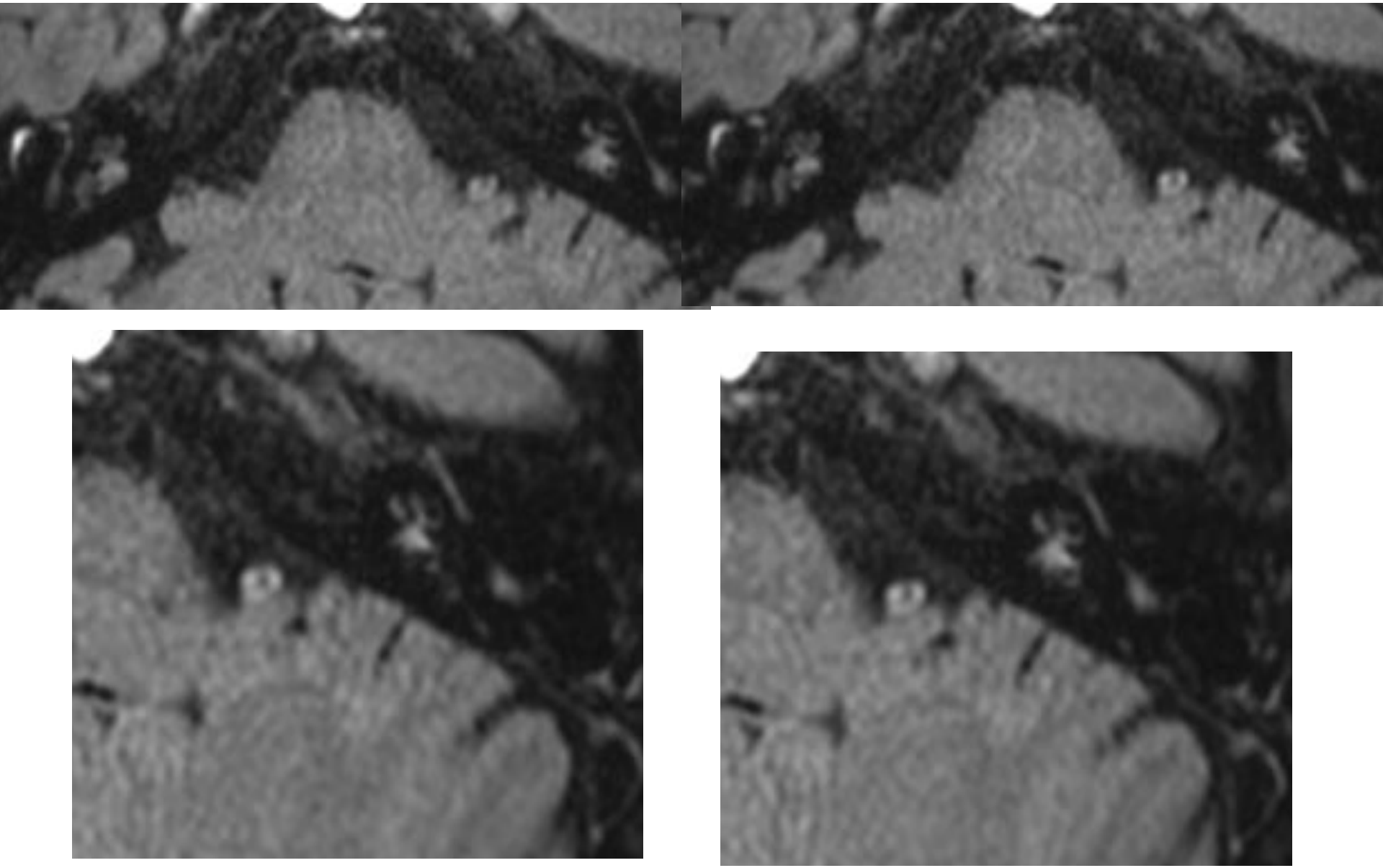

Mr Lamb. Claude Sd menieriforme atypique gauche

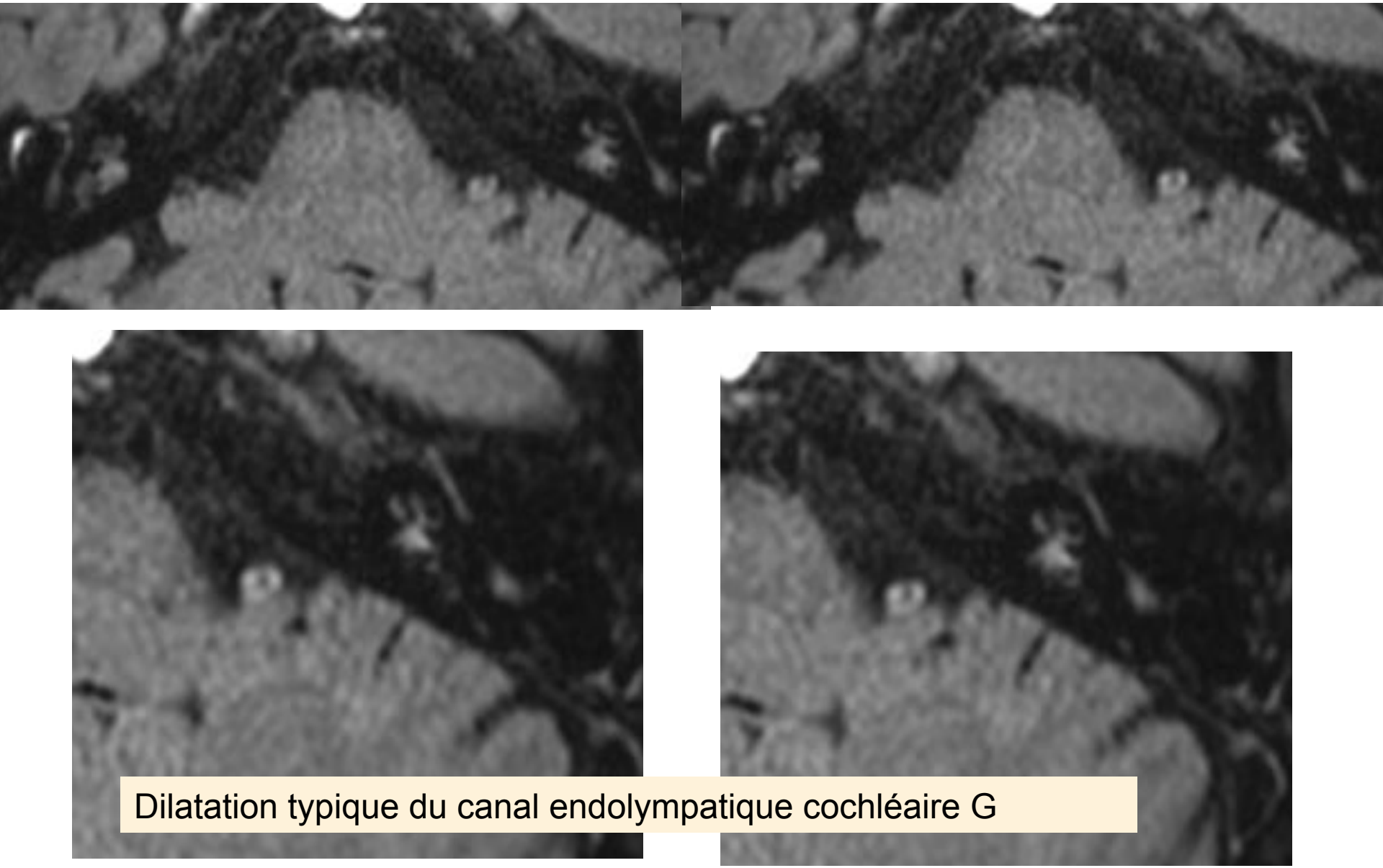

Dilatation typique du canal endolympatique cochléaire G

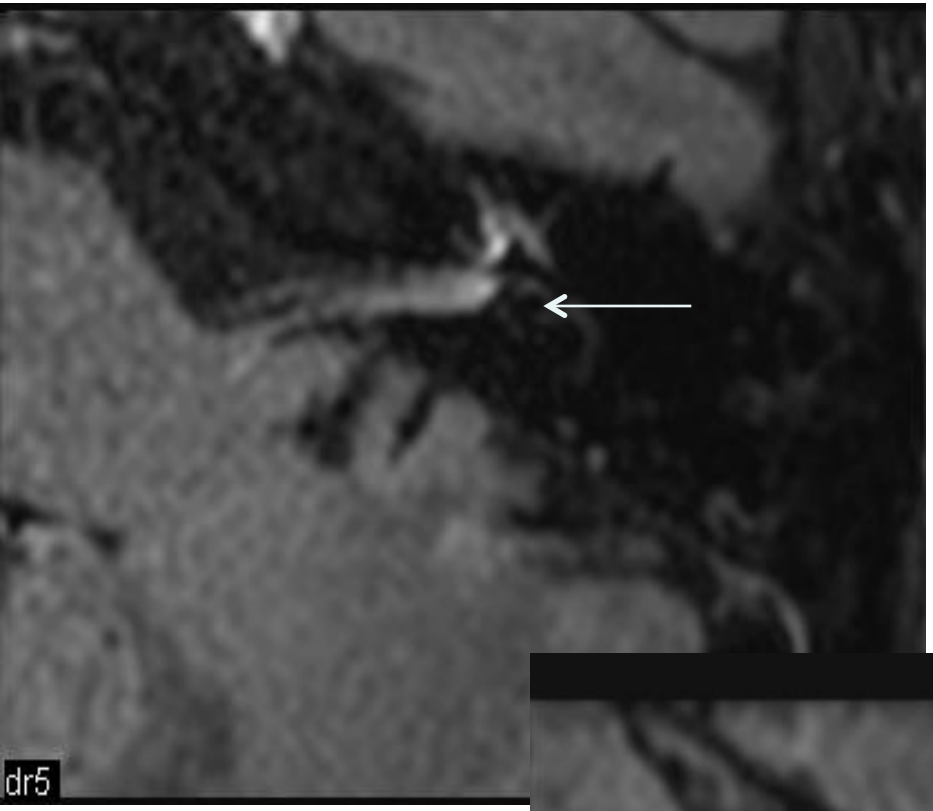

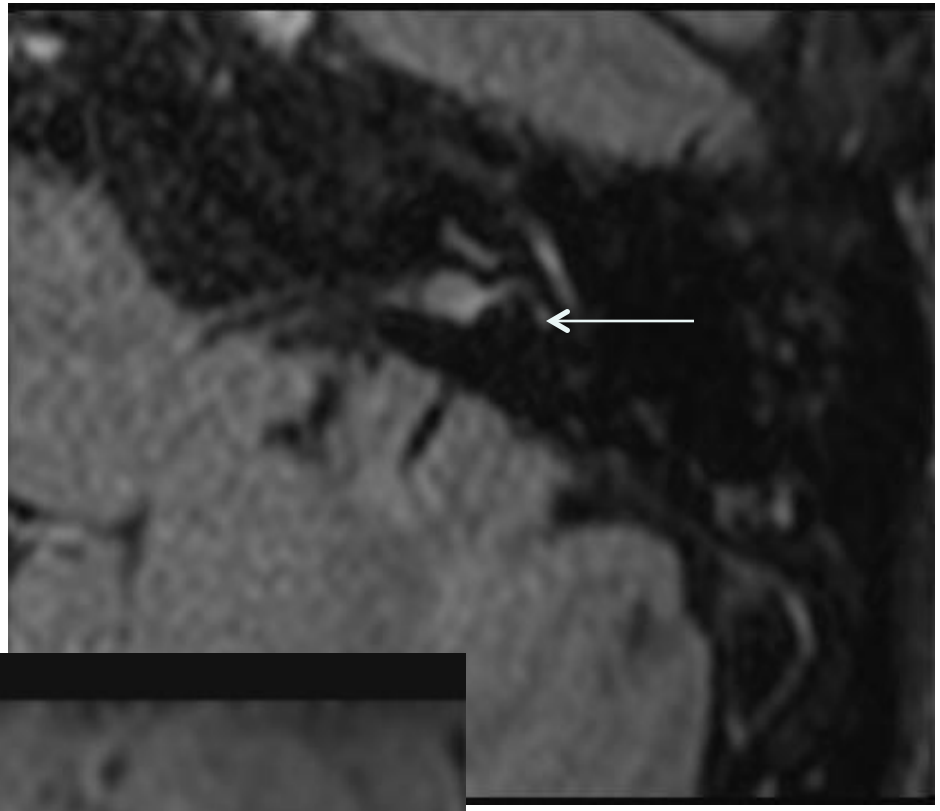

saccule>> utricule
SURI
> 50% du vestibule

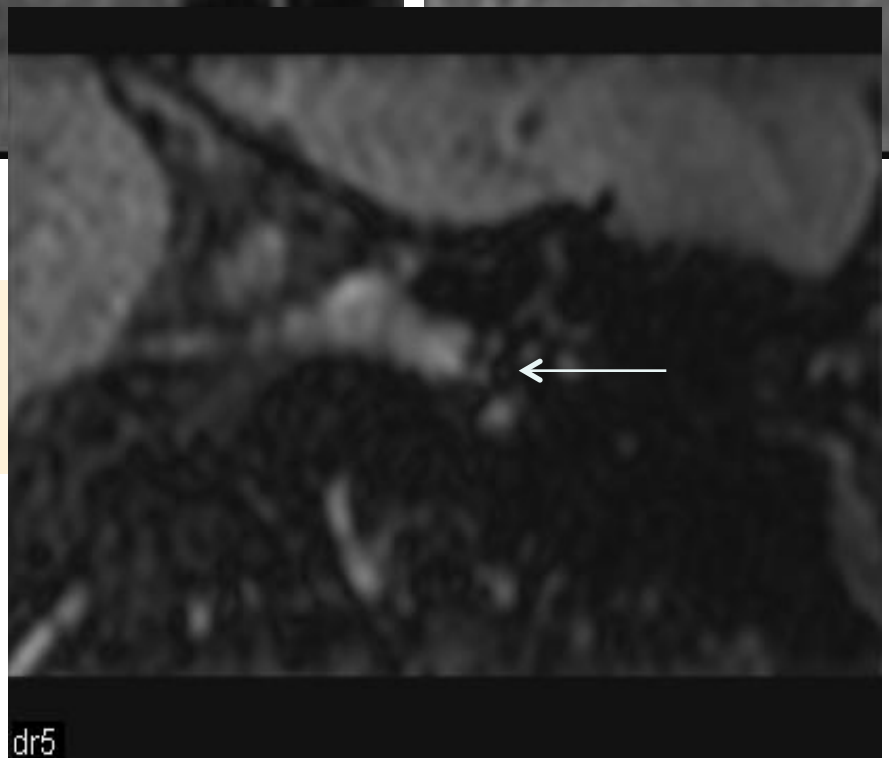

coronal

Endolymphatic hydrops and Ménière's disease: a lesion meta-analysis.

Pender DJ

J Laryngol Otol. 2014 Oct;128(10):859-65.

184 specimens demonstrating endolymphatic hydrops

93 patients

. 100%	cochlear duct
. 80%	saccule
. 55%	utricule
. 13%	ampullae

canal endocochléaire
↓
saccule
↓
utricule
↓
ampoules

La maladie a toujours commencé dans l'apex cochléaire, même dans les cas non symptomatiques, puis atteinte du saccule, puis de l'utricule, puis des ampoules et des canaux dans cet ordre précis

La progression de la lésion associée à la maladie de Ménière suggère que le processus d'hydrops a un effet non aléatoire gradué sur le labyrinthe. Ces résultats suggèrent un système de stadification pathologique qui peut être utile dans l'évaluation de l'os temporal.

- **critères de Naganawa**

  - **hydrops vestibulaire** si plus d'1/3 d'endolymphe dans le vestibule

  - **hydrops cochléaire** si au moins une localisation visible de dilatation nodulaire

- **critères de Attyé**

  (population témoin)

  - **hydrops vestibulaire** si saccule plus gros que l'utricule **SURI et endolymphe > 50%**

  - **hydrops cochléaire** si au moins 2 localisations nodulaires dans la cochlée

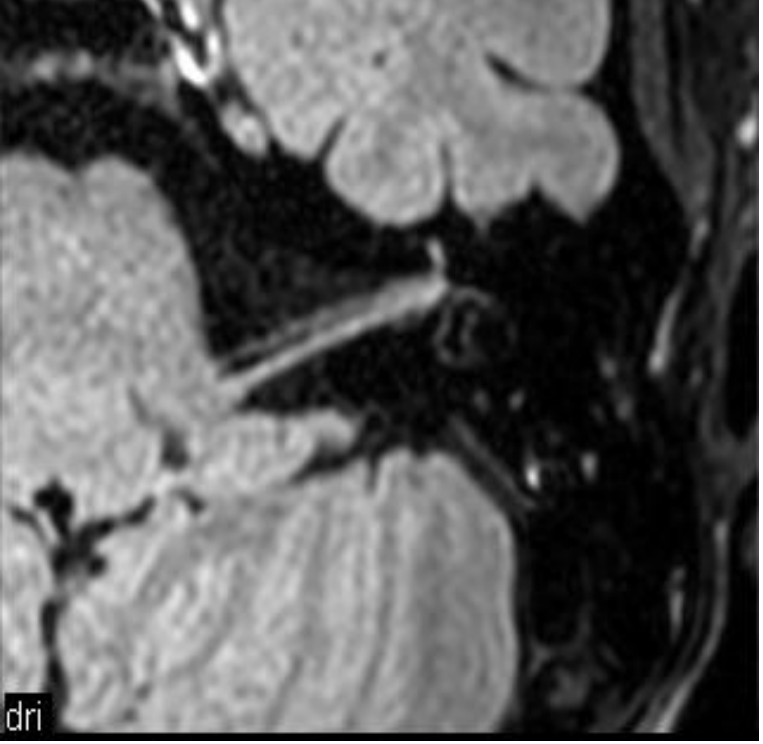

Patient de 32 ans
vertiges et
acouphène gauche
Pas de surdité

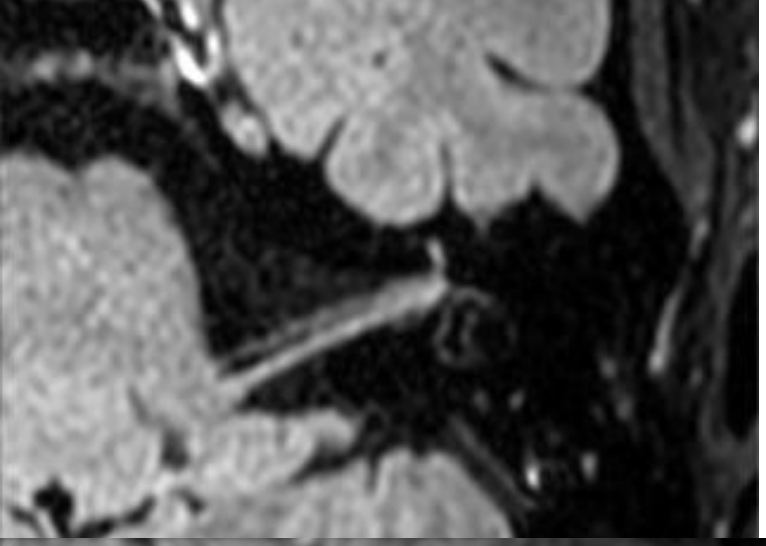

Patient de 32 ans
vertiges et
acouphène
gauche
Pas de surdité

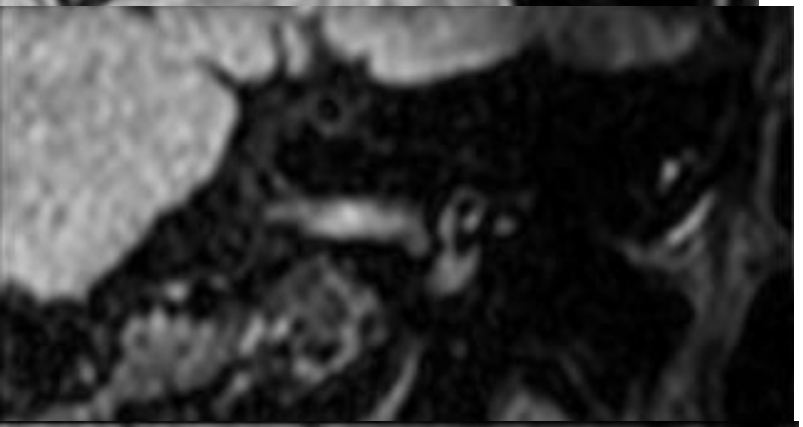

coronal

coronal

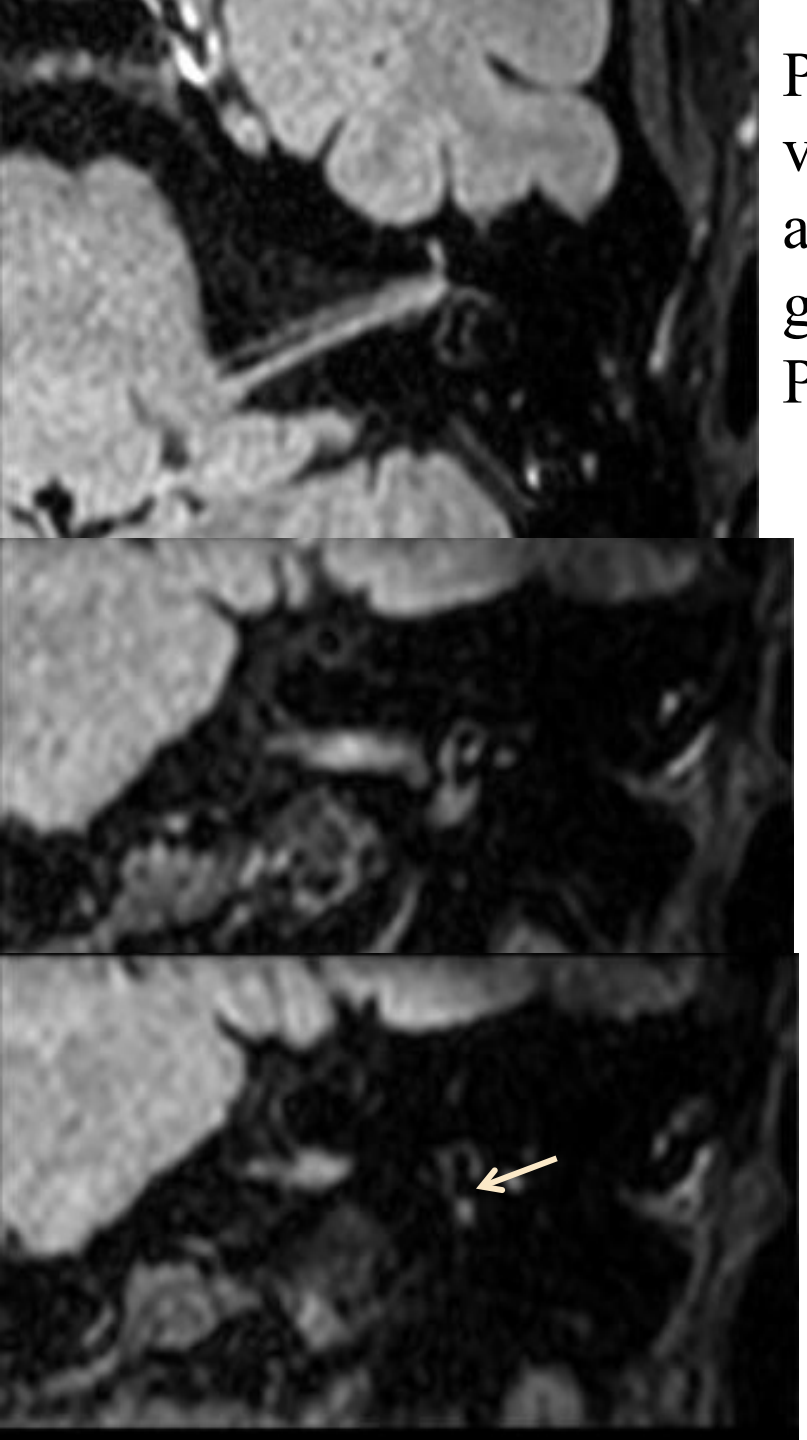

Patient de 32 ans
vertiges et
acouphène
gauche
Pas de surdité

inversion du
rapport
sacculo-
utriculaire
SURI

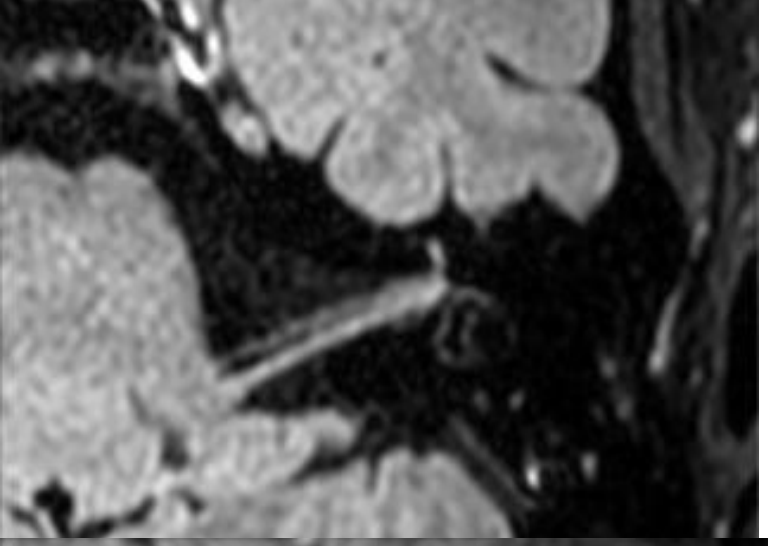

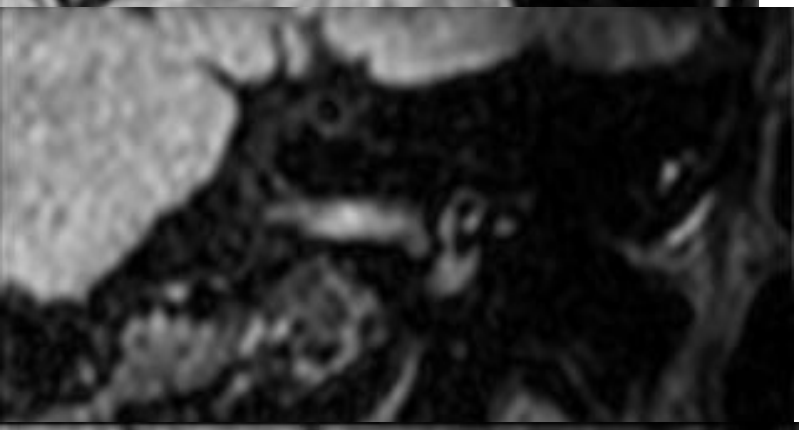

Patient de 32 ans
vertiges et
acouphène
gauche
Pas de surdité

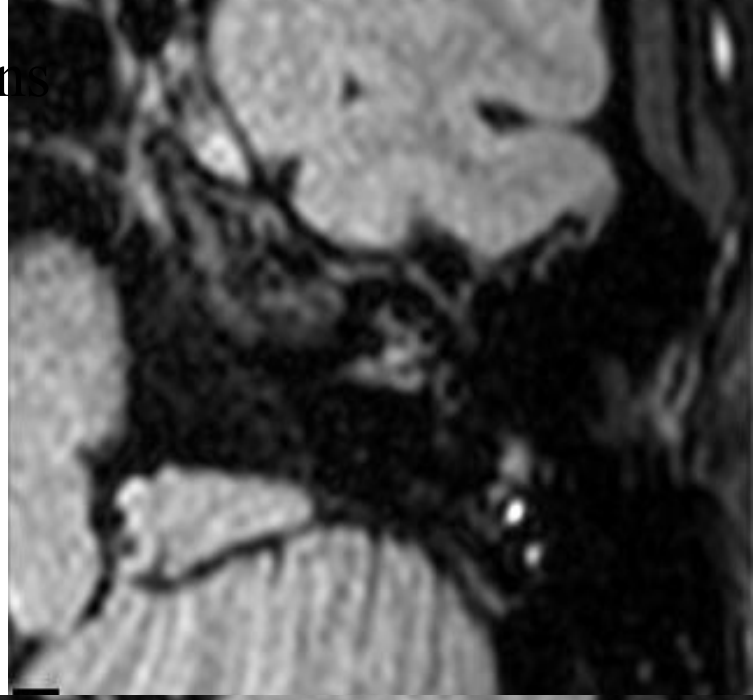

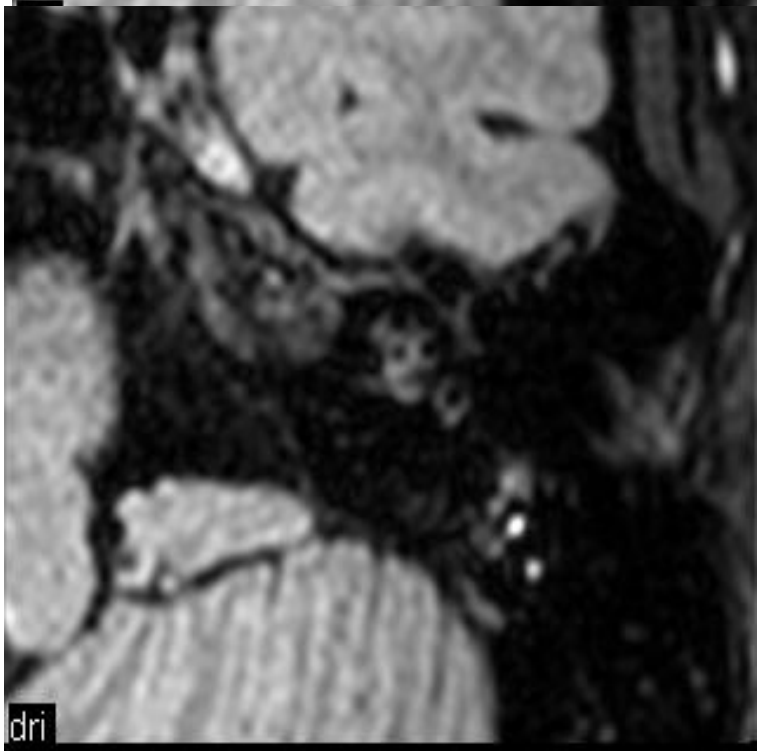

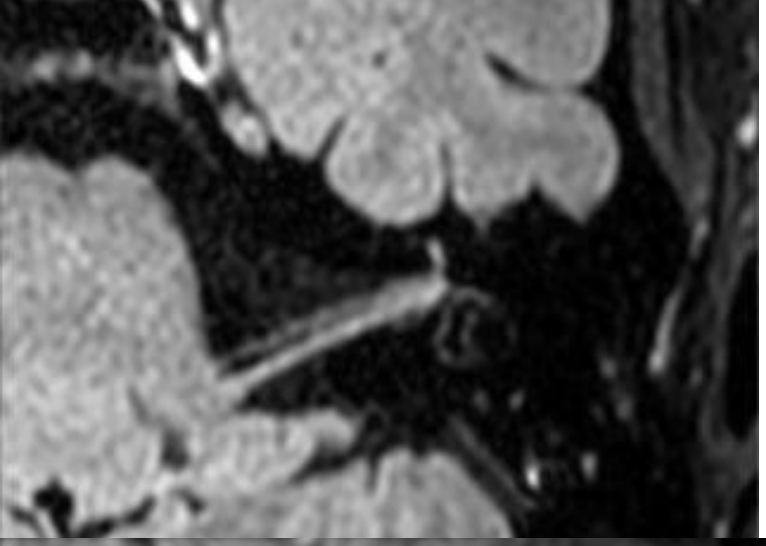

Patient de 32 ans
vertiges et
acouphène
gauche
Pas de surdité

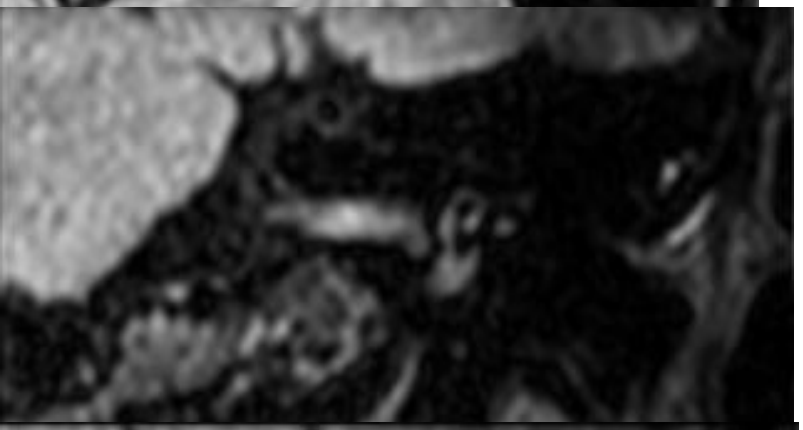

dilatation nette
du canal
endolyphatique
cochléaire

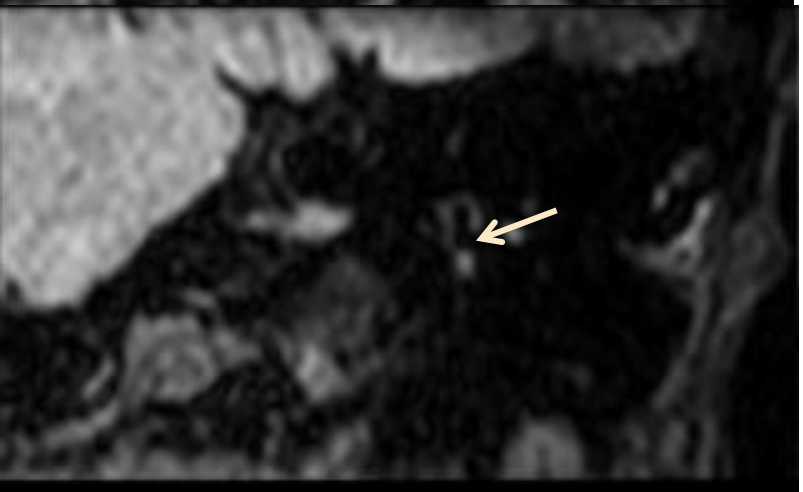

+ de 2
localisations
nodulaires
dans la
cochlée

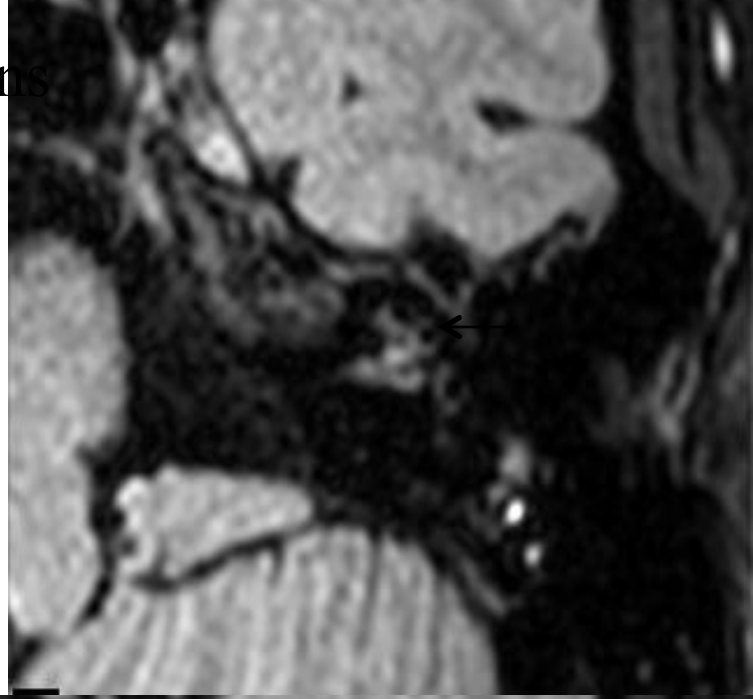

Patient de 55 ans
Vertiges atypiques + surdité de perception modérée prédominant à G + acouphène G intermittent

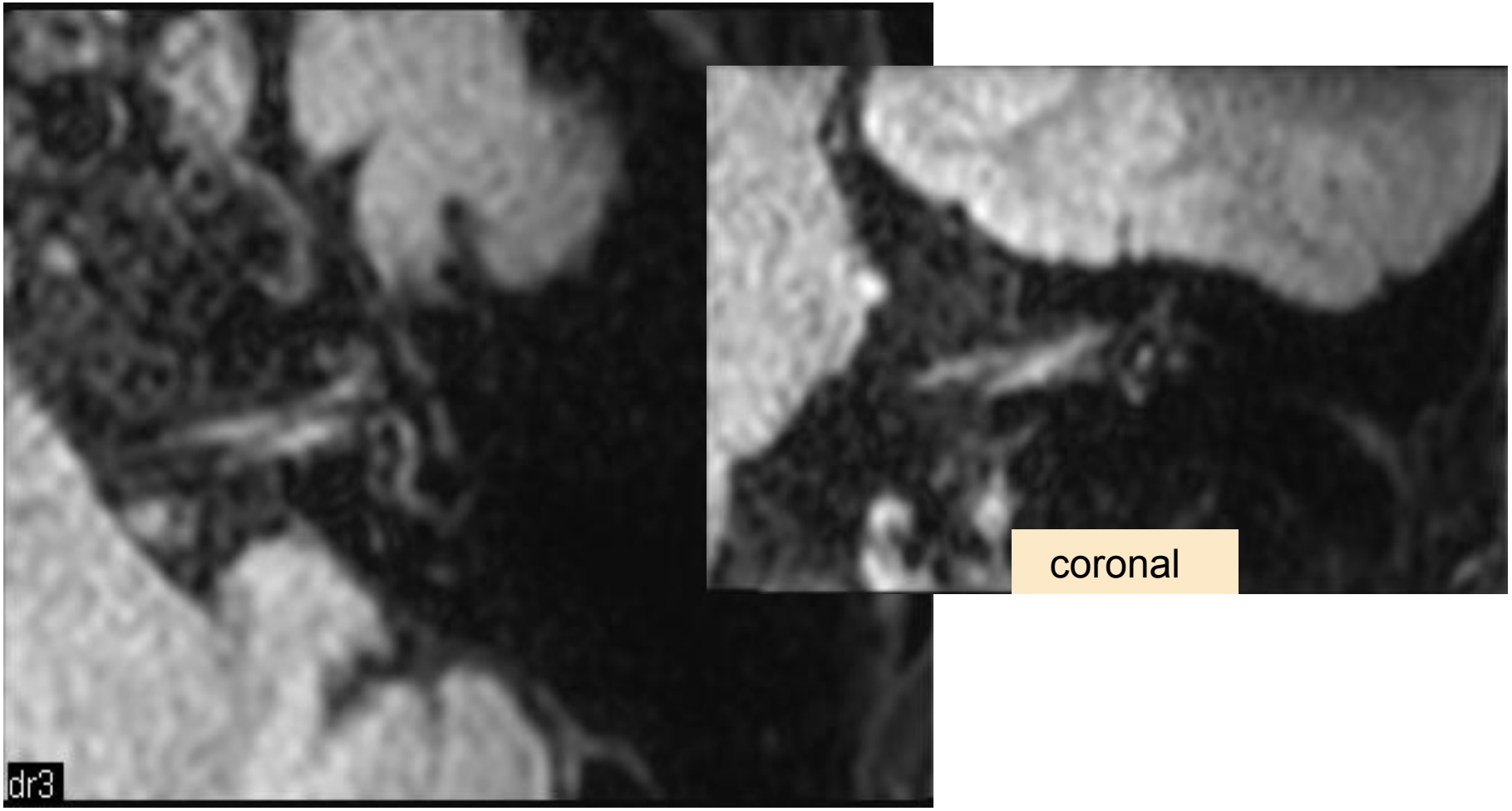

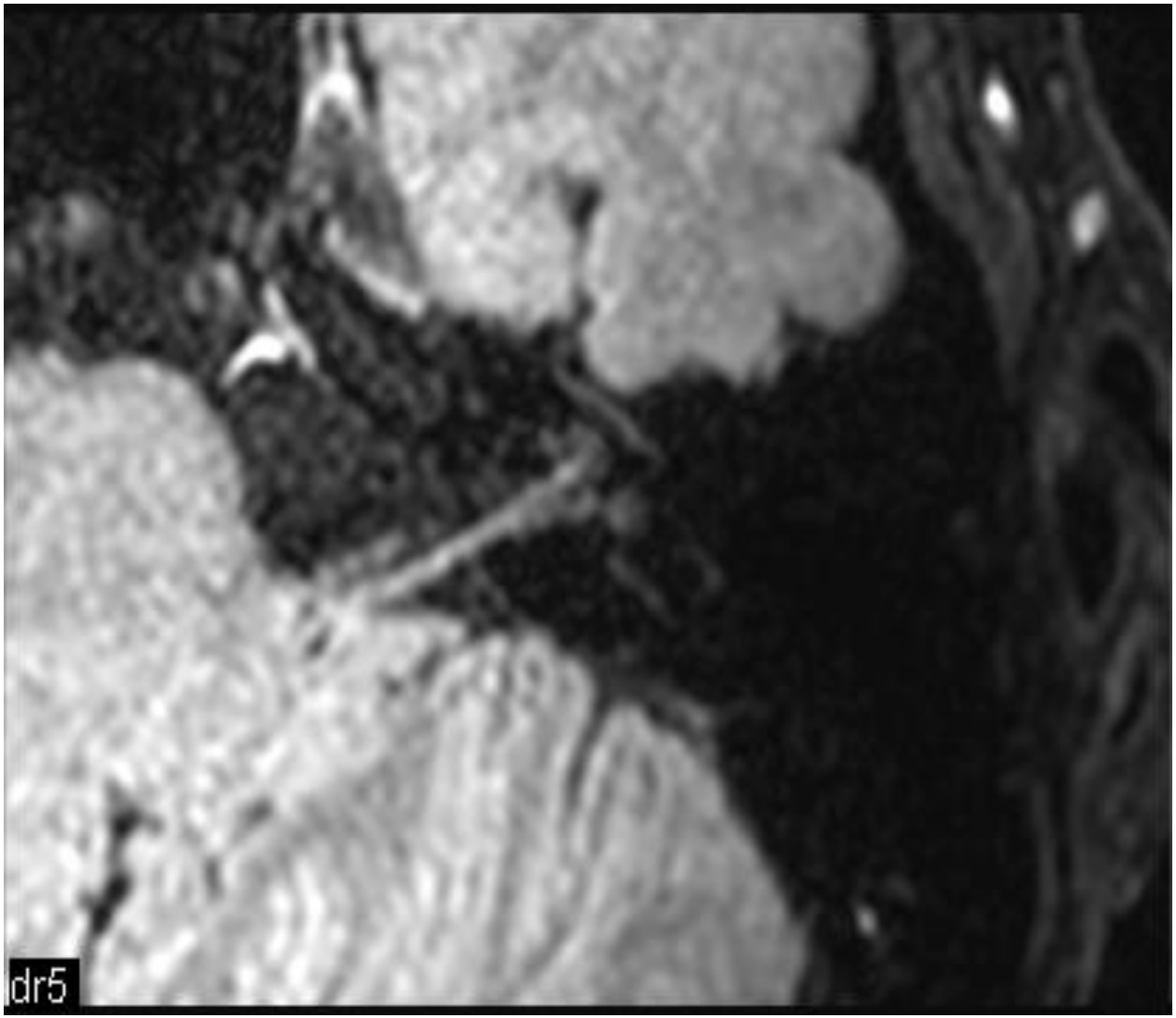

Canal endolymphatique cochléaire G quasiment pas visible

Conclusion: pas de critère d'hydrops

Ne pas oublier de regarder
la séquence 3D HR T2

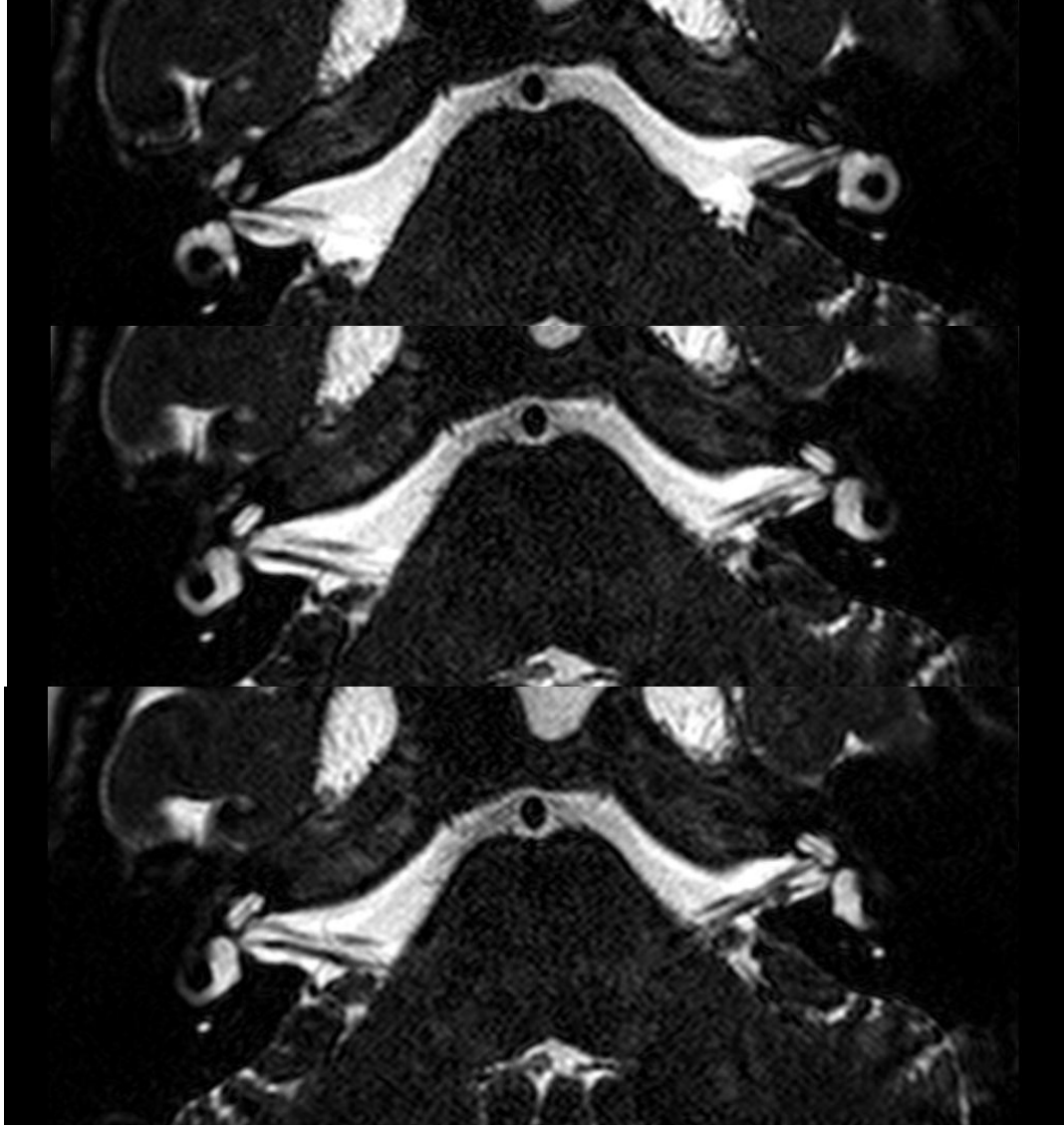

Schwannome vestibulaire inférieur

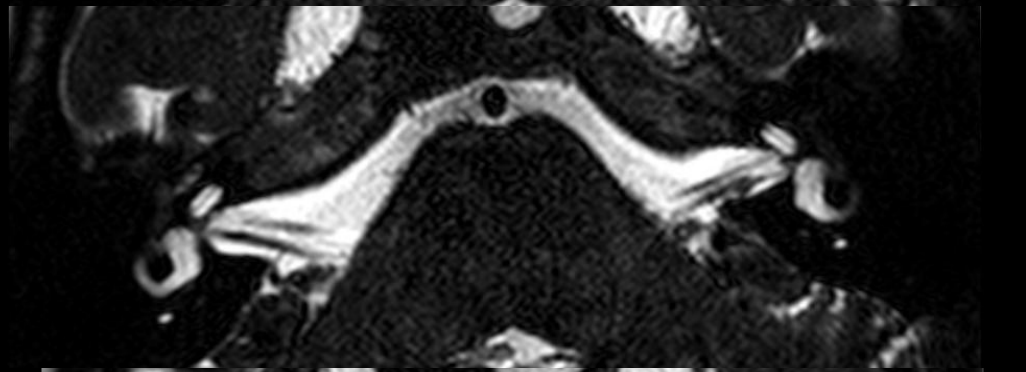

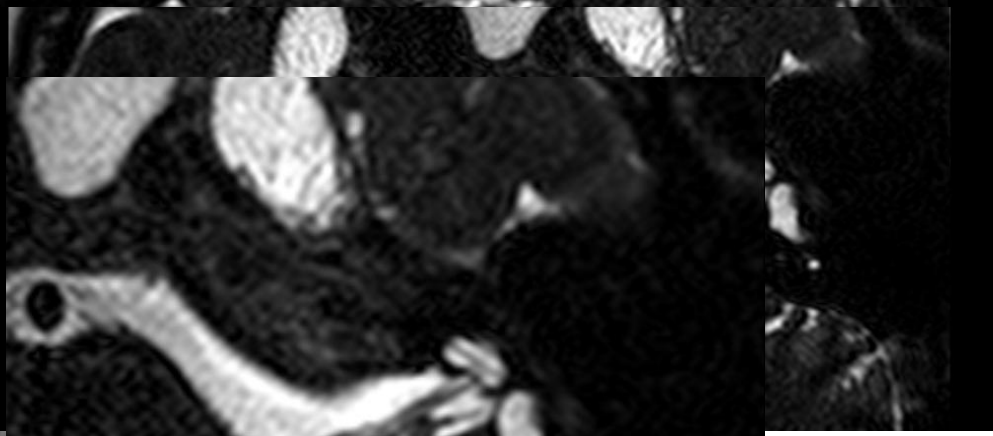

qualité insuffisante du FLAIR HR à 1.5 T

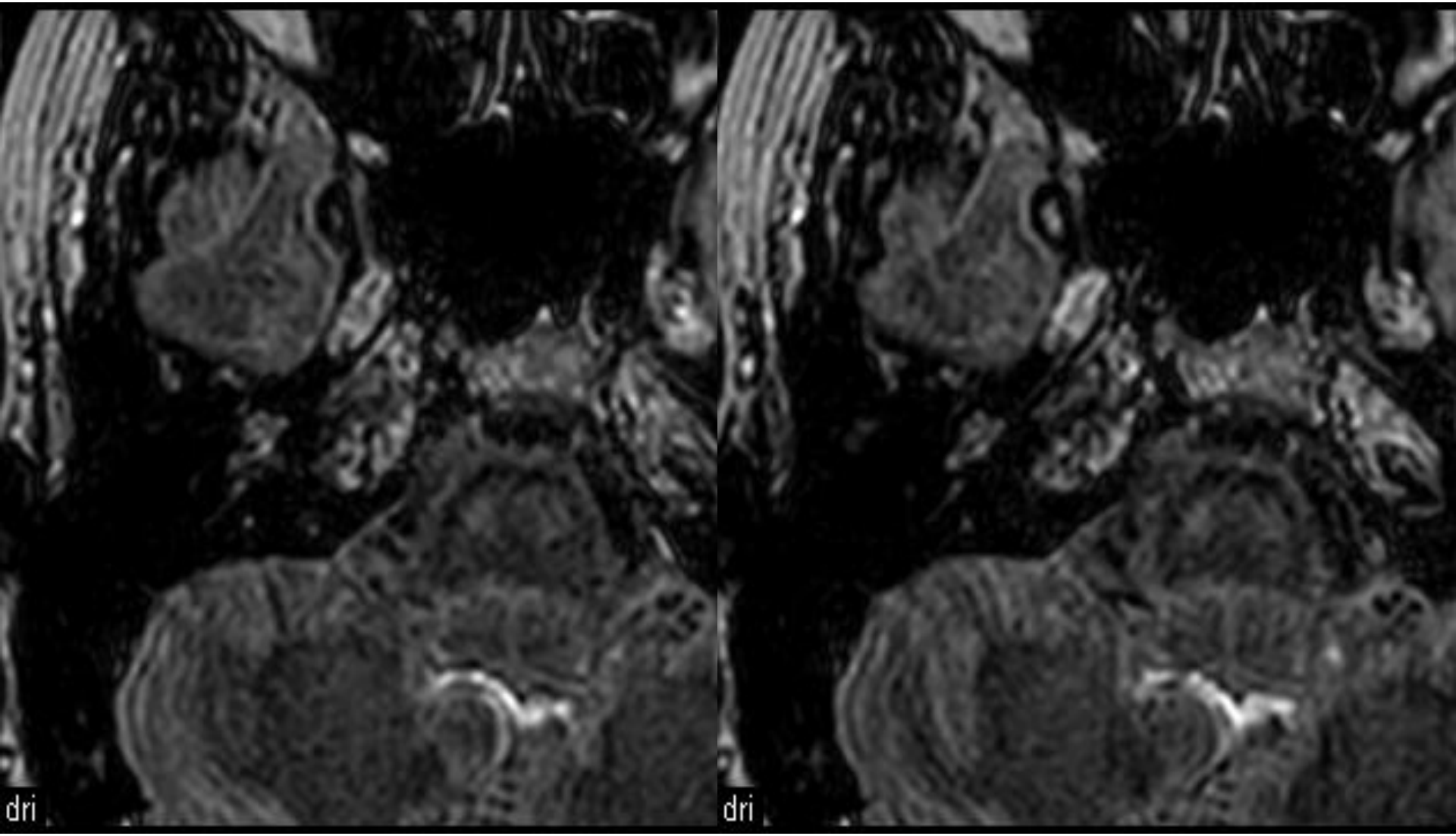

Loic Gaillandre
Siemens 1,5T – antenne de surface
Acquisition en coronal direct

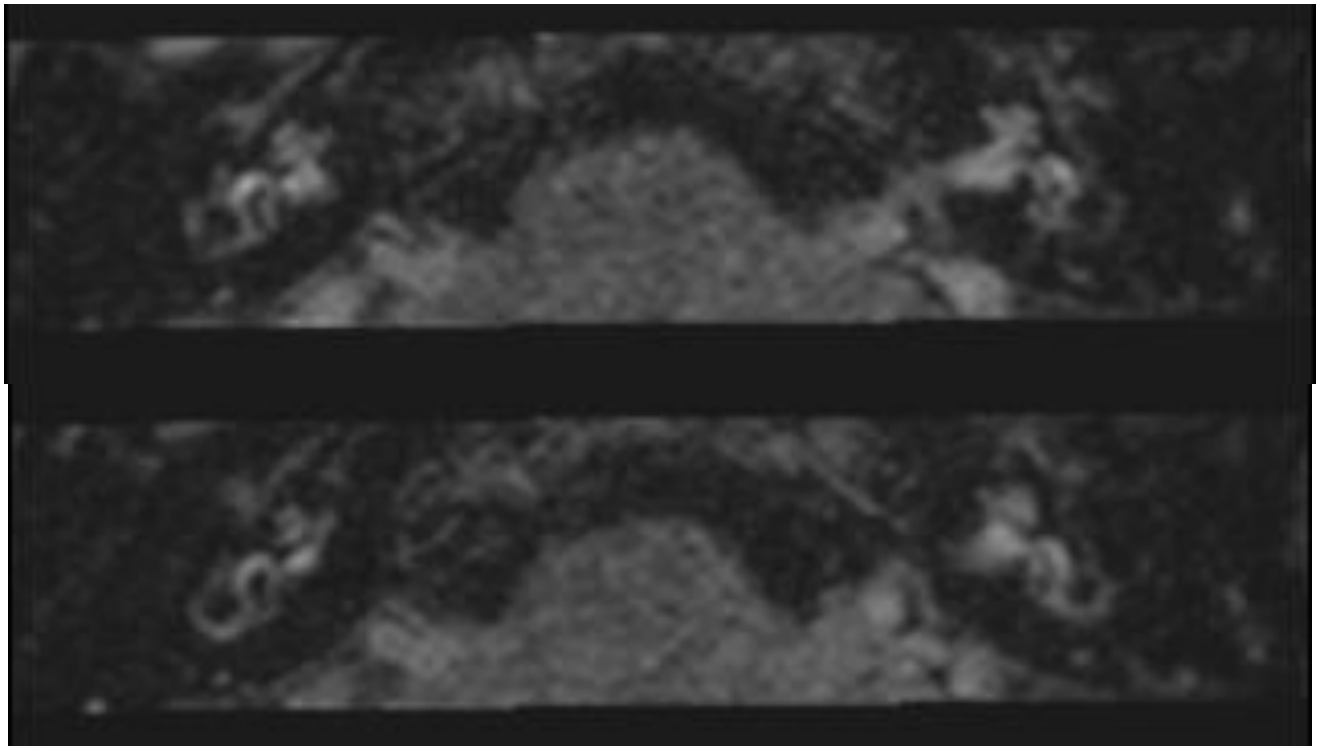

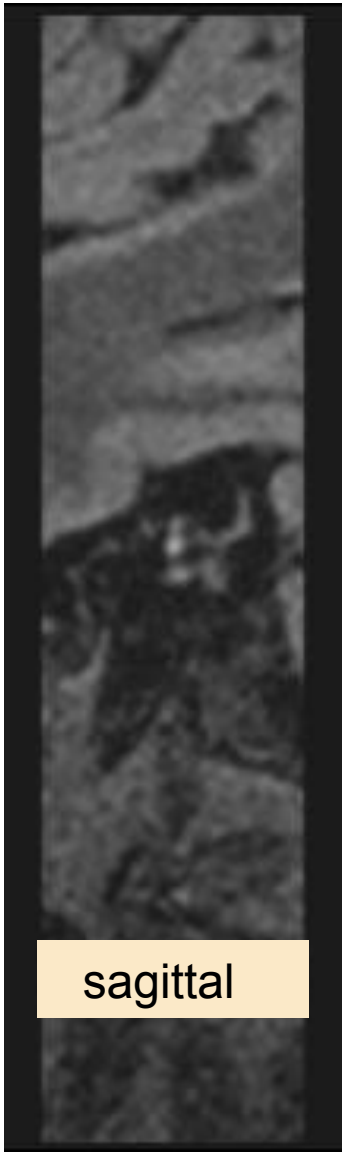

Mme Dese..Jeannine 69 ans

surdité de perception droite, acouphènes droits et vertiges

envoyée pour recherche d’hydrops

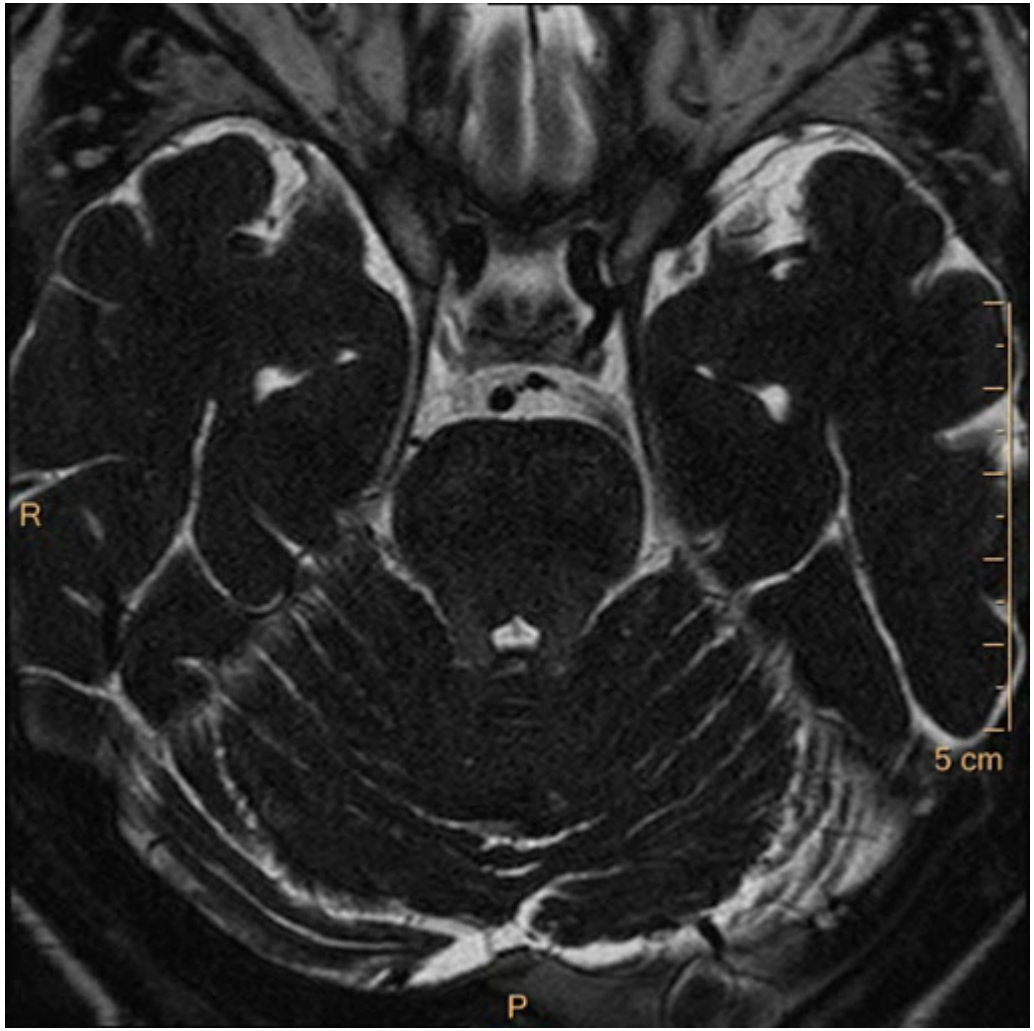

Mme Dese..Jeannine 69 ans

surdité de perception droite, acouphènes droits et vertiges

envoyée pour recherche d’hydrops

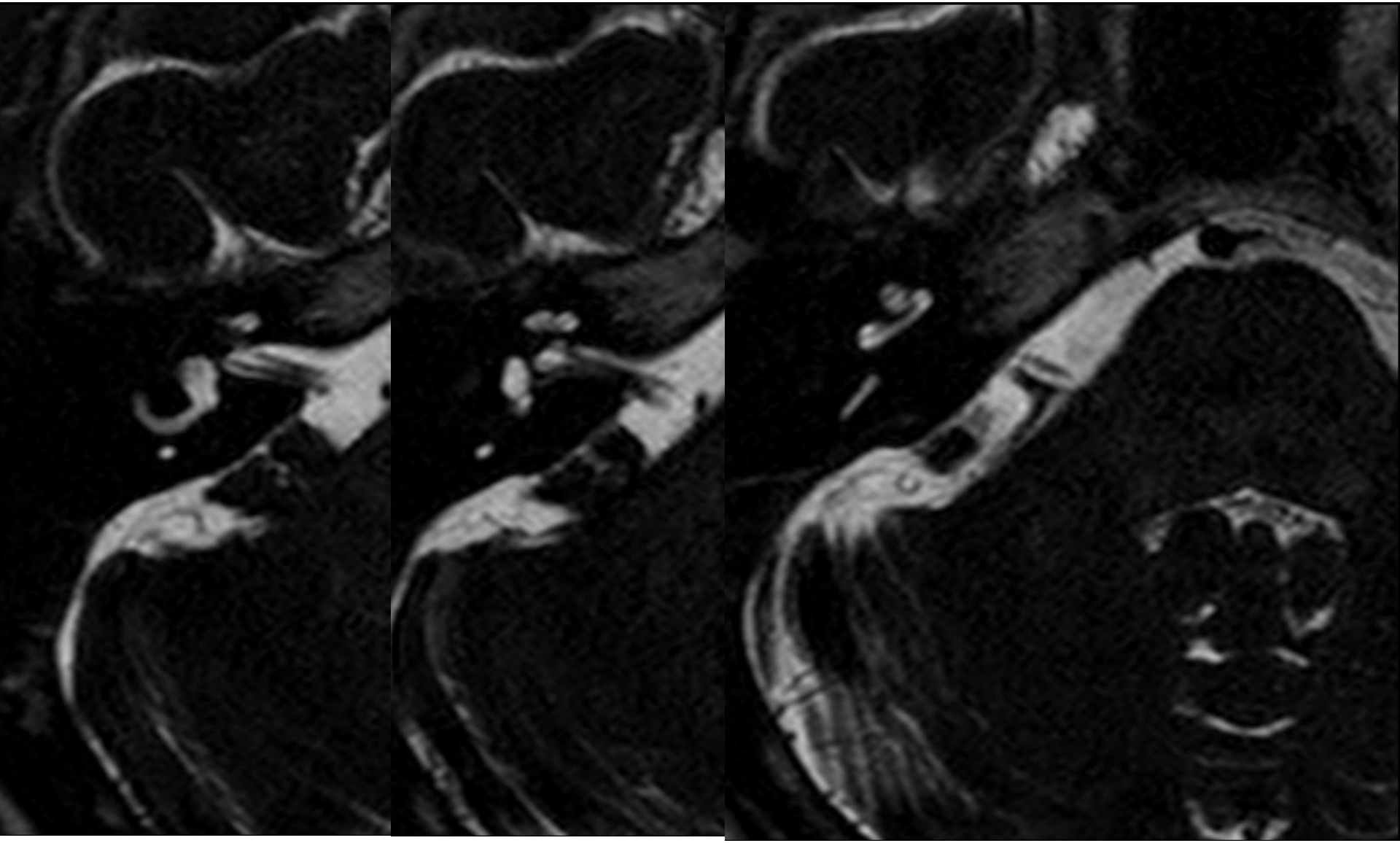

Mme Dese..Jeannine 69 ans

surdité de perception droite, acouphènes droits et vertiges

envoyée pour recherche d’hydrops

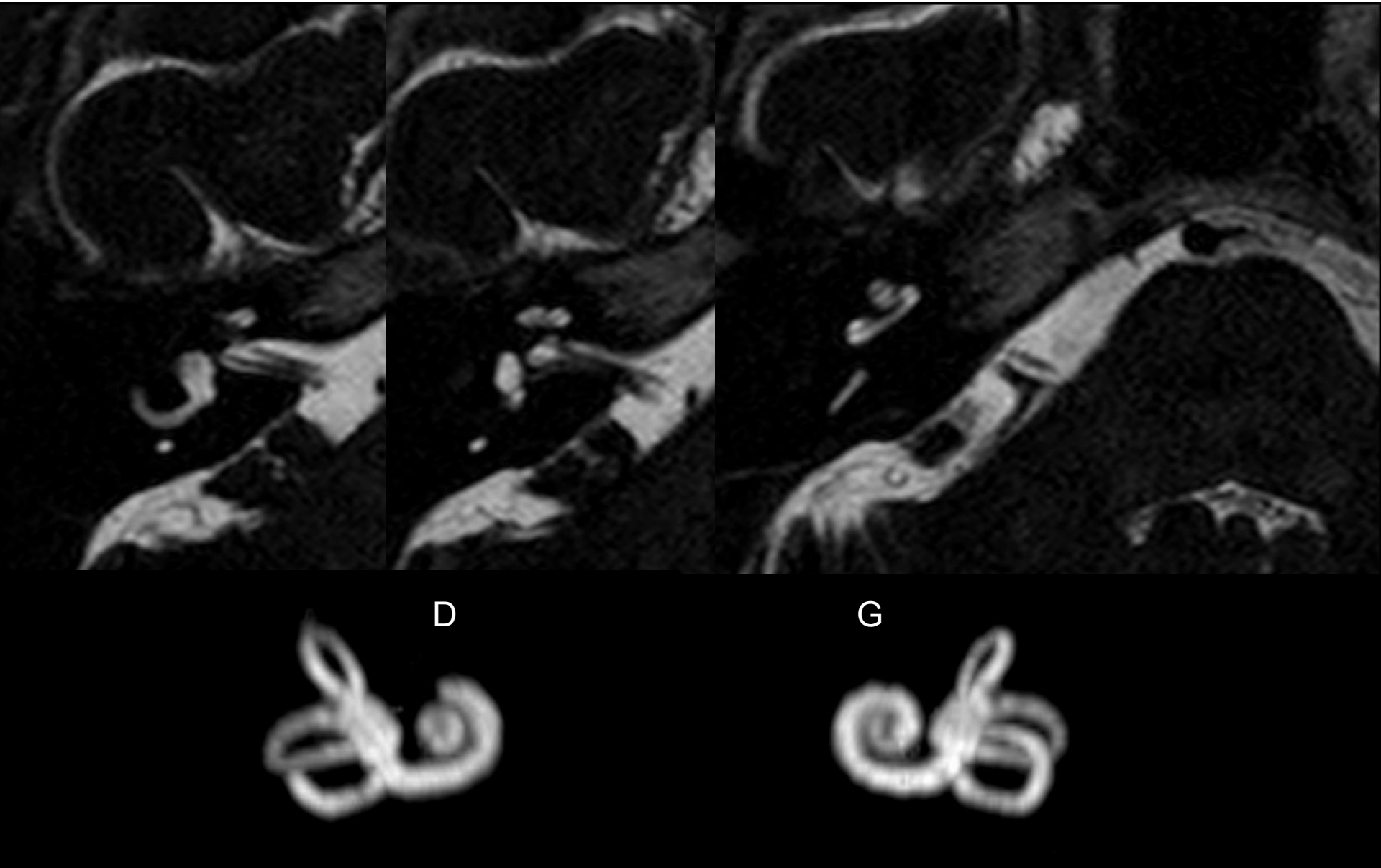

Mme Dese..Jeannine 69 ans

surdité de perception droite, acouphènes droits et vertiges

envoyée pour recherche d’hydrops

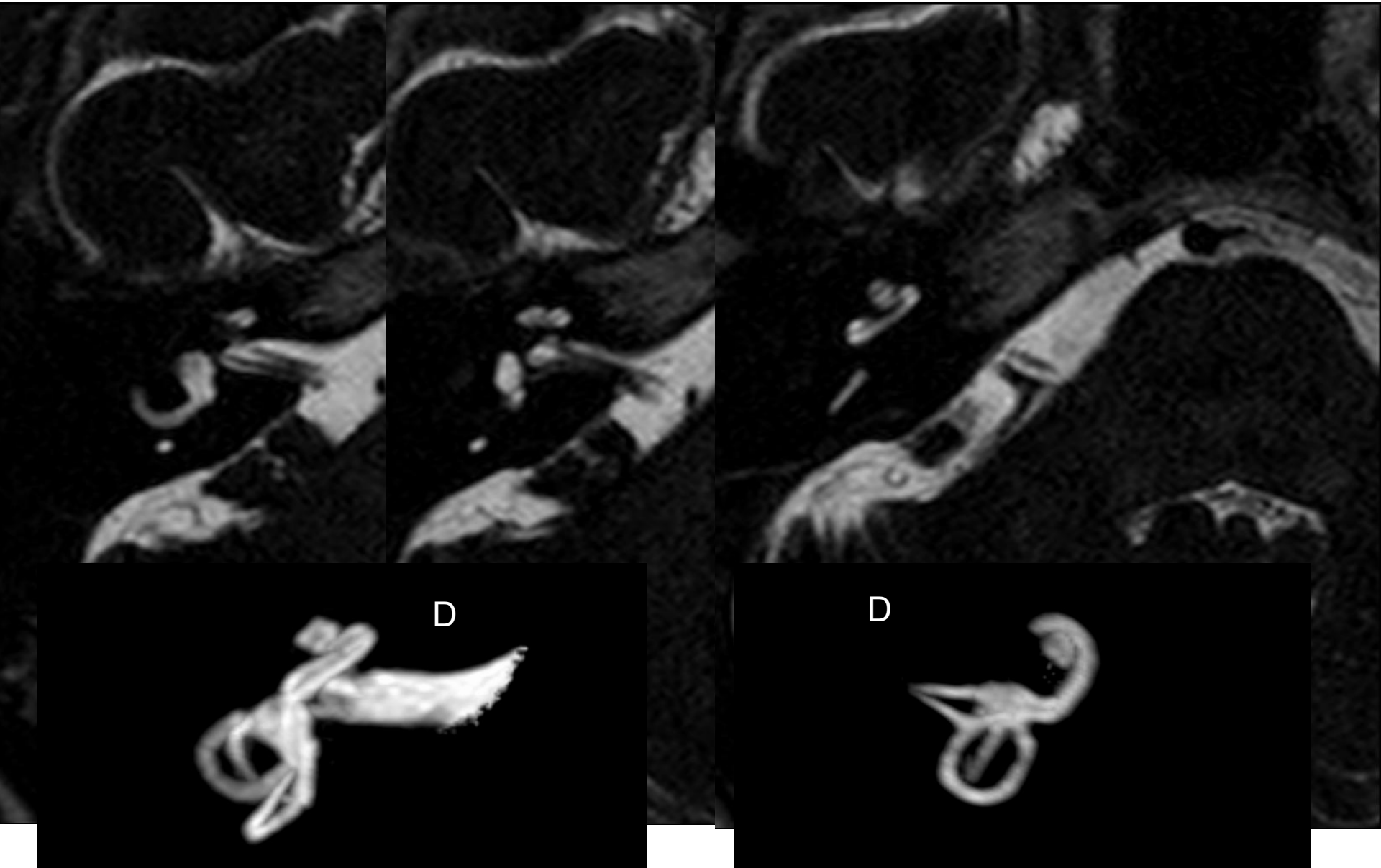

Mme Dese..Jeannine 69 ans

surdité de perception droite, acouphènes droits et vertiges

envoyée pour recherche d’hydrops

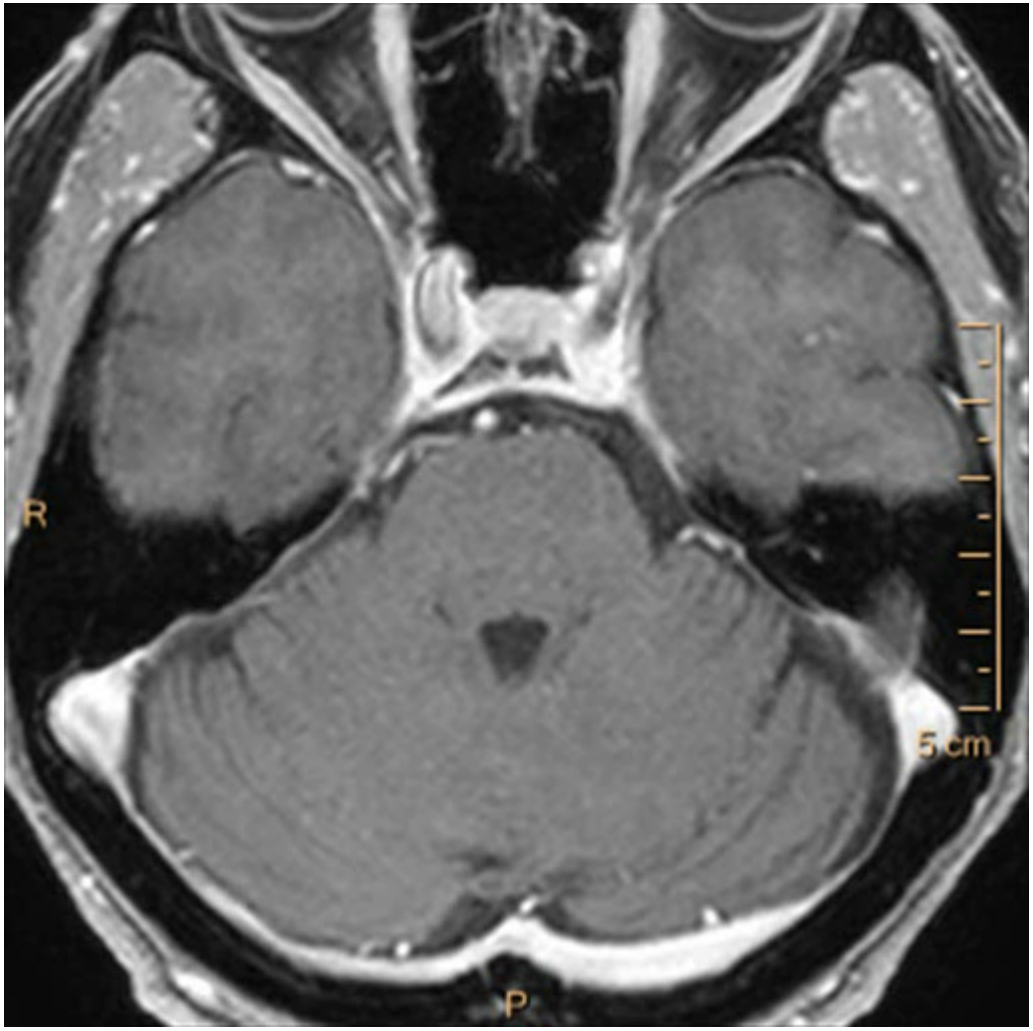

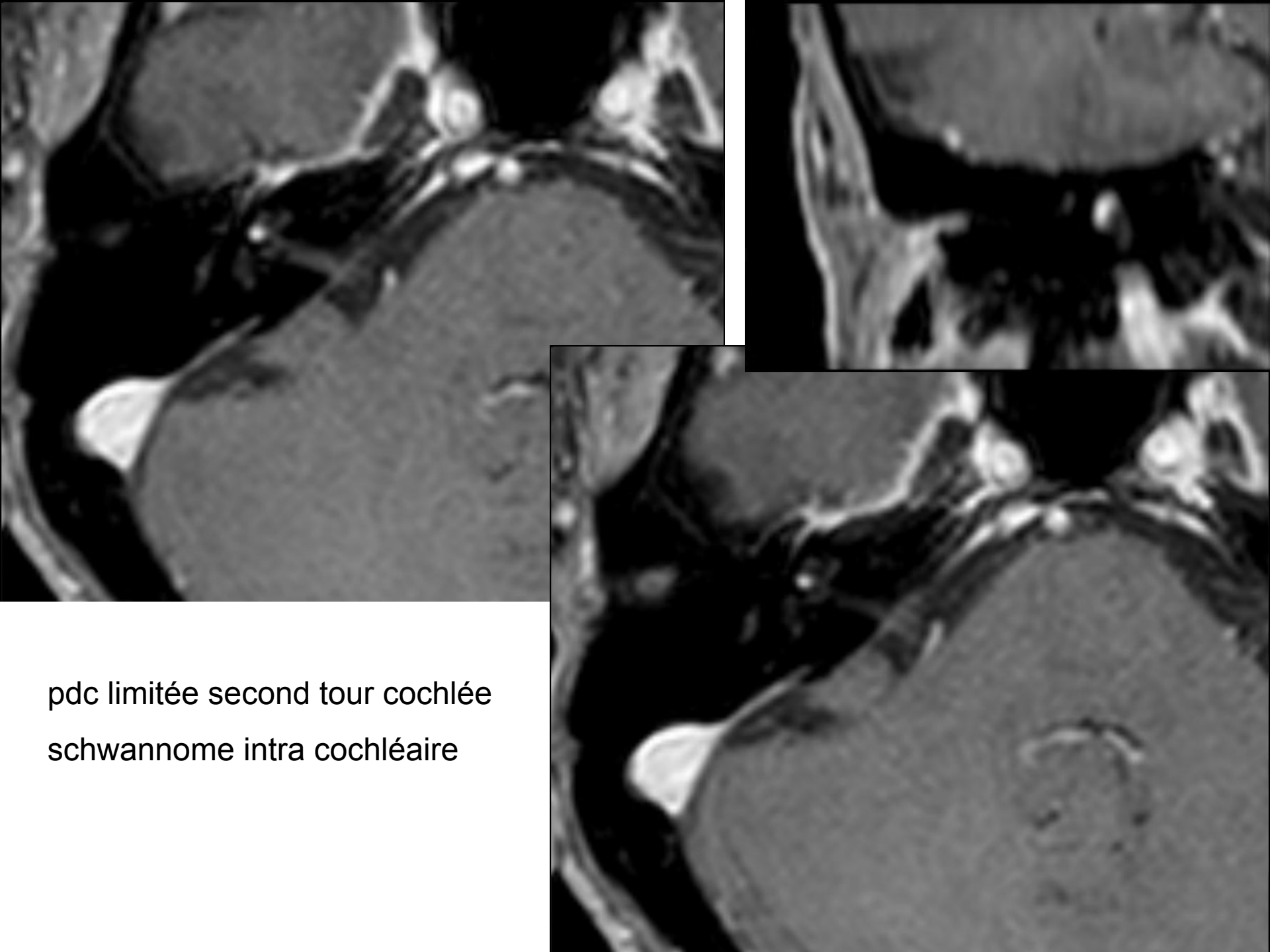

pdc limitée second tour cochlée

schwannome intra cochléaire

Patiente de 48 ans

vertiges et acouphènes droit

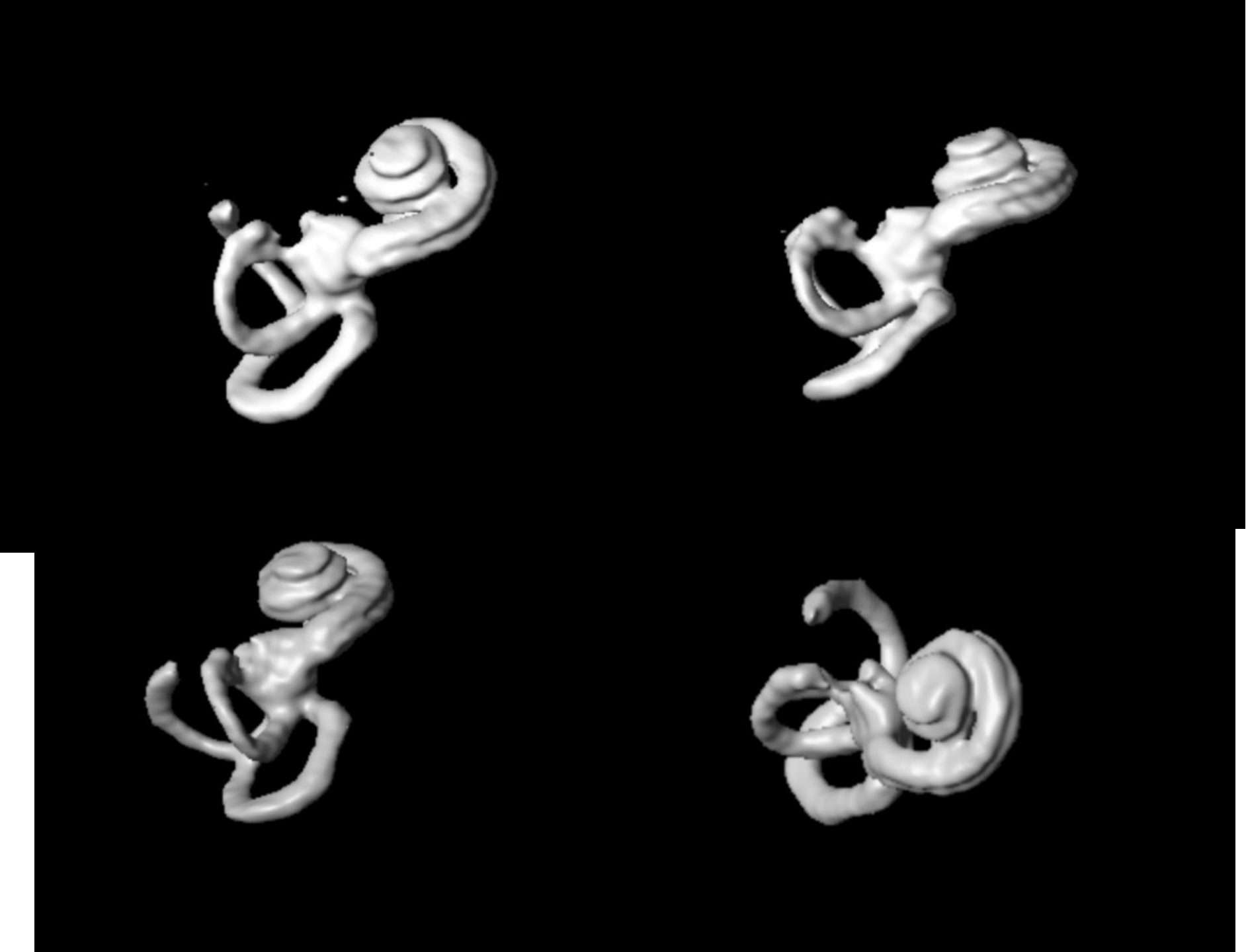

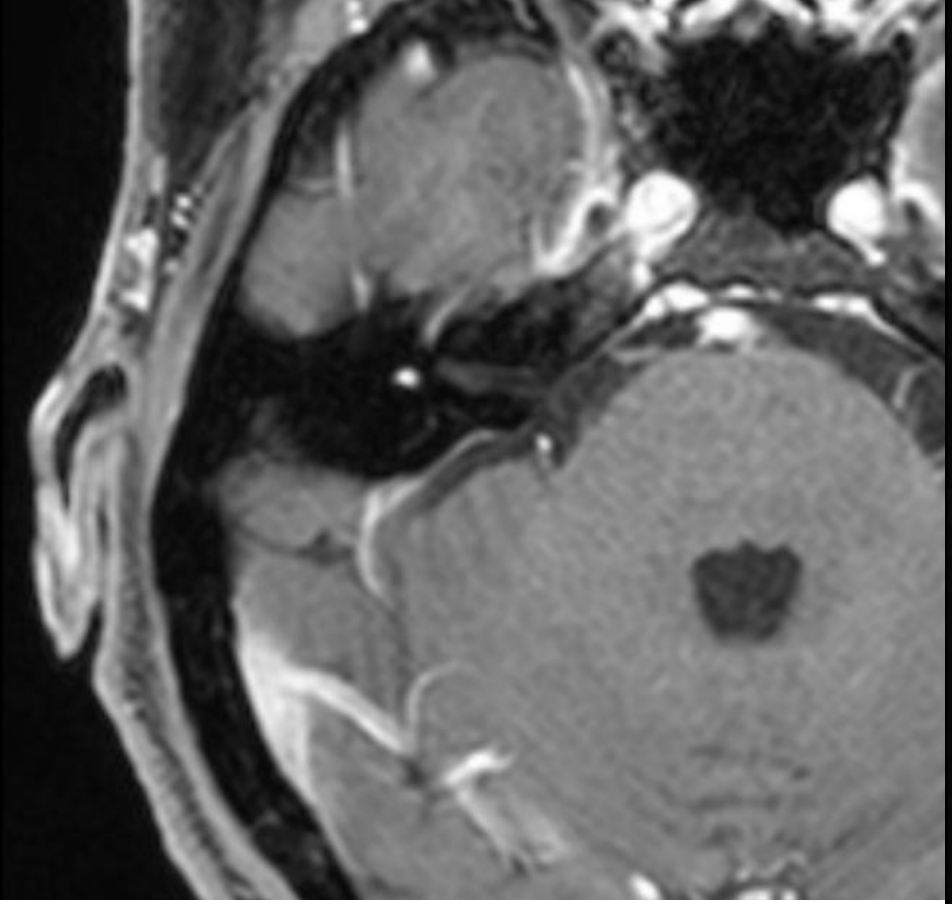

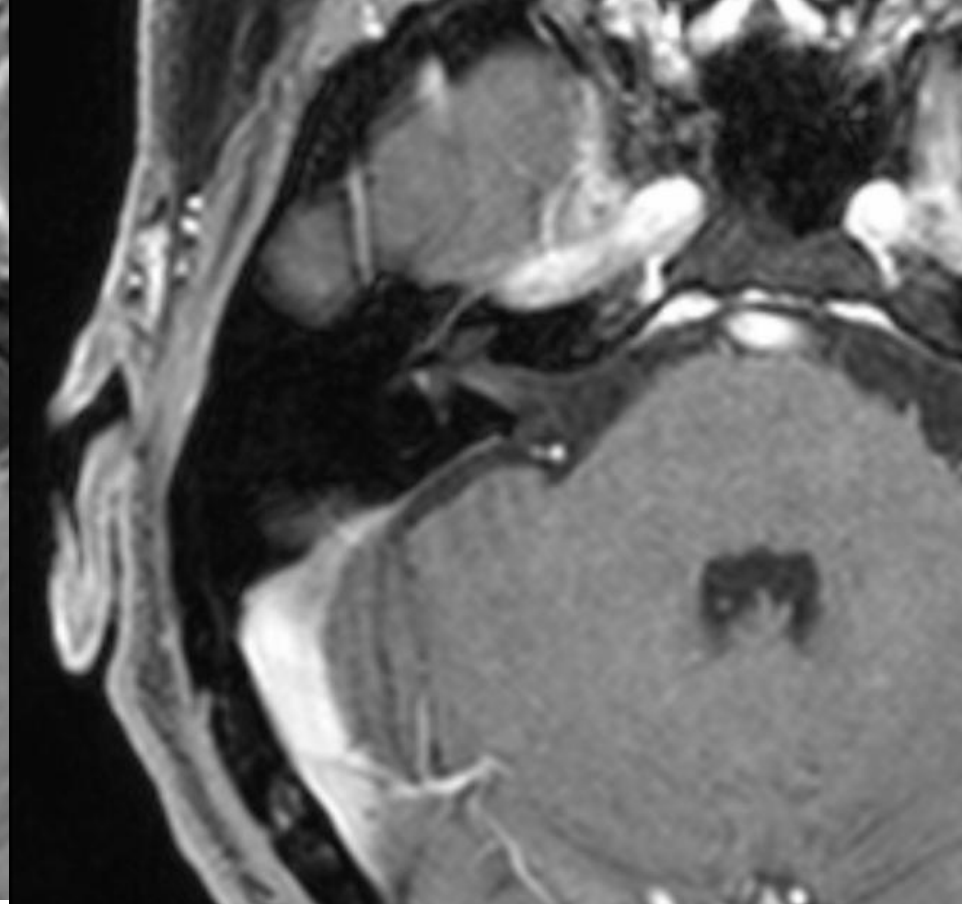

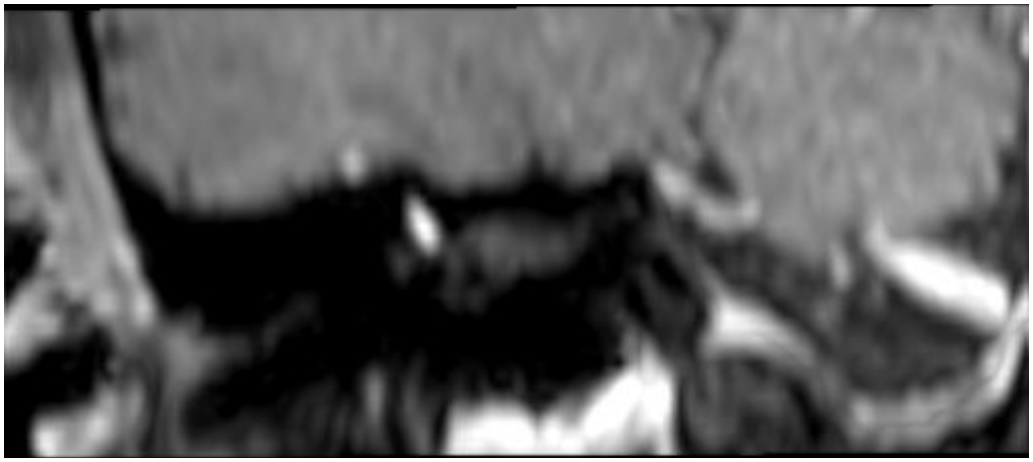

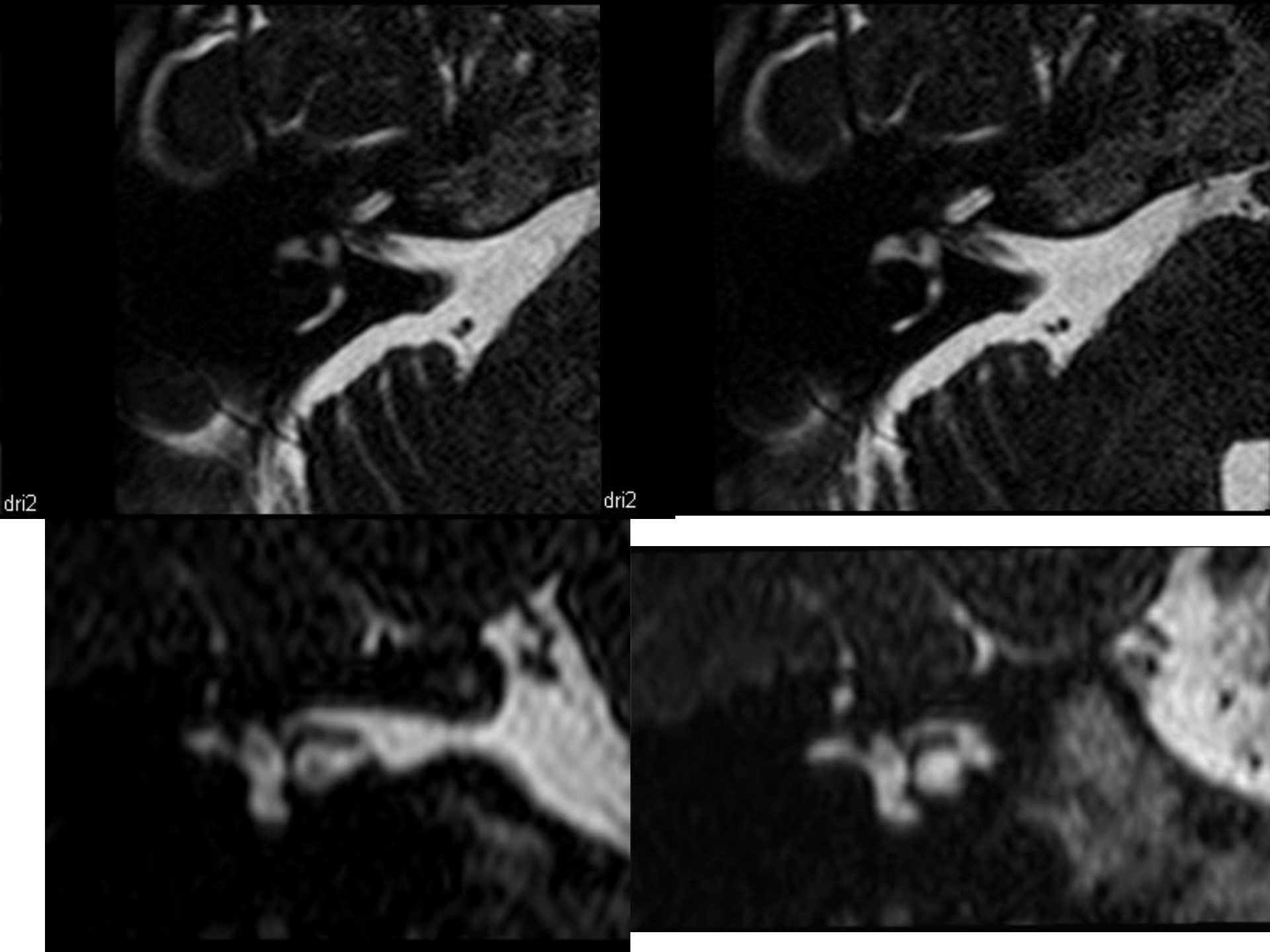
dri2
dri2

schwannome partie haute du vestibule et ampoule du CSS supérieur droit

sur la macule ampullaire ?

Patiente 55 ans

vertiges et surdité de perception gauche

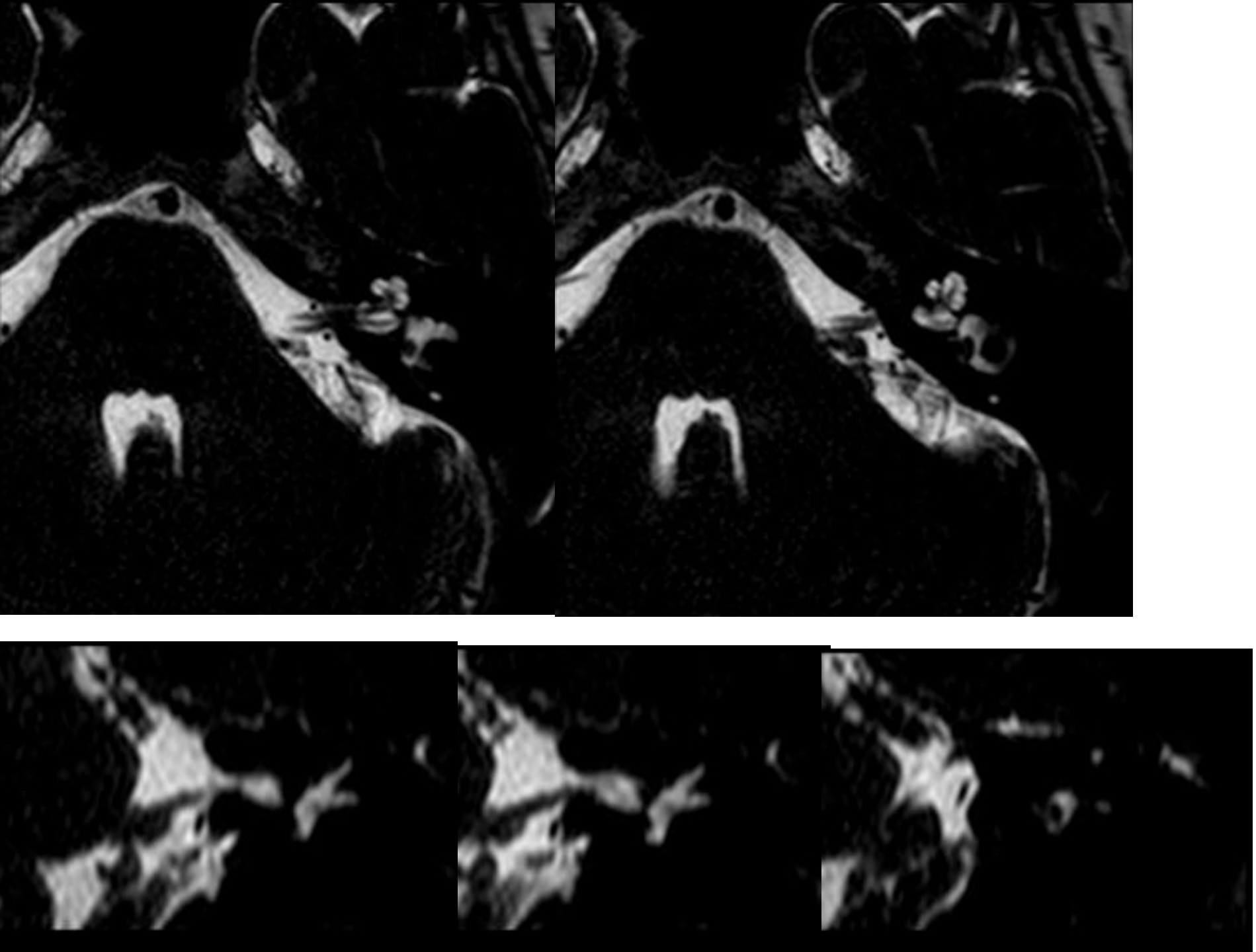

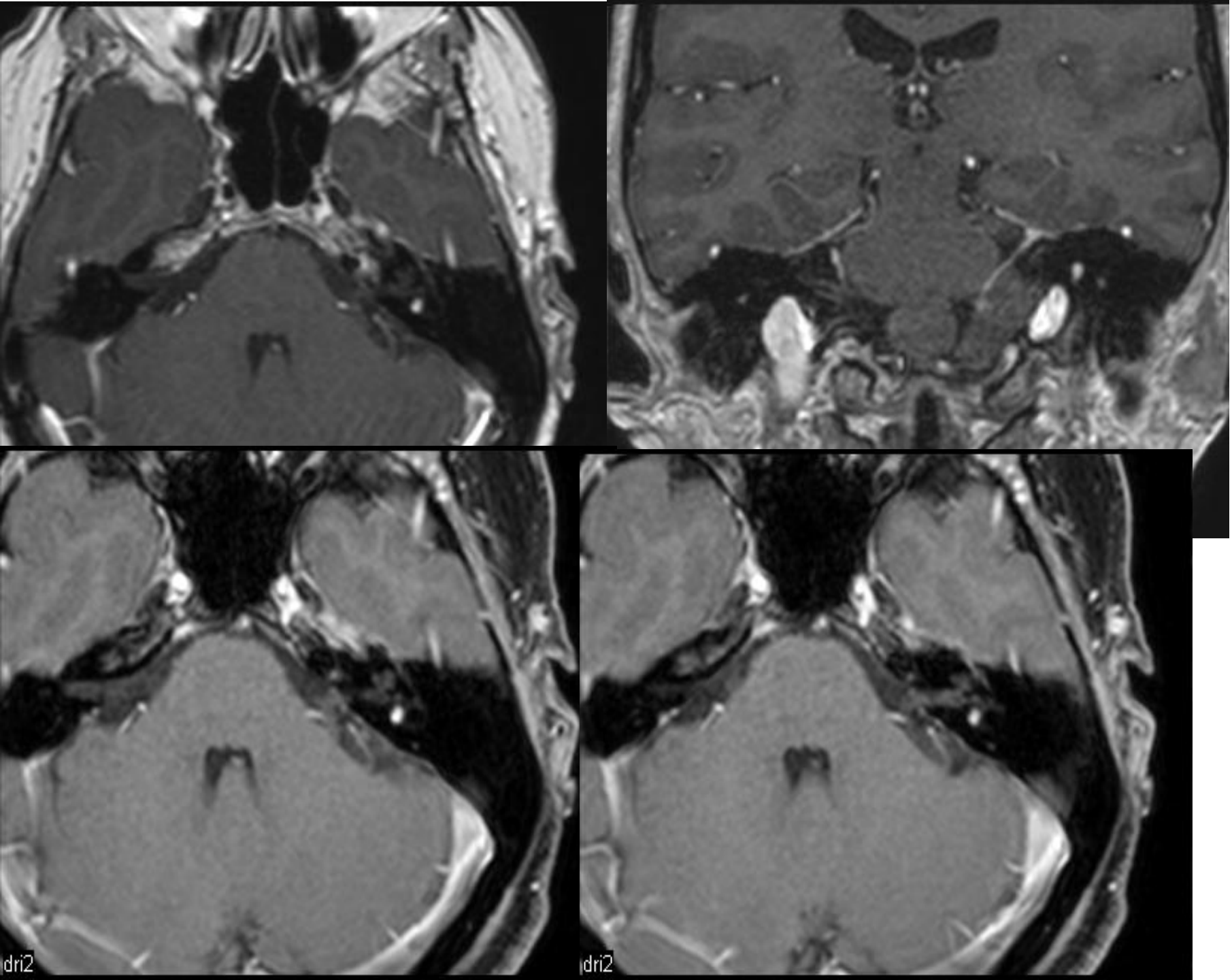
dri2
dri2

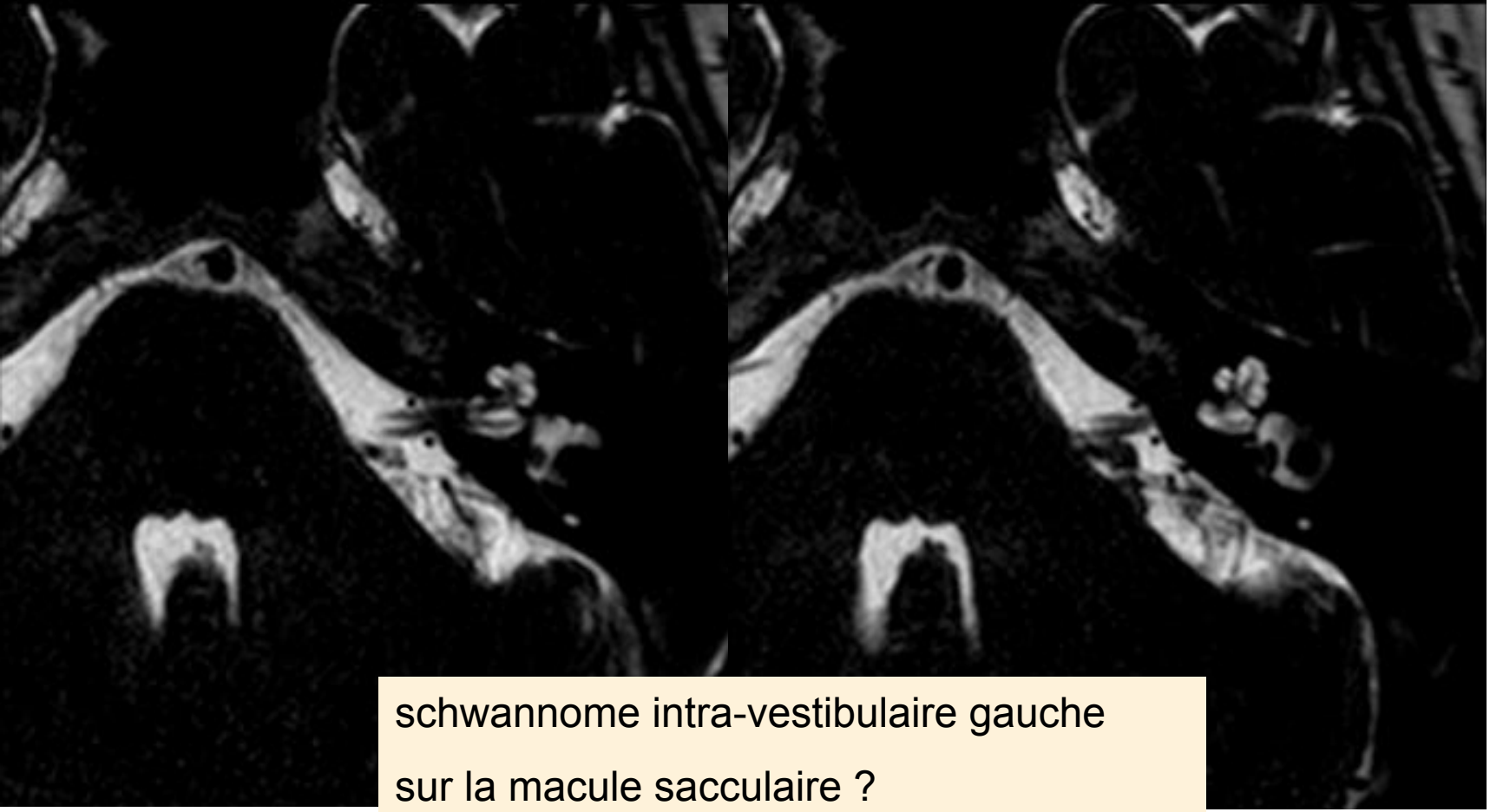

schwannome intra-vestibulaire gauche

sur la macule sacculaire ?

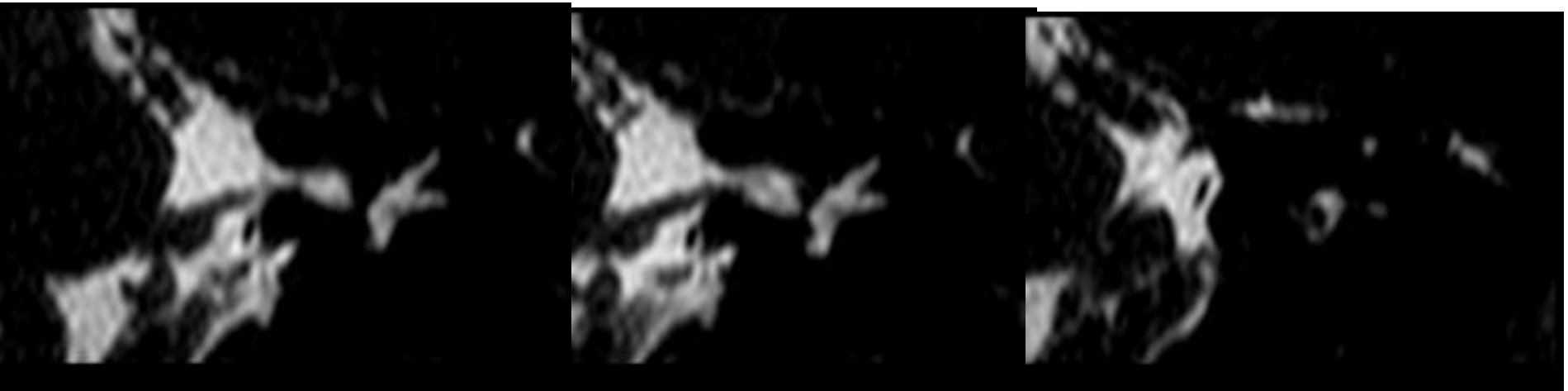

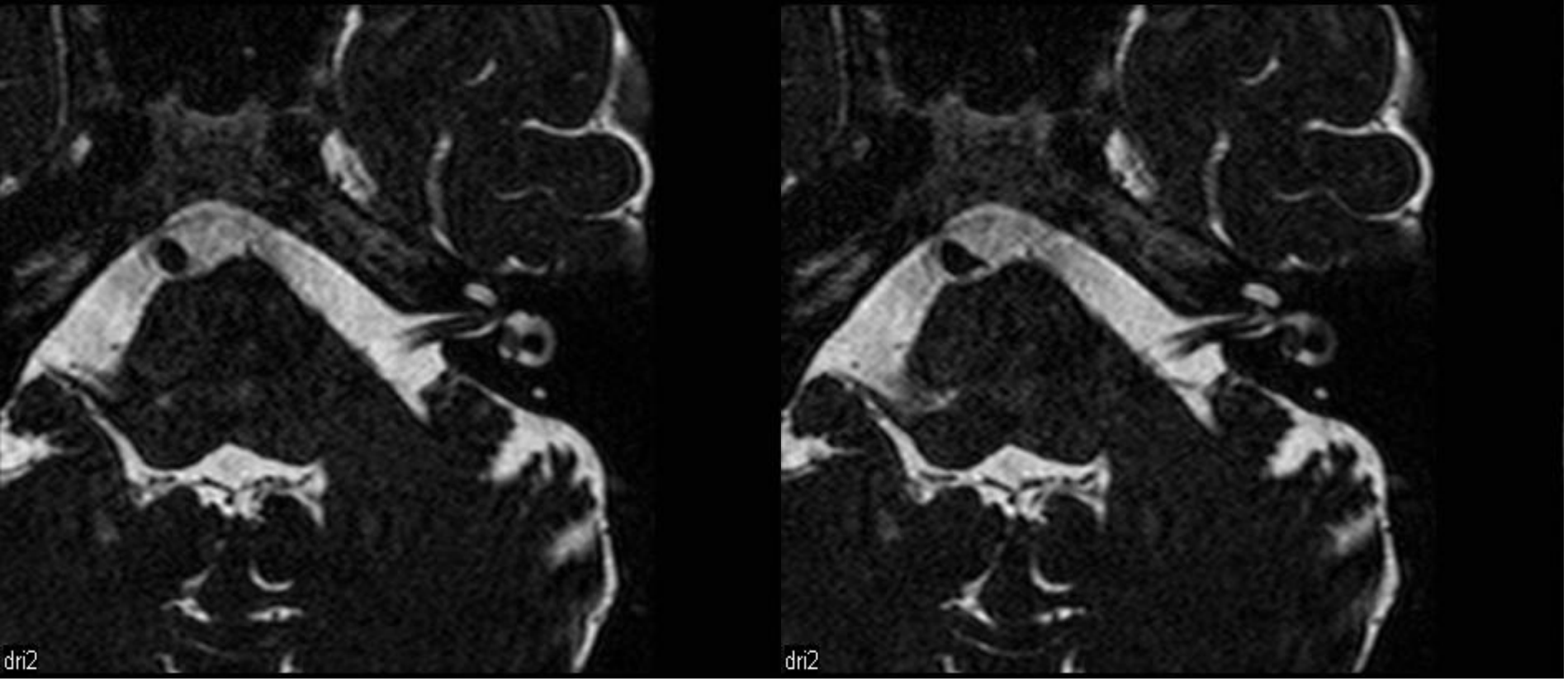
dri2
dri2

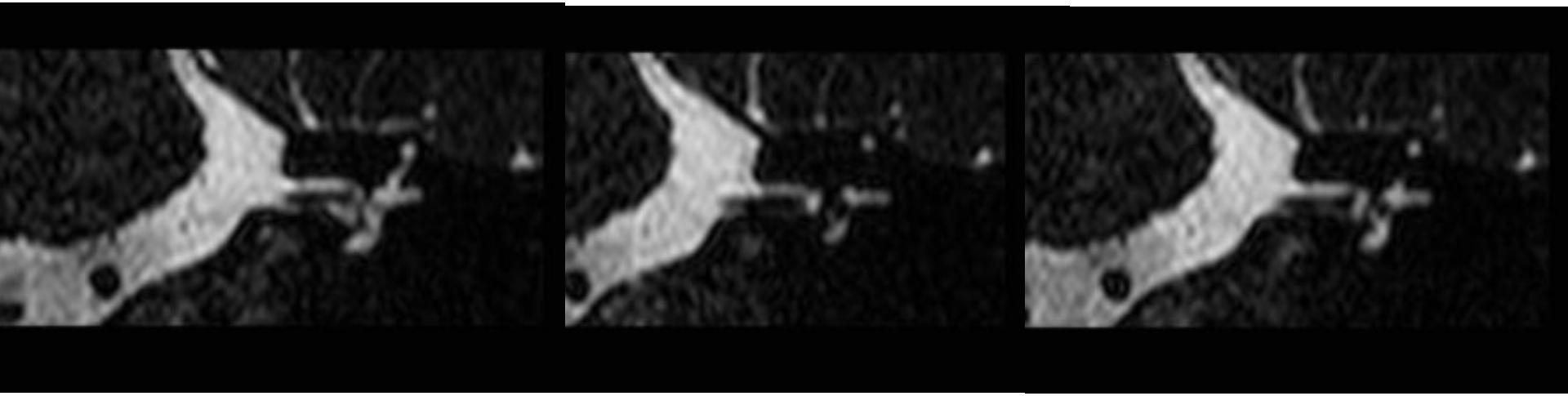

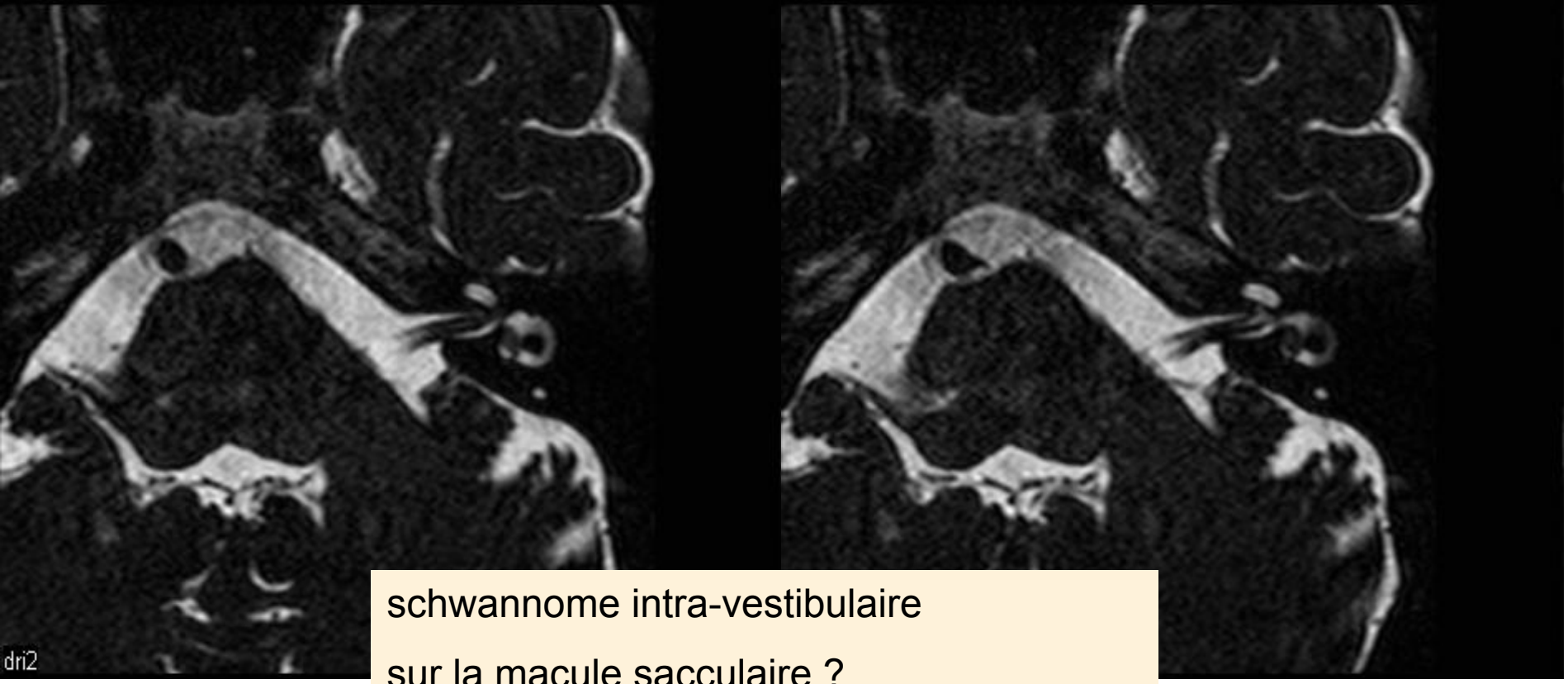

schwannome intra-vestibulaire

sur la macule sacculaire ?

Conclusion

Intérêt du FLAIR 4 h après gado +++
>> séquence 3D HR T2

Toujours après une IRM classique (séquences classiques oreille – CAI)